

# The Diagnostic Challenge Posed By Cardiac Myxomas: A Quintessential Case

Abdullah Al-Hudaib\*, Saad Warraich

MB BCh BAO LRCSI & LRCPI

## Abstract

*Cardiac myxoma is the commonest of a rare group of entities known as benign growths of the heart.*

*This case report aims to highlight the challenges associated with diagnosing a patient with this tumour.*

*The discovery in our patient was unexpectedly made when an echocardiography study was conducted to investigate persistent dyspnea. After its detection, the tumour was consequently surgically resected.*

*Most cases, like this one, are incidental findings. Patients usually present with episodic dyspnea, hemoptysis, syncope, signs of right heart failure, ascites, or hepatic congestion. Due to the unique characteristics of the tumour, echocardiography remains the ideal method for investigation. The diagnosis, however, is confirmed only by biopsy.*

## **Introduction**

Primary cardiac tumours have been known since the middle Ages, yet they continue to form a challenge in terms of their diagnosis and management [1]. The first successful resection was performed by Clarence Crawford, a Swedish cardiovascular surgeon, in 1954 with the assistance of a heart-lung machine [2]. Recent autopsy studies have revealed that the prevalence of cardiac tumours is 0.02% [1].

Majority (75%) of the tumours of the heart are benign, with the rest being malignant [1]. 50% of primary benign neoplasms are myxomas. Other types of benign neoplasms include lipoma, fibroblastoma of valves, rhabdomyoma, and mesothelioma of the AV node among others. Primary malignant cardiac neoplasms are mostly sarcomas such as angiosarcoma, rhabdomyosarcoma, fibrosarcoma and mesothelioma [3].

Myxoma arises from either pluripotent subendocardial mesenchymal cells or endocardial nerve cells [3]. Around 5% of myxomas show autosomal dominant inheritance, and the peak incidence occurs mostly in the 3rd to 6th decade with 2-3:1 female to male preponderance [3].

The average size is about 5cm, and they can have areas of hemorrhage, cyst formation, or necrosis [3].

The tumours are likely to grow into the overlying cardiac cavity, rather than the surrounding myocardium. They have the potential to grow in different cardiac chambers, with a higher incidence (75%) of being located in the left atrium and a lower incidence (20%) of being located in the right

atrium, leaving only a small minority to be of ventricular origin [3]. Multicentric tumours are less than 5% of all myxoma cases [7]. The tumour can also originate from two different chambers of the heart [7].

Clinical presentation of myxomas vary according to the tumour location, size, and mobility [4].

Frequently, the patient is asymptomatic and the tumour is discovered incidentally [3]. Embolism, intracardiac obstruction, constitutional symptoms, as well as, infection can be the presentation of a myxoma [3]. Transesophageal echocardiography is diagnostic and the method of choice for diagnosing myxomas [3]. Myxomas share a feature with malignant tumours, in that they have the potential to metastasize; it can metastasize to different sites, but favors the cerebrum [4]. The exact incidence of metastases is unknown, but it's estimated to be over 10% of all cardiac myxoma cases [1]. Traditionally, the discovery of atrial myxoma is considered an indication for urgent surgery within 24 hours of diagnosis due to risk of embolism and intracardiac obstruction [3]. Atriotomy with excision of the tumour is considered curative [3].

## **Case Report**

67 years old female, a known case of diabetes mellitus type II, hypertension, supra ventricular tachycardia (SVT), iron deficiency anaemia, irritable bowel syndrome, sciatica and biliary atresia, was regularly attending a neurology clinic for management of her sciatica. On the 15th of October 2013, the patient came complaining to this clinic of shortness of breath, exaggerated by physical activity, and generalized

weakness for the past few weeks. The treating doctor misdiagnosed her with asthma and prescribed a long acting bronchodilator. The patient reported that the inhaler did not relieve the symptoms, and that the shortness of breath had persisted.

On the 12th of November 2013, she visited an internal medicine specialist at a private clinic complaining of weakness, weight loss, and shortness of breath. There she was diagnosed with iron deficiency anaemia-her hemoglobin level was found to be 8 g/L-and vitamin D deficiency. She was advised to improvement in symptoms a few weeks after taking the supplements. Unfortunately, by the end of January 2014 or so, the symptoms worsened, especially the shortness of breath. Later on, she presented to the accident and emergency department of a local hospital with a history of fever, shortness of breath, dysuria of one-week duration, anaemia, and anorexia with severe weight loss.

Echocardiography was done on the 17th of April, which showed a large mass inside the left atrium that prolapsed into the left ventricle during diastole. The mass was attached to the interatrial septum, and measured about 2.6x3.4cm. These findings were suggestive of an atrial myxoma. The patient was transferred to a tertiary centre on the 18th of April. A left atrial myxoma excision was performed successfully with no complications. The patient recovered fully postoperatively, her symptoms subsided, and she was discharged two weeks after surgery.

## Discussion

The chief complaint of the patient was dyspnea. Left atrial myxoma is considered a rare cause of dyspnea, while dyspnea is a common symptom of cardiac myxoma [6, 4]. Ali Pourdjabbbar et al. claim that “myxoma is a rare cause of dyspnea and a diagnosis that is often not considered in the absence of embolic complications” [6]. Since the patient only had dyspnea, without embolic complications, a high index of suspicion was required to list myxoma in the differential diagnosis.

Constitutional symptoms and clinical features of cardiac myxoma vary between different patients. They can present

with fatigue, fever, rash, arthralgia, myalgia, weight loss, in addition to symptoms of anaemia. Studies have confirmed that myxomas produce interleukin 6 (IL-6)—an inducer of the acute phase response that results in constitutional symptoms and immunologic abnormalities [5]. This could possibly explain the patient’s weakness, weight loss, shortness of breath, and iron deficiency anaemia.

Whenever a cardiac tumour is suspected, diagnostic investigations should start with exclusion of vegetations or thrombi [1]. History taking and physical examination, followed by a Focused Cardiac Ultrasound (FOCUS) are significantly beneficial in clinical practice for diagnosing such tumours [6].

Generally, there are two main approaches for ultrasound cardiac imaging, namely Transthoracic Echocardiography (TTE) and Transesophageal Echocardiography (TEE) [3]. There are many advantages of TEE over TTE; TEE has a finer resolution, and is better at imaging the posterior aspect of the heart advanced imaging techniques can be used such as computed tomography and magnetic resonance imaging [1]. If malignancy is suspected, such as a lymphoma, a biopsy sample will confirm the diagnosis; coronary angiography can also prove helpful in that it can elucidate the vascular nature of the tumour [1].

The patient’s intra-operative TEE clearly shows the tumour prolapsing into the left ventricle during diastole, thereby obstructing the inflow of the ventricle [Figure 1] [Figure 2].

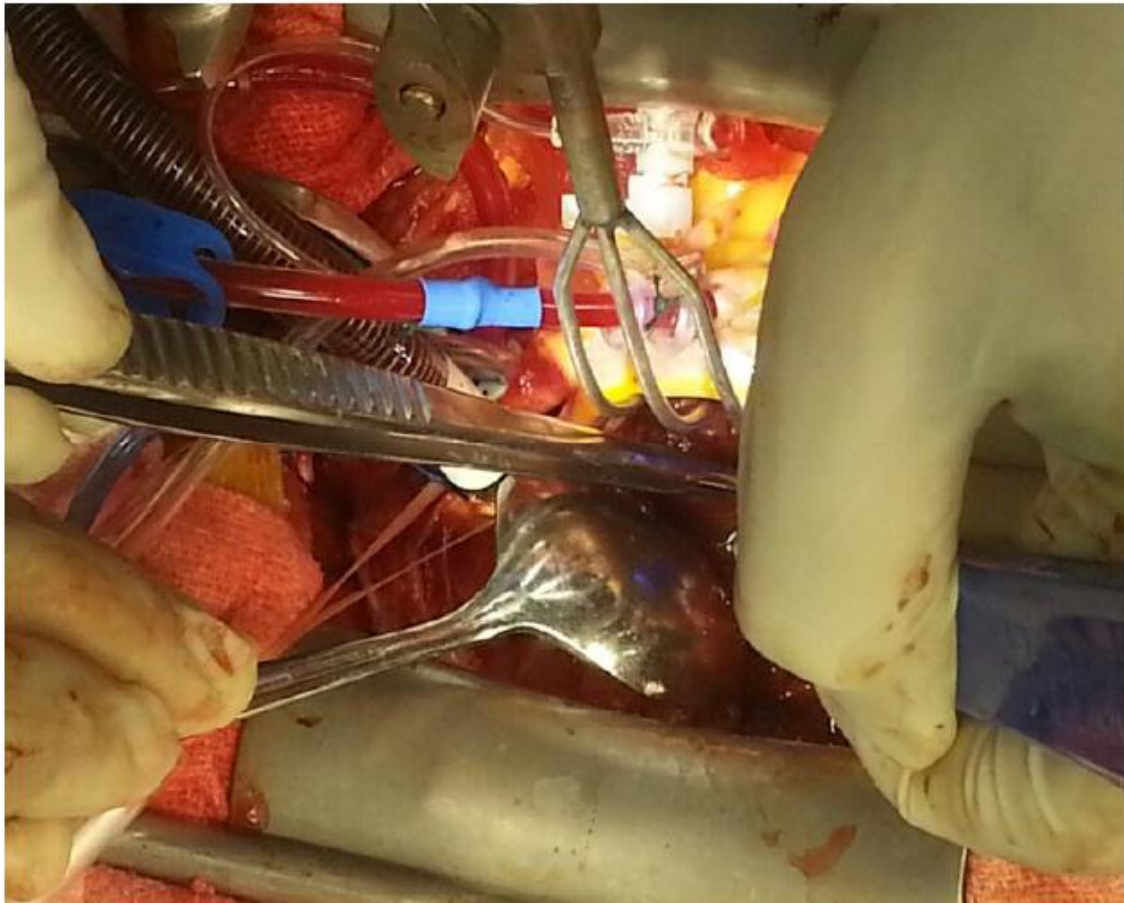
Management of left atrial myxoma requires the input of a multidisciplinary team, and surgery is the main treatment modality. Simple tumour resection is usually performed for this benign tumour via an oblique right atriotomy; incision of the floor of the right atrium in a trans-septal approach is then made and a sterile dessert spoon is subsequently used to evacuate the friable, gelatinous tumour without causing it to fragment [1,3]. Figure 3 illustrates the use of the dessert spoon on our patient. In some cases, myxomas might damage valves by a ‘wrecking ball’ effect that requires valve reconstruction or replacement [3].

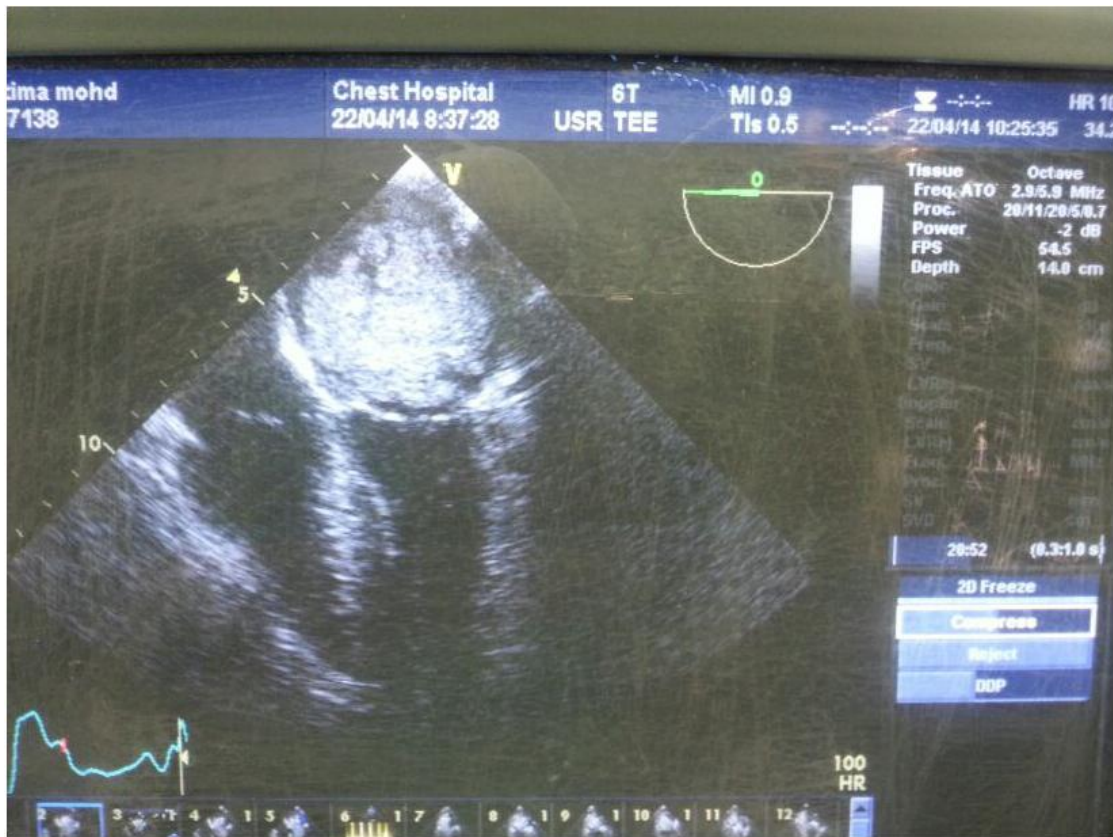

Figure 1: Tumour during systole.

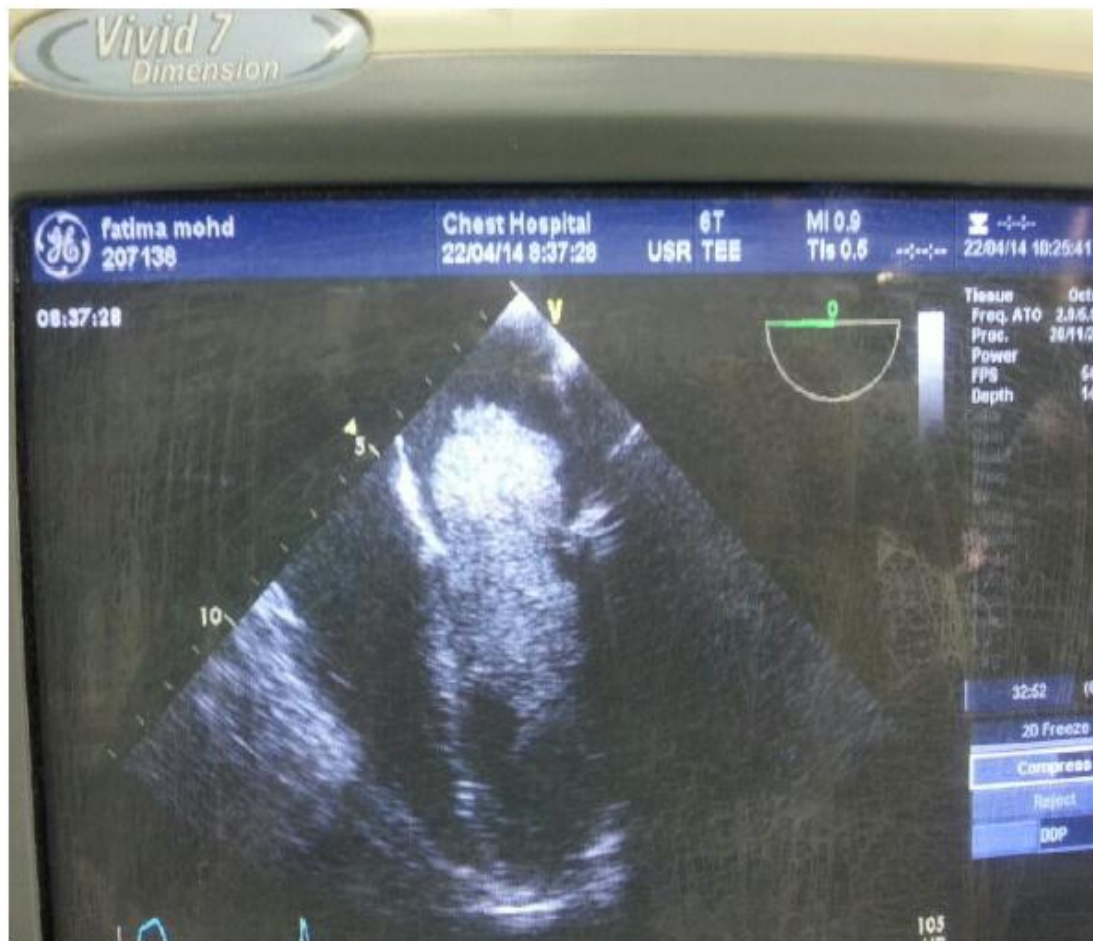

Figure 2: The tumour prolapsing into the LV from the LA during diastole, and thus obstructing the filling of the ventricle.



**Figure 3: The cardiac surgeon is using what is called a sterile dessert spoon to evacuate the tumour.**

## References

- [1] Hoffmeier, A; Sindermann, J R; Scheld, H H; Martens, S. Cardiac Tumors—Diagnosis and Surgical Treatment. *Dtsch Arztebl Int.* Mar 2014; 111(12): 205–211.
- [2] Chitwood WR Jr. Clarence Crafoord and the first successful resection of a cardiac myxoma. *Ann Thorac Surg.* 1992 Nov; 54(5):997-8.
- [3] Chikwe Joanna, Cooke David Tom, Weiss Aaron. *Cardiothoracic Surgery. Second Edition.*Oxford Medical Publications: 2012.
- [4] Ji-Gang Wang, Yu-Jun Li, Hui Liu, Ning-Ning Li, Jie Zhao, and Xiao-Ming Xing. Clinicopathologic analysis of cardiac myxomas: Seven years' experience with 61 patients. *J Thorac Dis.* Jun 1, 2012; 4(3): 272–283.
- [5] Jun Amano, MD, PhD, Tetsuya Kono, MD, PhD, Yuko Wada, MD, Tianshu Zhang, MD, PhD, Naohiko Koide, MD, PhD, Minoru Fujimori, MD, PhD, and Ken-ichi Ito, MD, PhD. Cardiac Myxoma: Its Origin and Tumor Characteristics. *Ann Thorac Cardiovasc Surg* Vol. 9, No. 4 (2003).
- [6] Ali Pourdjabbar, MD, Benjamin Hibbert, MD, Ronnen Maze, MD, Chi Lai, MD, Michel R. Le May, MD. Left Atrial Myxoma: A Rare Cause of  
Dyspnea. *Canadian Journal of Cardiology* Volume 30, Issue 4, April 2014, Pages 465.e1–465.e2.
- [7] M YILMAZ, O GURBUZ, M CENGIZ. Multicentric Cardiac Myxoma Treated with Extended Surgery. *Journal of International Medical Research* 2006 34: 331.
- [8] Z. Akbarzadeh, M. Esmailzadeh, A. Yousefi, A. Safaei, K. Raisi, F. Sharifi. Multicentric familial cardiac myxoma. *Oxford Journals Medicine EHJ Cardiovascular Imaging* Volume 6, Issue 2 P. 148-150.