



# Evaluation of Plasma-Assisted Noninvasive Surgery (PANIS) As a New Approach for Pterygium Removal with Amniotic Membrane Transplantation (AMT); a Clinical Case Series

Farhad Nejat <sup>\*1</sup>, Khosrow Jadidi <sup>1</sup>, Shima Eghtedari <sup>1</sup>, Nazanin Sadat Nabavi <sup>1</sup>, Maryam Moradi <sup>2</sup>

<sup>1</sup>Vision Health Research Center, Tehran, Iran

<sup>2</sup>Iran University of Medical Sciences, School of Medicine, Tehran, Iran

\*Co-responding Author: Farhad Nejat; Address: Unit 17, 5th Floor, No. 8, 2nd alley, in front of Dey Hospital, above Tavanir Intersection, Valiasr St., Tehran, Iran; [fanejat@yahoo.com](mailto:fanejat@yahoo.com)

Received 21 October 2021;

Accepted 08 November 2021;

Published 14 November 2021

## Abstract

**Purpose:** Medical plasma application has been used in different fields recently. In this study, we assess the outcome of using plasma-assisted noninvasive surgery (PANIS) with amniotic membrane transplantation (AMT) in pterygium surgical treatment. **Methods:** This clinical case series was conducted in 4 patients with primary grades 1, 2, and 3 pterygium (Table 1). After exclusion and inclusion criteria considerations, patients underwent different examinations. Various measurements were obtained such as uncorrected visual acuity (UCVA), refractive error (RE), the best-corrected visual acuity (BCVA), and ocular surface disease index (OSDI). The surgical procedure was pterygium removal from the cornea and then AMT attached to the conjunctival borders with plasma spots using a white handpiece of Plexr device (Plexr, GMV s.r.l Grottaferrata, Italy) instead (Table 2). After postoperative follow-ups within the first week of the surgery and in 1 month and 6 months later the results were obtained. **Results:** All patients have been fully recovered after the surgery without any complications. In all 4 cases, UCVA, BCVA, and RE parameters have improved during 6 months after the surgical procedure. Every patients' OSDI decreased after the surgery. Recurrence has not been seen in any cases during 6 months follow-up. **Conclusion:** Pterygium removal surgery using the PANIS technique with AMT is safe, effective, fast, and cost-benefit.

**Keywords:** Pterygium, Amniotic membrane transplantation, Plasma assisted noninvasive surgery.

## Introduction

Pterygium is a common superficial ocular disorder that mostly forms over the perilimbal conjunctiva and continues onto the corneal surface. Its prevalence differs from 1% to more than 30% with various geographical locations. China has the highest prevalence of pterygium about 53% and Saudi Arabia has the lowest about 0.07%. There are different risk factors responsible for pterygium; male gender, older age, living in rural areas, having outdoor jobs, and sun exposure. Most patients' complaints are swelling, redness, itching, irritation, and blurring of vision. Corneal astigmatism and Ocular surface squamous neoplasia are possible complications in some serious cases [1-4].

Surgical treatment is essential due to the lesion expansion toward the optical area and altered visual acuity. Different surgical

methods have been used with various recurrence rates; bare sclera, conjunctival or conjunctiva-limbal autografting, and using amniotic membrane transplantation (AMT) for the surgical site after pterygium excision. In contrast to conjunctival autografting, AMT utilization with sutured or glued over the bare scleral site helps to reduce postoperative pain and normal limbal stem cells proliferation, although, the recurrence rate is higher in this method according to a meta-analysis in 2016. In some cases, adjuvant therapies such as fluorouracil (FU), mitomycin C (MMC), beta-irradiation, or vascular endothelial growth factor (VEGF) were used to reduce recurrence rate [1,5-7]. Post-operative recurrence is the utmost concern following pterygium surgical management. Pterygium length, width, relative area, and also the scale of vascularity have been described to be the most relative risk factors responsible for post-operative recurrence, while sex and age had no significant influences [8-10].

Recently, the medical application of plasma has emerged and plasma medicine has been known as an appealing research topic lately. Plasma is defined as the fourth state of matter which is the most placeable known matter in the whole universe [11]. Low-temperature plasma (LTP) reactivates oxygen and nitrogen forms and is used as a direct treatment of living cells and tissues. The cancer field, dermatology, dentistry, wound healing and ophthalmology are various areas in which LTP has entered [12-14]. In ocular surface disorders, plasma-assisted noninvasive surgery (PANIS) has been used for Conjunctival cyst and conjunctivochalasis treatment so far. According to the results of these studies, the PANIS method is effective, safe, rapid, and affordable with a short recovery time [16,17].

In the current study, we use the PANIS method with amniotic membrane transplantation (AMT) for pterygium excision in four patients.

**Materials and Methods**

Between August 2019 and October 2021, pterygium removal surgery with AMT, PANIS method was performed at Vision Health Research Center in Tehran, Iran on 4 eyes (2 left and 2 right eyes) of 4 patients (three males and one female) who had primary grade 1, 2 and 3 pterygium (Table 1). The patient’s mean age was 44.5 years old. Permission from the Semnan University Ethics Committee for Clinical Studies and written informed consent from all patients were obtained before the study [IRCT20181229042160N2] and we adhere to the Declaration of Helsinki in our study. None of the patients had any underlying systemic diseases and those with recurrent pterygium were excluded. Later, different measurements were conducted such as refractive error (RE), uncorrected visual acuity (UCVA), the best-corrected visual acuity (BCVA), and ocular surface disease index (OSDI). All the parameters were performed as a follow-up examination in one week, one month, and six months after the surgery.

The OSDI is a fast assessment in patients with dry eye for ocular irritations which was measured by a 12-item questionnaire, with a 0 to 100 range of scores. The higher the final score, the worse the prognosis.

**Table1: Pterygium Grading**

Pterygium Grading	Extension
Grade 1	Between limbus and a point midway between the limbus and pupillary margin.
Grade 2	Head of the pterygium present between a point midway between the limbus and pupillary margin and pupillary margin.
Grade 3	Crossing pupillary margin.

**Surgical procedure**

Local anesthesia was performed using three drops of 0.5% tetracaine (Sina Darou, Tehran, Iran) every 5 minutes. The pterygium border was marked about 2 mm behind the limbus in the

operating room. At the first, the scalpel blade was entered into the conjunctiva), the pterygium was excised near the limbus and the head of the pterygium was separated from the corneal surface. Then the remaining attachments were shaved and removed with a knife and the corneal surface polished. Next, the involved Tenon tissue was cautiously dissected off the normal conjunctiva. After that, the bare sclera was coated with AMT and its borders were fused to the edge of the Conjunctiva with plasma spots (See the video). For this purpose, the white handpiece (VPP= 500 V, Power = 0.7 W, and Frequency = 75 kHz) (Table 2) of the Plexr device was used. After the surgery, a combination of antibiotic and corticosteroid eye ointment was applied to the patient's eye and the eye was closed gently with the eye pad for 24 hours. All the procedures were done by Dr. Farhad Nejat.

Patients were discharged with 0.3% ciprofloxacin eye drop (Sina Darou, Tehran, Iran) and 0.1% betamethasone eye drop (Sina Darou, Tehran, Iran) every 4 hours for 1 week. The corticosteroid drop was tapered within 4 weeks.

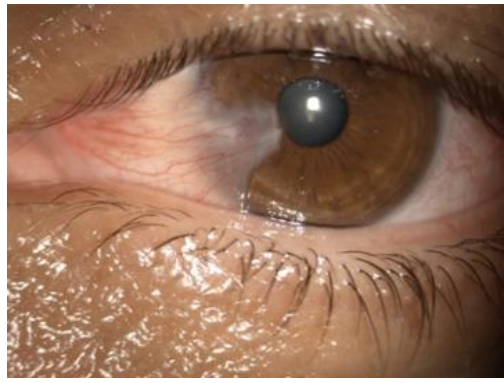
**Table 2: Technical features of Plexr device**

Parameters	Values
Working gas	Air
Power supply	Docking station = 24V Handpieces: embedded inductive charger = 5V
<b>Handpieces:</b>	
Max output	≤ 2W
Max working voltage	≤ 1,3 kVPP
Output frequency	(70-80) kHz
<b>Handpiece types:</b>	
White	V peak to peak = 500V, Power = 0.7W, Frequency = 75kHz
Green	V peak to peak = 600V, Power = 2W, Frequency = 75kHz
Red	V peak to peak = 700V, Power = 2W, Frequency = 75kHz
Maximum absorbed power (Docking station)	120W
Applicator electrode	Stainless steel sterile disposable needle
Risk classification of the device	I Ib (Medium-high risk)

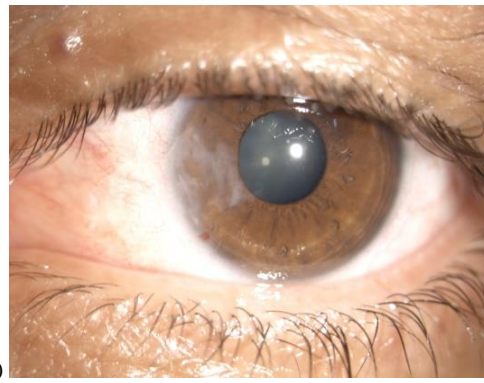
Abbreviations: V= Volt, W= Watt, k=kilo, VPP= Peak-to-peak voltage, Hz= hertz.

**Results**

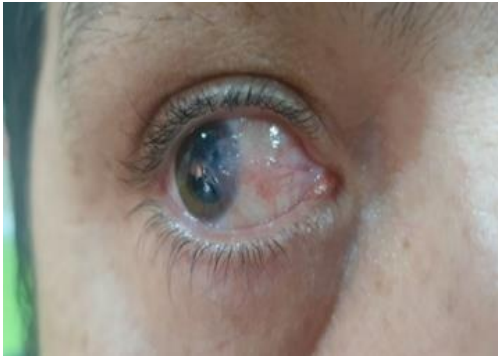The patient’s demographic data are summarized in Table 3. Post-operative complaints such as mild pain, mild tear, mild foreign body sensation, and mild irritation were observed during the first week after the procedure. Besides the usual complaints, all patients were fully recovered within months without any noticeable complications. The pre and post-operative slit-lamp images are shown in Figure 1.



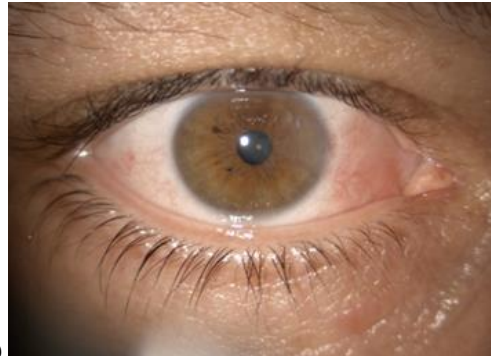
Case 1 (A)



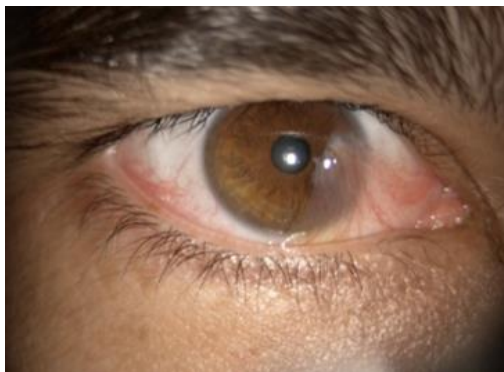Case 1 (B)



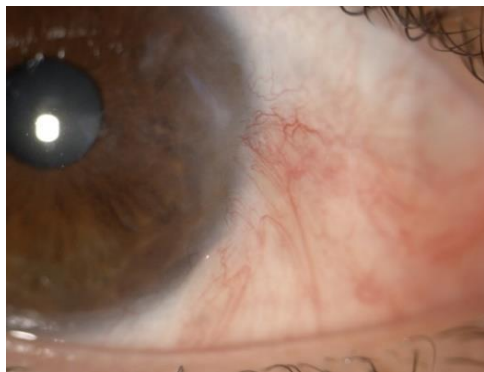
Case 2 (C)



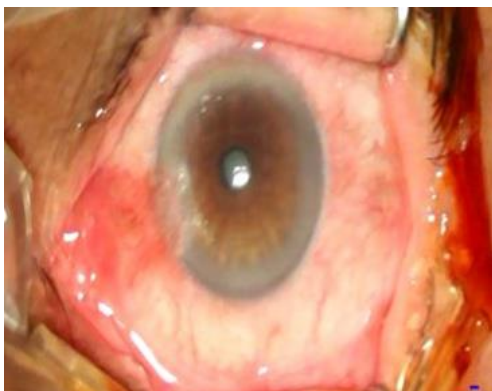Case 2 (D)



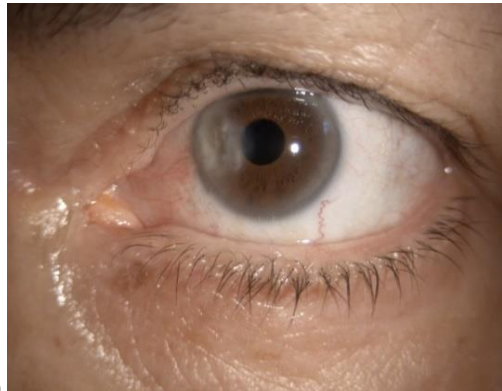
Case 3 (E)



Case 3 (F)



Case 4 (G)



Case 4 (H)

**Figure 1: Patients pre and post-operative slit-lamp images**

**(A): Case 1 pre-surgery (Grade 3), (B): Case 1 post-surgery, (C): Case 2 pre-surgery (Grade 3), (D): Case 2 post-surgery, (E): Case 3 pre-surgery (Grade 2), (F): Case 3 post-surgery, (G): Case 4 pre-surgery (Grade 1), (H): Case 4 post-surgery**

Both visual acuity measures (UCVA and BCVA) have improved after the surgery and also in the next follow-ups visits. The mean UCVA before surgery was 0.35, while it was 0.675 within the first week of the surgery and 0.775 in 6 months follow-up. The mean BCVA before surgery was 0.55, while it was 0.85 within the first week of the surgery and 0.9 in 6 months follow-up (**Table 4**). As expected, RE was decreased after the procedure (**Table 4**).

According to the 12-item questionnaire for the ocular irritation scale, it has shown that the surgery was a success and OSDI has decreased dramatically. The mean OSDI before surgery was 65.55 but after surgery, it was 29.175 and 15.8 within the first week from the surgery and in 6 months follow-up (**Table 4**). In the current study, after 6 months of follow-up, no recurrence has been seen.

**Table 3: Patients Data**

Case No.	Gender	Age	Affected Eye	Pterygium Grade
1	Male	39	Left	3
2	Male	43	Right	3
3	Male	38	Right	2
4	Female	58	Left	1

**Table 4: Patients ocular Parameters before and after the surgery**

Case I	UCVA	RE (Sphere)	RE (Cylinder)	RE (Axis)	BCVA	OSDI
Pre	0.7	-1	-2.25	170	0.7	44.7
One week	0.8	-0.25	-0.75	160	1	34
One month	0.8	-0.25	-0.5	160	1	28
Six months	0.8	-0.25	-0.5	160	1	22
<b>Case 2</b>						
Pre	0.1	-4	-3.75	180	0.3	67.5
One week	0.7	-1	-1	180	1	16
One month	0.8	-0.5	-0.75	175	1	12.5
Six month	0.8	-0.5	-0.75	175	1	12
<b>Case 3</b>						
Pre	0.4	-1.75	-2.75	165	0.8	66
One week	0.8	-0.25	-1.25	180	0.9	23
One month	0.8	-0.25	-0.75	180	0.9	12
Six months	0.9	-0.25	-0.75	180	0.9	11.5
<b>Case 4</b>						
Pre	0.2	-3	-3	180	0.4	84
One week	0.4	-2	-1.5	140	0.5	43.7
One month	0.4	-2	-1.25	140	0.6	22
Six months	0.6	-1	-1.5	160	0.7	17.7

Abbreviations: UCVA= Uncorrected Visual Acuity, RE= Refractive Error, BCVA= Best Corrected Visual Acuity, OSDI= Ocular Surface Disease Index

**Discussion**

Pterygium is an ancient ocular disorder worldwide with a wide range of prevalence. Different surgical methods have been used to excise the damaged area. The major concern in all available surgical methods is the high rate of recurrence [18,19]. Treatment options like primary or bare scleral closure, conjunctival or limbal-conjunctival sliding flap transplantation, AMT, intraoperative mitomycin C, and postoperative mitomycin C are the available methods with different recurrence rates. Among these methods, the highest recurrence rate has been seen in bare scleral closure. Conjunctival or limbal-conjunctival autograft transplantation (CAT) was preferred to the AMT method due to the less recurrence rate [20-22].

In Cem Küçükerdönmez et al. study recurrence rate was compared between CAT and AMT methods. After pterygium dissection with a surgical blade and excision for 4mm from the limbus with a scissor, the fibrovascular tissue was removed from the conjunctival edge for 2mm. Later, a 100 mL balanced salt solution was used to wash the eye surface, and then the patient received either CAT or AMT with sutures. In this study, after further evaluation, there were no significant differences in recurrence rate between the two groups (7.5% vs 7.9%). However, cosmetic appearance was significantly better in those who underwent CAT surgery [23].

Based on a meta-analysis in 2016 on 20 studies with both primary and recurrent pterygium, CAT recurrence after 6 months was from 0% to 16.7% while it was from 4.76% to 26.9% in AMT (with glued or sutured) method. However, the recurrence rate after 3 months in both groups did not have a significant difference. In this analysis, there was no significant difference between the

recurrence rates when the studies were performed in primary pterygium [7].

In Cem Küçükerdönmez and his colleague’s study, 70 eyes underwent pterygium excision followed by AMT. Thirty-two eyes were in the fibrin glue group and 38 were in vicryl sutures. Post-operative complaints were fewer in the fibrin glue group than vicryl sutures. Corneal recurrence was seen in 9.4% of the first group and 10.5% of the second group. Conjunctival recurrence was seen in 21.9% of the first and 23.7% of the second group. In pterygium removal surgery, using AMT is an alternative method to the limbal autograft, but due to the recurrences in both glued and sutured groups, neither of them represent the best results [24].

In the study of Sailaja Bondalapati and Balamurali Ambati on sutureless pterygium excision, 9 eyes underwent minimally invasive surgery with AMT and ReSure as a tissue hydrogel sealant. After 41 weeks of follow-up, there was no complication or recurrence reported [25].

In our previous study of pterygium removal surgery with the PANIS method on 6 patients, we used plasma spots to attach the free edges of conjunctiva after pterygium removal. In previous study glue or suture string were not used but recurrence was seen in 2 cases. Our current study indicates that pterygium removal surgery with AMT and PANIS method can decrease the rate of postoperative recurrence as we did not see any recurrence in the six months of follow-up, and also due to the absence of suture strings and glues, surgical finances can be lowered. However, due to the small number of patients participating in this surgical procedure for ethical reasons, it is recommended to conduct studies in this field with a higher number of samples and also a longer follow-up time to achieve more definitive results.

## Conclusion

According to the current study, the PANIS method with AMT can be a promising technique for pterygium removal surgery. This method is fast, effective, safe, and consumes fewer finances.

## Ethical approval

This project was approved by the Institutional Review Board of Semnan University of Medical Sciences [IRCT20181229042160N2].

## Funding

None

## Competing interests

The authors declare that they have no competing interests.

## Consent for publication

The author confirm that written consent has been obtained from the patient for submission and publication.

## Availability of data and materials

Not applicable.

## Authors' contributions

Not applicable.

## Acknowledgments

None

## References

- [1] Shahraki T, Arabi A, Feizi S. Pterygium: an update on pathophysiology, clinical features, and management. *Ther Adv Ophthalmol.* 2021;13:25158414211020152.
- [2] Sarkar P, Tripathy K. Pterygium. *StatPearls. Treasure Island (FL): StatPearls Publishing Copyright © 2021, StatPearls Publishing LLC.; 2021.*
- [3] Rezvan F, Khabazkhoob M, Hooshmand E, Yekta A, Saatchi M, Hashemi H. Prevalence and risk factors of pterygium: a systematic review and meta-analysis. *Surv Ophthalmol.* 2018;63(5):719-35.
- [4] Pan ZX, Shan GL, Wang XJ, Pan L, Tao ZY, He HJ, et al. [Prevalence and risk factors of pterygium in Han and Yugur populations in Gansu Province, China]. *Zhonghua Yan Ke Za Zhi.* 2020;56(8):600-7.
- [5] Malozhen SA, Trufanov SV, Krakhmaleva DA. [Pterygium: etiology, pathogenesis, treatment]. *Vestn Oftalmol.* 2017;133(5):76-83.
- [6] Chu WK, Choi HL, Bhat AK, Jhanji V. Pterygium: new insights. *Eye (Lond).* 2020;34(6):1047-50.
- [7] Clearfield E, Muthappan V, Wang X, Kuo IC. Conjunctival autograft for pterygium. *Cochrane Database Syst Rev.* 2016;2:Cd011349.
- [8] Han SB, Jeon HS, Kim M, Lee SJ, Yang HK, Hwang JM, et al. Risk Factors for Recurrence After Pterygium Surgery: An Image Analysis Study. *Cornea.* 2016;35(8):1097-103.
- [9] Razmjoo H, Kashfi SA, Mirmohammadkhani M, Pourazizi M. Recurrence Rate and Clinical Outcome of Amniotic Membrane Transplantation Combined with Mitomycin C in Pterygium Surgery: Two-Year Follow-Up. *J Res Pharm Pract.* 2020;9(1):10-5.
- [10] Costa FQ, Costa RQ, Barbosa JB, Gomes JÁ P. Pterygium Surgery with Conjunctival Autograft Fixation Using Bipolar Electrocauterization. *Eur J Ophthalmol.* 2021;31(3):1458-62.
- [11] Yan X, Ouyang J, Zhang C, Shi Z, Wang B, Ostrikov KK. Plasma medicine for neuroscience-an introduction. *Chin Neurosurg J.* 2019;5:25.
- [12] Laroussi M. Plasma Medicine: A Brief Introduction. *Plasma.* 2018;1(1).
- [13] T VONW, Schmidt A, Bekeschus S, Wende K, Weltmann KD. Plasma Medicine: A Field of Applied Redox Biology. *In Vivo.* 2019;33(4):1011-26.
- [14] Bernhardt T, Semmler ML, Schäfer M, Bekeschus S, Emmert S, Boeckmann L. Plasma Medicine: Applications of Cold Atmospheric Pressure Plasma in Dermatology. *Oxid Med Cell Longev.* 2019;2019:3873928.
- [15] Nejat F, Nabavi N-S, Nejat M-A, Aghamollaei H, Jadidi K. Safety evaluation of the plasma on ocular surface tissue: An animal study and histopathological findings. *Clinical Plasma Medicine.* 2019;14:100084.
- [16] Nejat F, Jadidi K, Pirhadi S, Adnani SY, Nabavi NS, Nejat MA. A Novel Approach to Treatment of Conjunctival Cyst Ablation Using Atmospheric Low-Temperature Plasma. *Clin Ophthalmol.* 2020;14:2525-32.
- [17] Jadidi K, Nabavi N-S, Nejat MA, Aghamollaei H, Adnani S-Y, Nejat B, et al. Evaluation of plasma assisted noninvasive surgery (PANIS) as a new approach for the treatment of conjunctivochalasis; a clinical case series. *Expert Review of Ophthalmology.* 2021;16(3):225-30.
- [18] Young AL, Kam KW. Pterygium: Surgical Techniques and Choices. *Asia Pac J Ophthalmol (Phila).* 2019;8(6):422-3.
- [19] Lin YH, Sun CC, Yeung L, Yu YW, Sun MH, Chen KJ. Epidemiologic study of pterygium in Taiwan. *Jpn J Ophthalmol.* 2019;63(4):297-303.
- [20] Kaufman SC, Jacobs DS, Lee WB, Deng SX, Rosenblatt MI, Shtein RM. Options and adjuvants in surgery for pterygium: a report by the American Academy of Ophthalmology. *Ophthalmology.* 2013;120(1):201-8.
- [21] Hirst LW. The treatment of pterygium. *Surv Ophthalmol.* 2003;48(2):145-80.
- [22] Kurna SA, Altun A, Aksu B, Kurna R, Sengor T. Comparing treatment options of pterygium: limbal sliding flap transplantation, primary closing, and amniotic membrane grafting. *Eur J Ophthalmol.* 2013;23(4):480-7.
- [23] Küçükerdönmez C, Akova YA, Altınörs DD. Comparison of conjunctival autograft with amniotic membrane transplantation for pterygium surgery: surgical and cosmetic outcome. *Cornea.* 2007;26(4):407-13.
- [24] Kucukerdonmez C, Karalezli A, Akova YA, Borazan M. Amniotic membrane transplantation using fibrin glue in

pterygium surgery: a comparative randomised clinical trial. *Eye (Lond)*. 2010;24(4):558-66.

- [25] Bondalapati S, Ambati B. Minimally Invasive Pterygium Surgery: Sutureless Excision with Amniotic Membrane and Hydrogel Sealant. *Case Rep Ophthalmol*. 2016;7(1):79-84.



Open Access This article is licensed under a Creative Commons Attribution 4.0 International License, which permits use, sharing, adaptation, distribution and reproduction in any medium or format, as long as you give appropriate credit to the original author(s) and the source, provide a link to the Creative Commons license, and indicate if changes were made. The images or other third party material in this article are included in the article's Creative Commons license, unless indicated otherwise in a credit line to the material. If material is not included in the article's Creative Commons license and your intended use is not permitted by statutory regulation or exceeds the permitted use, you will need to obtain permission directly from the copyright holder. To view a copy of this license, visit <https://creativecommons.org/licenses/by/4.0/>.

© The Author(s) 2021