

Retinal Vascular Occlusive Disorders - Risk Factors

Shivcharan Lal Chandravanshi, Sunil Kumar Shrivastava, Priyanka Agnihotri, Smriti Gupta

Department of Ophthalmology, Shyam Shah Medical College, Rewa, MP, India



**Corresponding Author -*

Dr. Shivcharan Lal Chandravanshi,

Assistant Professor, Department of Ophthalmology, Shyam Shah Medical College, Rewa, MP, India Pin 486001

Abstract

Aims and Objective - The aim of the present study is to identify risk factors associated with different retinal vascular occlusive diseases (RVOD), such as central retinal artery occlusion (CRAO), hemi-retinal artery occlusion (HRAO), branch retinal artery occlusion (BRAO), cilioretinal artery occlusion (Cilio-RAO), central retinal vein occlusion (CRVO), branch retinal vein occlusion (BRVO), and hemi-retinal vein occlusion (HRVO).

Patients and Method - A cross-sectional study on 114 consecutive subjects, aged 24-96 years who have attended at the outpatient department of ophthalmology at Shyam Shah Medical College, Rewa, MP, were included in the study. The Duration of study was January 2016 to December 2017. Only patients with CRAO, BRAO, HRAO, Cilio-RAO, CRVO, BRVO, and HRVO were included in the study. Other retinal vascular disorders such as diabetic vaso-occlusive disease, anterior and posterior ischemic and non-ischemic neuropathy, hypertensive retinopathy, sickle cell retinopathy, retinal telangiectasia, retinopathy of prematurity, were excluded from study.

Results - We have included 114 patients, 64 cases (56.14%) males, 50 (43.85%) females, aged 56+/-8 years (range 24-96 years). Bilateral retinal vascular occlusive disorders were seen in only 4 cases (3.5%). Two patients have bilateral CRVO followed by one case of bilateral BRVO and one case of bilateral CRAO. Out of 114 patients, branch retinal vein occlusion was seen in 62 cases (54.38%), followed by central retinal vein occlusion in 36 cases (31.57%), CRAO in 8 cases (7.01%), and hemi-retinal vein occlusion in 4 cases (3.50%). Hypertension was the most common, (40 cases, 35.08%) risk factor identified for retinal vascular occlusive disorders followed by diabetes 24 cases (21.05%), combined diabetes and hypertension in 22 cases (19.29%), and atherosclerosis in 18 cases (15.78%).

Conclusions - Retinal vascular occlusive diseases have systemic as well as ocular risk factors. Understanding of these risk factors is essential for proper treatment of RVOD. Timely identification of risk factors for RVOD may helpful in decreasing ocular and systemic morbidity in these patients.

Keywords - Retinal vascular occlusive disorders, Central retinal artery occlusion, Branch retinal artery occlusion, Cilioretinal artery occlusion, Hemi-retinal artery occlusion, Central retinal vein occlusion, Branch retinal vein occlusion, Hemi-retinal vein occlusion, Diabetes, Hypertension, Hyperhomocysteinaemia

Introduction

Retinal vascular occlusion is a group of common vascular disorder of the retina and one of the most common causes of vision loss in clinical practice. Common vascular occlusive disorders of retina are central retinal artery occlusion (CRAO), central retinal vein occlusion, diabetic retinopathy, hypertensive retinopathy, retinal telangiectasia, sickle cell retinopathy, retinopathy of prematurity.^[1] Retinal vascular occlusive disorders (RVOD) are the common cause of visual disability. Both retinal artery and vein are vision threatening emergencies. Central retinal vein occlusion (CRVO) is an obstruction, usually as a result of thrombosis, of the retinal vein at or posterior to the optic nerve head.^[2] Branch retinal

vein occlusion (BRVO) is a complete or partial obstruction of a branch or tributary of the central retinal vein. Hemi-retinal vein occlusion (HRVO) affects either the superior or inferior hemisphere/hemi-retina. Risk factors for retinal vascular occlusive disorders are diabetes, hypertension, cardiovascular disorders, carotid insufficiency, hyperhomocysteinaemia, glaucoma, orbital disorders, atherosclerosis, collagen vascular disorders, oral contraceptive, alcoholism, hyperviscosity syndromes, hyperlipidemia, and smoking.^[3]

The aim of the present study is to identify the risk factors associated with different retinal vascular occlusive diseases, such as central retinal artery occlusion, hemi-retinal artery

occlusion (HRAO), branch retinal artery occlusion (BRAO), cilioretinal artery occlusion, central retinal vein occlusion, branch retinal vein occlusion, and hemi-retinal vein occlusion.

Material and Methods

This is hospital based, cross sectional study, conducted at the department of ophthalmology, Shyam Shah Medical College, Rewa MP. The duration of study was from January 2016 to December 2017. All newly diagnosed patients with central retinal artery occlusion, branch retinal artery occlusion, cilioretinal artery occlusion, hemi-retinal artery occlusion, central retinal vein occlusion, branch retinal vein occlusion, and hemi-retinal vein occlusion were included in the study. Demographic data (age sex, address), ocular and systemic complaints, past history of ophthalmic and systemic disorders were recorded. Special interest was taken on history pertaining to diabetes, hypertension, systemic collagen vascular disorders, coagulopathies, trauma, abnormalities contributing embolus formation, carotid insufficiency, infective vasculitis, and glaucoma. Swinging flash light test was done to rule out relative afferent pupillary defect or total afferent pupillary defect. Slit-lamp assisted comprehensive ophthalmic evaluation done in all cases. Intraocular pressure was measured with Goldmann applanation tonometer. Gonioscopy carries out in selected cases. Posterior segment examination was performed with the help of direct and indirect ophthalmoscope and 90 D lens. Fundus fluorescein angiography and optical coherence tomography were performed to know pattern of occlusion and assess macular involvement. Ultrasonography, computerized tomography and magnetic resonance imaging of orbit were ordered in selected cases of orbital inflammatory or infection condition to see crowding at orbital apex. Systemic evaluation was done by physician to rule out systemic disorders. All patients underwent routine blood investigations which includes complete blood count, blood sugar-fasting and postprandial, lipid profile, anti-nuclear antibodies, Anti-neutrophil cytoplasmic antibodies, antiphospholipid antibodies, complete coagulation profile, erythrocyte sedimentations rate, urine routine and microscopy. Echocardiography and carotid artery studies were done in selected cases. Other specific laboratory tests were done whenever necessary.

Informed consent was obtained from all participants before study. During entire study period investigators adhered to the tenets of Declaration of Helsinki. Patients data was feed in an excel sheet and analyzed. Results were expressed in percentage.

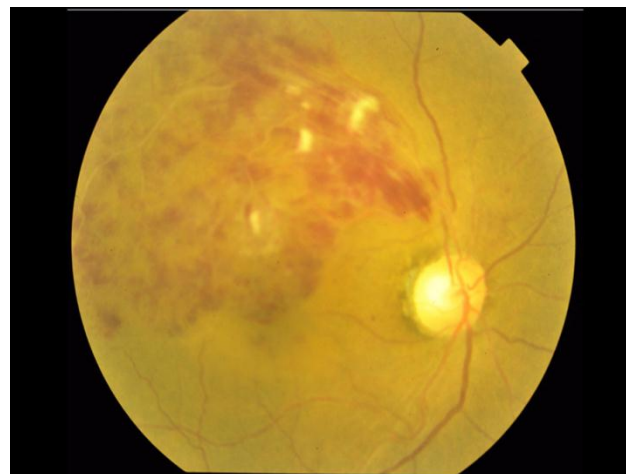

Figure 1: Fundus photograph of the right eye showing multiple superficial flame shaped, dot blot hemorrhages & cotton wool spots present in superotemporal quadrant of the retina involving the macular area with retinal thickening in macular area and absent foveolar reflex, suggesting of superotemporal BRVO.

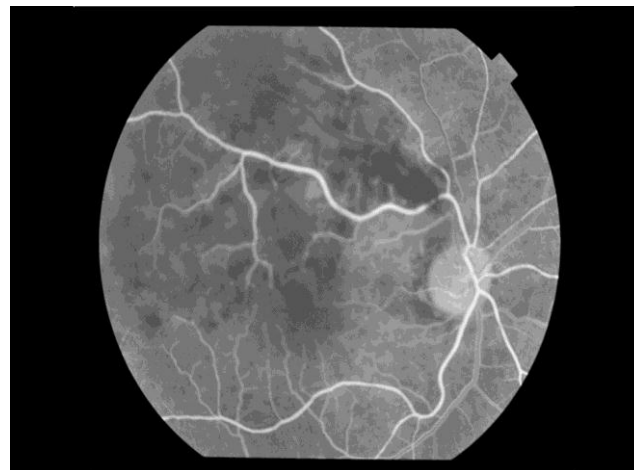

Figure 2: Fundus fluorescein angiography of superotemporal BRVO showing delayed venous filling and capillary non perfusion area at macula superiorly and blocked hypofluorescence due to hemorrhages.

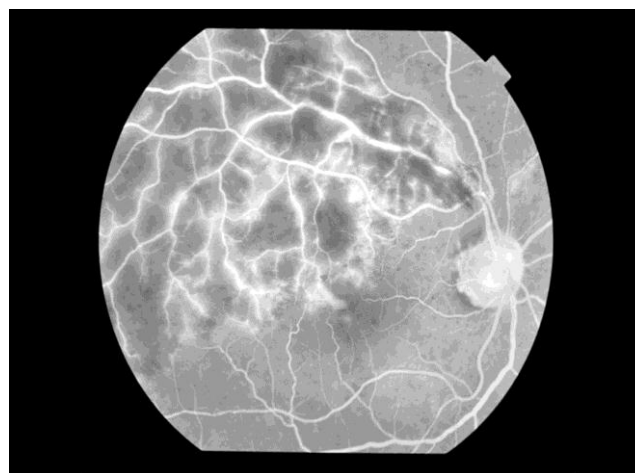


Figure 3: Fundus fluorescein angiography of patient with superotemporal BRVO showing extensive staining of vessels wall and cystoids macular edema in late stage.

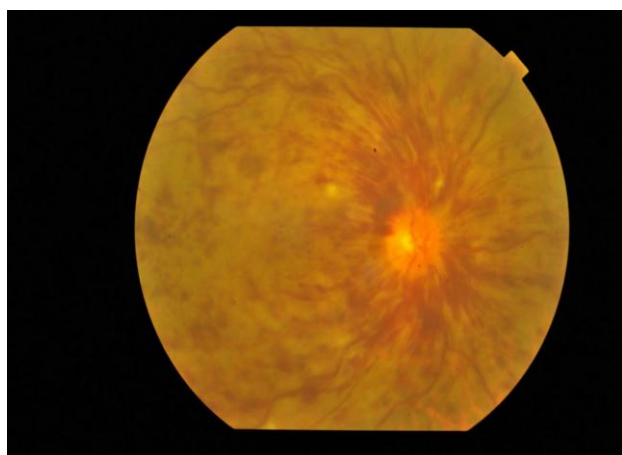


Figure 4: Fundus photograph of a patient with ischemic central retinal vein occlusion in the right eye showing disc edema, venous dilatation and tortuosity, multiple superficial and deep hemorrhages in general fundus and cotton wool spots.

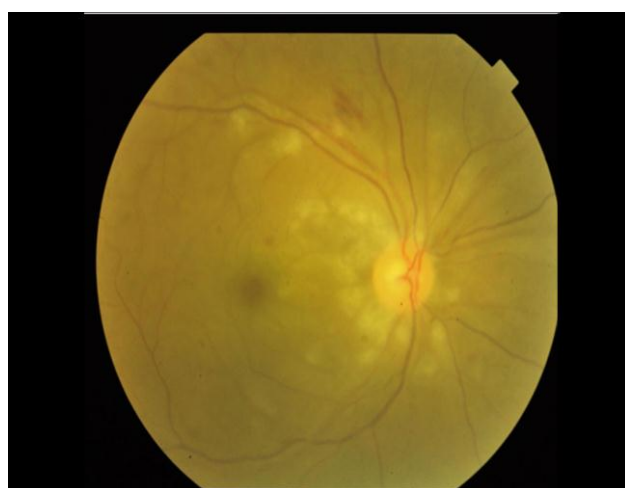

Figure 5: Fundus photograph of the right eye with central retinal artery occlusion showing opacified retina, superficial flame shaped hemorrhages and cherry red spot at macula.

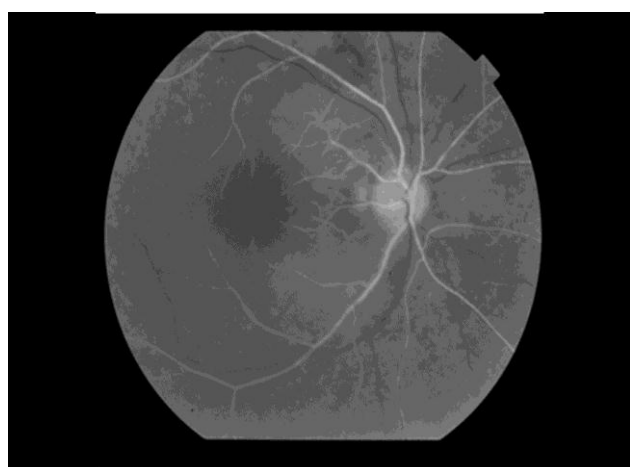


Figure 6: Fundus fluorescein angiography image of patient with CRAO in the right eye showing area of hypofluorescence in the area of retinal opacification around disc and macula and area of blocked fluorescence due to superficial hemorrhages superotemporal to disc.

Table No 1. Gender Distribution of Patients with Retinal Vascular Occlusive Disorders

Gender	No of patients	Percentage (%)
Females	62	54.38
Males	52	45.61

Table No. 2 Laterality and Retinal Vascular Occlusive Disorders

Laterality	No of patients	Percentage
Unilateral	110	96.49
Bilateral	4	3.50

Table no. 3. Pattern of retinal vascular disorders

Type of Retinal Vascular Disorders	No of patients	Percentage (%)	
Retinal arterial occlusive disorders	Central retinal artery occlusion	8	7.01
	Branch retinal artery occlusion	1	0.877
	Cilioretinal artery occlusion	1	0.877
	Hemi-retinal artery occlusion	1	0.877
Combined arterial and venous occlusive disorders	Combined central retinal and vein occlusion	1	0.877
Retinal venous occlusive disorders	Branch retinal vein occlusion	62	54.38
	Central retinal vein occlusion	36	31.57
	Hemi-retinal vein occlusion	4	3.50

Table no. 4: Types of central retinal vein occlusion on the basis of fundus fluorescein angiography

Types of Retinal vein occlusion	No of patients	Percentage (%)
Ischemic CRVO	12	33.33
Non-ischemic CRVO	24	66.66

Table No. 5: Risk factors for retinal vascular disorders

Risk factors for Retinal vascular occlusion	No of patients	Percentage (%)
Hypertension	40	35.08
Diabetes	24	21.05
Both Diabetes and Hypertension	22	19.29
Atherosclerosis	18	15.78
Cardiovascular disorders	9	7.89
Hyperhomocysteinaemia	8	7.01
Hyperlipidemia	7	6.14
Glaucoma	5	4.38
Collagen vascular disorders	4	3.50

Alcoholism	4	3.50
Smoking	4	3.50
Carotid insufficiency	3	2.63
Hyperviscosity syndromes	3	2.63
Oral contraceptive	2	2.75
Others	12	10.52

Results

Total 114 patients of retinal vascular occlusive disorders were identified during period of two years. Out of 114 patients, 64 cases (56.14%) were males and 50 (43.85%) were females (Table No 1), aged 56+/-8 years (range 24-96 years). Bilateral retinal vascular occlusive disorders were seen in only 4 cases (3.5%) (Table 2). Two patients have bilateral central retinal vein occlusion followed by one case of bilateral branch retinal artery occlusion and one case of bilateral artery central artery occlusion. Out of 114 patients, branch retinal vein occlusion was seen in 62 cases (54.38%) (Figure 1, 2 and 3), followed by central retinal vein occlusion in 36 case (31.57%) (Figure 4), hemi- retinal vein occlusion in 4 cases (3.50%) and 8 cases (7.1%) CRAO (Figure 5 and 6) (Table 3). The higher frequency (60%) of branch retinal vein occlusion was found in the superotemporal quadrant. Out of 36, CRVO cases, 66.66 % were non-ischemic and 33.33 were ischemic type of CRVO (Table 4). Hypertension was the most common (40 cases, 35.08%) risk factor identified for retinal vascular occlusive disorders followed by diabetes 24 cases (21.05%), combined diabetes and hypertension in 22 cases (19.29%), and atherosclerosis 18 cases (15.78%) (Table No 5).

Discussion

Retinal vascular disorders are broadly classified as retinal venous occlusive diseases and retinal arterial occlusive disorders. Retinal venous occlusive disorders further divided into central retinal vein occlusion (CRVO), branch retinal vein occlusion (BRVO), and hemi-retinal vein occlusion (HRVO). Retinal arterial occlusive disorders further clinically divided into central retinal artery occlusion (CRAO), hemi-retinal artery occlusion (HRAO), branch retinal artery occlusion (BRAO), and cilioretinal artery occlusion.

According to population bases studies, the prevalence of CRVO is 0.1% to 0.4%.^[3,4]

Retinal vascular occlusion disorders can affect any age group of population. However, these are commonly seen in old persons. The ischemic type of venous occlusive disorders occurs more often in patients above 65 years while non-ischemic type of retinal venous occlusive disorders more common in patients less than 45 years. Central retinal artery occlusion is common in 50-60 age group.^[5] In present study, retinal vascular disorders were most frequently seen

in 50-60 years of age group. Both venous and arterial retinal occlusive disorders are slightly more common in males than females.^[6] Males were more affected in current study. This is probably because of easy access to medical care for males in comparison to females in India. In Martínez *et al* study, males are outnumbered females.^[7] Branch retinal vein occlusion is four times more common than central retinal vein occlusion.^[6] Hayreh and Zimmerman noted ischemic CRVO only 16% of cases.^[8] In present study, 33.33% cases have ischemic CRVO. Risk factor for retinal vascular disorders are advanced age, hypertension, diabetes, atherosclerosis, cardiovascular disorders, hyperhomocysteinaemia, hyperlipidemia, glaucoma, collagen vascular disorders, alcoholism, carotid insufficiency, smoking, hyperviscosity syndromes, and oral contraceptives

Systemic hypertension was the most common, (40 cases, 35.08%) risk factor identified for retinal vascular occlusive disorders followed by diabetes 24 cases (21.05%), combined diabetes and hypertension in 22 cases (19.29%), and atherosclerosis 22 cases (19.29%). Newman-Casey *et al* reported hypertension and diabetes as major systemic risk factors for development of retinal vein occlusion.^[9] Rudkin *et al* found hyperlipidemia as a most frequently systemic risk factor for non-arteritic CRAO^[10]

Hyperhomocysteinaemia is a newly emerging risk factor for retinal vascular occlusive disorders.^[11] In current study, 7% of cases of retinal vascular disorders are due to hyperhomocysteinaemia. Elevated level of homocysteine in blood promotes atherosclerosis through increased oxidant stress, impaired vascular endothelial function, and induction of thrombosis.^[12] Narrow anterior chamber angle and higher blood urea concentration are also risk factor for central retinal vein occlusion.^[13] However author did not found these risk factors in current study. Both venous and arterial occlusive retinal disorder are seen in Hyperhomocysteinaemia.^[14] Valvular diseases of the heart, and carotid artery stenosis or plaques are common cardiovascular risk factor in development of retinal vascular occlusive disorders.^[15] In present study, only 8% of cases of retinal vascular disorders have cardiovascular risk factors. Oral contraceptive pills are risk factor for RVOD in young females.^[16] Retinal vascular occlusion is seen in 2.75% cases due to use of oral contraceptive pills. Oral contraceptive pills contain high doses of estrogen which accelerate thrombosis inside veins.

Conclusion

Retinal vascular occlusive disorders are common retinal disorders among elderly peoples. The main risk factors of retinal vascular disorders are hypertension, diabetes, hyperhomocysteinaemia, dyslipidemia. Regular ophthalmic and physical check up is essential in patients having

systemic risk factors for retinal vascular occlusive disorders. Early detection and treatment of retinal vascular occlusion disorders might be helpful in preventing blindness among ageing population.

References

- [1] Hayreh SS. Prevalent misconceptions about acute retinal vascular occlusive disorders. *Prog Retin Eye Res.* 2005; 24(4):493-519.
- [2] Hayreh SS, Zimmerman B, McCarthy MJ, Podhajsky P. Systemic diseases associated with various types of retinal vein occlusion. *Am J Ophthalmol.* 2001; 131:61-77.
- [3] Cugati S, Wang JJ, Rochtchina E, Mitchell P. Ten-year incidence of retinal vein occlusion in an older population: the Blue Mountains Eye Study. *Arch Ophthalmol.* 2006; 124(5):726-32.
- [4] Klein R, Klein BE, Moss SE, Meuer SM. The epidemiology of retinal vein occlusion: the Beaver Dam Eye Study. *Trans Am Ophthalmol Soc.* 2000; 98:133-41.
- [5] Mitchell P, Smith W, Chang A. Prevalence and associations of retinal vein occlusion in Australia. The Blue Mountains Eye Study. *Arch Ophthalmol.* 1996; 114(10):1243-7.
- [6] Kolar P. Risk factors for central and branch retinal vein occlusion: a meta-analysis of published clinical data. *J Ophthalmol.* 2014; 2014:724780.
- [7] Martínez F, Furió E, Fabiá MJ, Pérez AV, González-Albert V, et al. Risk factors associated with retinal vein occlusion. *Int J Clin Pract.* 2014; 68(7):871-81.
- [8] Hayreh SS, Zimmerman MB. Fundus changes in central retinal vein occlusion. *Retina.* 2015 ;35(1):29-42
- [9] Newman-Casey PA, Stem M, Talwar N, Musch DC, Besirli CG, Stein JD. Risk factors associated with developing branch retinal vein occlusion among enrollees in a United States managed care plan. *Ophthalmology.* 2014; 121(10):1939-48.
- [10] Rudkin AK, Lee AW, Chen CS. Vascular risk factors for central retinal artery occlusion. *Eye (Lond).* 2010 ;24(4):678-81.
- [11] Abu El-Asrar AM, Abdel Gader AG, Al-Amro SA, Al-Attas OS. Hyperhomocysteinemia and retinal vascular occlusive disease. *Eur J Ophthalmol.* 2002; 12(6):495-500.
- [12] Guthikonda S, Haynes WG. Homocysteine as a novel risk factor for atherosclerosis. *Curr Opin Cardiol.* 1999;14(4):283-91.
- [13] Jonas JB, Nangia V, Khare A, Sinha A, Lambat S. Prevalence and associations of retinal vein occlusions: the Central India Eye and Medical Study. *Retina.* 2013; 33(1):152-9.
- [14] Wenzler EM, Rademakers AJ, Boers GH, Cruysberg JR, Webers CA, Deutman AF. Hyperhomocysteinemia in retinal artery and retinal vein occlusion. *Am J Ophthalmol.* 1993; 115(2):162-7.
- [15] Lang GE, Spraul CW. [Risk factors for retinal occlusive diseases]. *Klin Monbl Augenheilkd.* 1997; 211(4):217-26.
- [16] Stowe GC 3rd, Zakov ZN, Albert DM. Central retinal vascular occlusion associated with oral contraceptives. *Am J Ophthalmol.* 1978; 86(6):798-801.