



Fortuitous Discovery of a Fahr Syndrome in a Psychiatric Environment

Ibra DIAGNE ^{*1}, Maimouna DIEYE ², Khadim SECK ³, Ndèye Dialé NDIAYE-NDONGO ⁴, Aida SYLLA ⁴

¹Health Emergency Operations Center (COUS), Ministry of Health and Social Action (MSAS), Senegal, ibradiagnepsy@yahoo.fr

²Psychiatrist and Addictologist, Head of Addictology Unit of the National Psychiatric Hospital Center of Thiaroye, Dakar / Senegal; maimounadiyepsy@gmail.com

³Psychiatrist and Head of Department of the Psychiatry Unit of the National Center for Social Reintegration Imam Assane Cisse, Kaolack / Senegal; bayekha04@hotmail.com

⁴Psychiatrist, Systemic Psychotherapist. Full Professor in Psychiatry at the Medical Faculty of Cheikh Anta Diop University in Dakar / Senegal; dialouchandongo@yahoo.fr, mhenendiaye@yahoo.fr

*Corresponding author: Ibra DIAGNE; ibradiagnepsy@yahoo.fr, ibra.diagne@ucad.edu.sn

Received 09 December 2021;

Accepted 23 February 2022;

Published 07 March 2022

Abstract

Fahr syndrome is a rare anatomical and clinical entity characterized by bilateral and symmetrical intracerebral calcifications located in the basal ganglia. It is most often associated with disorders of phosphocalcic metabolism and its symptomatology is very heterogeneous ranging from simple headaches to constituted neuropsychiatric disorders. We report the case of a 42-year-old female patient, followed in a psychiatric department since the age of 30 years for a psychotic symptomatology of schizophrenic appearance and well stabilized 8 treatment. On the occasion of a consultation for a psychotic picture associated with repetitive tonicoclonic convulsions and a confusional note, diffuse calcifications of the lenticular nuclei and the cephalic regions of the head of the caudate nuclei were objectified on cerebral computed tomography (CT) and hypocalcemia on biology. These anatomic-clinical and biological data allowed us to retain the Fahr syndrome. This clinical observation shows the importance of suspecting this syndrome in the presence of an abruptly changing chronic psychiatric picture associated with neurological signs in order to adapt the global management. A correction of the phosphocalcic metabolism disorders often leads to a clear improvement.

Keywords: Fahr syndrome, psychotic disorders, phosphocalcic metabolism, psychiatry.

Introduction

First described in the 1930s by a German neurologist, Fahr syndrome is defined by the presence of bilateral and symmetrical intracerebral calcifications located in the basal ganglia [1-5]. A rare condition, whose pathophysiology remains unclear, is associated with disorders of phosphocalcium metabolism and mainly with primary or secondary hypoparathyroidism [4,5]. Fahr syndrome is difficult to suspect clinically because of its clinical polymorphism. It may remain asymptomatic and be discovered incidentally or be revealed by various neuropsychiatric symptoms [3,6]. Psychiatric disorders are variable: mood disorder, anxiety symptoms, delusional syndrome with paranoid delusions, and idea of reference or influence, complex auditory and visual hallucinations [2,7].

We report in the present observation the case of a 42-year-old patient, with a history of poorly observant thyrotoxicosis, who

was received in psychiatric consultation for psychomotor instability, acousticoverbal hallucinations and behavioral oddities, whose examinations during follow-up led to the incidental discovery of a Fahr syndrome.

Clinical Observation

Mrs. S is a 42-year-old Senegalese woman, married, of Muslim religion, mother of four children and a shopkeeper when we first received her in emergency at the outpatient psychiatry clinic of the Dalal Xel mental health center in Thiès, Senegal on June 19, 2020. She was from a polygamous family and a second degree consanguineous marriage. She was the third of four children, not attending French school. Mrs. S was brought in by one of her daughters and her husband for behavioral oddities, acousticoverbal hallucinations, and psychomotor agitation. In her personal history, she had been followed since the age of 30 years in psychiatry, for a

picture that progressively developed, made of mystical delusions, behavioral oddities, cenesthesia sensations like tingling and a total insomnia well supported. The diagnosis retained was that of a schizophrenic disorder and the patient was treated with two classical antipsychotics based on Haloperidol tablet 5mg (10mg per day) and Chlorpromazine tablet 100mg (200mg per day) associated with a synthetic antiparkinsonian (Trihexyphenidyl tablet 5mag per day). The evolution was marked by a good improvement of the clinical picture with disappearance of the hallucinations and restoration of sleep, a regular follow-up and a good adhesion to the treatment. However, she kept her complaints of cenesthesia sensations but they were well tolerated by the patient and her family. We also found a notion of thyrotoxicosis which had motivated a thyroidectomy about 6 years ago and the patient is still under levothyroxine with irregular follow-ups and a lack of compliance. It should be noted that there were no similar cases in the family.

The clinical examination during the first consultation showed a blood pressure of 110/70 mm Hg, a pulse of 70/minute, a weight of 59 kg for a height of 1.68 m with a temperature of 36.3°C. The psychiatric examination showed an unstable patient with a disengaged behavior. The contact was difficult, superficial even indifferent. Her speech was poor, with sometimes wrong answers and verbal incoherence. Her thought was vague, bizarre with a persecution, possession and mystical religious delirium, badly systematized, with hallucinatory and interpretative mechanism against her husband and her neighbors without thymic symptoms. She was well oriented in time and space and presented neither confusing elements, nor physical signs of appeal. Given this clinical picture and her psychiatric history, the diagnosis of schizophrenic disorder was retained. She was put on the same treatment as before, i.e. haloperidol 5mg tablet (10mg per day) associated with Chlorpromazine 100mg tablet (200mg per day) and a synthetic antiparkinsonian (trihexyphenidyl 5mag tablet per day).

One week after the beginning of this ambulatory treatment, the patient was brought back in emergency by her family for an accentuation of the psychotic symptomatology with the emergence of neurological signs such as dyskinesia and hand tremors associated with several sudden losses of consciousness, with fall

and post critical coma. The family also reported that the patient complained of moderate headaches and frequent and almost constant forgetfulness. The psychiatric examination of this second consultation had objectified a patient disoriented in time and space, with a frozen look, perplexed, not answering questions. The neurological examination had shown a confusing note with akinesia and a walking with small steps. We did not observe any meningeal stiffness or sensory-motor deficit. The osteotendinous reflexes were present and symmetrical without cranial nerve involvement. Given the modification of the previous clinical picture, the poor response to classical antipsychotics and the emergence of neurological signs, we thought of a cerebral organicist. Thus, a cerebral CT scan was requested and had objectified diffuse calcifications of the lenticular nuclei and the cephalic regions of the head of the caudate nuclei as well as the right and left para-ventricular subcortical regions evocative of a Fahr syndrome (Figure 1). We completed the explorations by a phosphocalcic assessment which revealed a severe hypocalcemia at 1.2mmol.L-1 (normal value 2.2 and 2.6mmol-L-1), a phosphoremia at 1.40mmol/L (normal value 0.80 - 1.45mmol-L-1).

The blood count, liver, lipid and renal tests were normal as well as the electroencephalogram. The requested brain MRI and lumbar puncture were not performed because the patient did not have the financial means to do them. Thus, in view of the clinical, radiological and biological elements, the diagnosis of a psychotic disorder associated with a Fahr's syndrome secondary to hypoparathyroidism was retained in our patient. The advice of neurologists and endocrinologists was sought and a treatment was then instituted, combining calcium (2 g per day), vitamin D therapy and Risperidone (2 mg per day). The evolution was marked after two weeks by an improvement of the neuropsychiatric picture with a clear decrease of the delirious syndrome, a normalization of the sleep without any side effects of the drugs and no epileptic seizures and an improvement of the memory. The calcium balance returned to normal after three weeks. Mrs. S is still under psychiatric care and her condition is currently stable, although she continues to present moments of verbal incoherence and some cognitive disorders. After stabilization of the psychiatric picture, the patient was referred to her endocrinologist for levothyroxine monitoring.

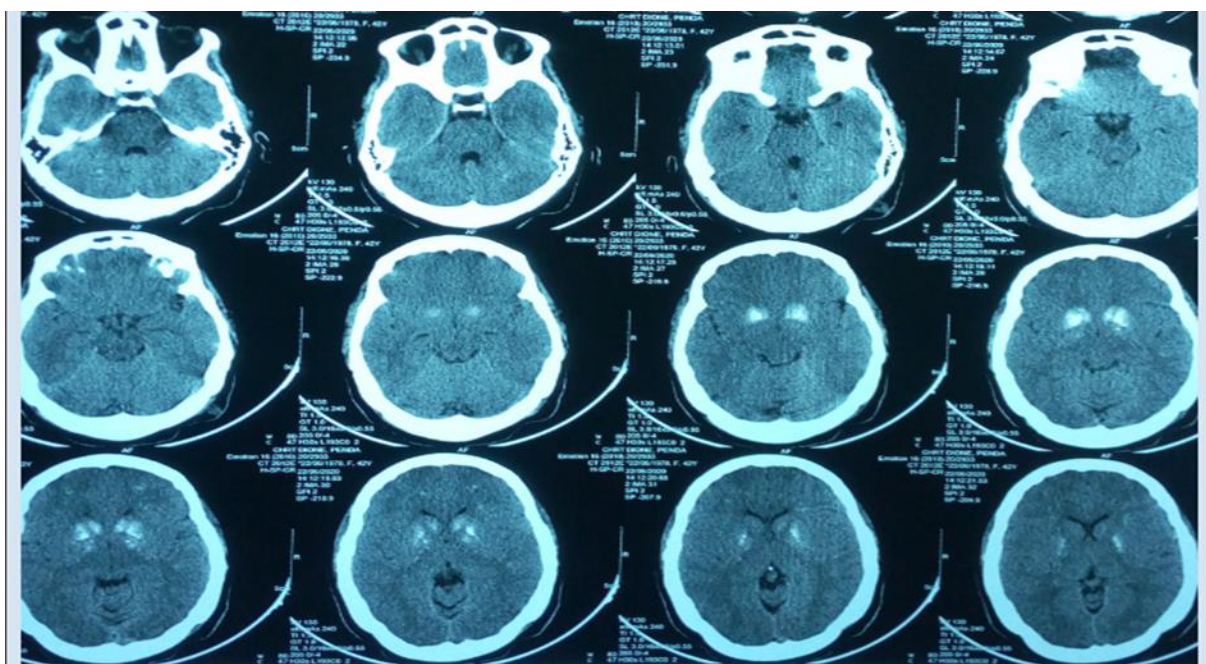


Figure 1: Axial slice brain CT showing diffuse calcifications of the lenticular nuclei and cephalic regions of the head of the caudate nuclei as well as the right and left para-ventricular subcortical regions

Discussion

Case reports of Fahr syndrome have increased in the medical literature over the past several years despite an estimated prevalence of 0.5% [8]. Many physicians, especially psychiatrists in our work setting are unaware of its diagnosis and treatment. This under-recognition of this syndrome may be due to clinical polymorphisms [6]. Fahr syndrome is usually difficult to suspect clinically because the clinical manifestations do not correspond to any specific picture. It may remain asymptomatic and be discovered incidentally during cerebral radiological examinations for another reason or following psychiatric manifestations that are resistant to treatment [9]. This was the case in our patient who had been under psychiatric care for several years, but who underwent a cerebral CT scan which revealed calcifications of the basal ganglia. Generally, Fahr's syndrome is silent in the first 2 decades and manifests itself most often, either around 30 years of age by the appearance of neuropsychiatric disorders, in particular pseudo-psychotic or schizophrenic manifestations [10], or around 60 years of age by a progressive dementia picture [11]. It should be noted that our patient was followed in psychiatry when she was 30 years old and the disorders only revealed themselves at the age of 40 years by psychotic manifestations and the diagnosis of Fahr's disease was suspected after a symptomatic evolution of several years. The neurological symptoms were only objectified at a later stage. The initial manifestations of the disease were very suggestive of a chronic psychotic disorder with a good response to antipsychotic drugs and good inter-critical intervals. It was only the modification of the clinical picture and the unfavorable evolution of the symptomatology under neuroleptics that directed the physicians towards the path of organicity. Thus, the brain scan and the biological tests made it possible to retain the diagnosis of a Fahr syndrome.

The diagnosis of Fahr's syndrome is radiological, which can have different clinical manifestations, especially psychic, which are present in 45% of cases [12]. Some authors [13,14] have suggested a causal relationship between intracerebral calcifications and schizophrenia, in view of the psychotic manifestations presented by some patients and matching a schizophrenic disorder, but this remains uncertain. Fahr's syndrome refers to conditions with calcifications of the basal ganglia. It is often associated with disturbances in phosphocalcic metabolism, unlike Fahr's disease, which is said to be idiopathic or primary, of genetic or sporadic cause [15]. It is most often associated with dysparathyroidism, which is the most classical abnormality associating hypocalcemia, hyperphosphatemia, hypocalcaemia, hypophosphaturia and a decrease in serum parathormone levels [13]. A study conducted by Chabot et al. in 2001 [14] showed that the risk of psychotic symptoms in Fahr's disease was proportional to the diffusion of calcifications in the grey nuclei of the brain. In our patient, the imaging revealed a more or less diffuse involvement of the calcifications. This finding supports the hypothesis that schizophrenia is related to a dysregulation of the thalamo-cortico-striatal circuit [16]. However, the pathophysiology of Fahr's syndrome is not completely clear. Therapeutically, the prognosis of Fahr's syndrome is good, as the clinical and neuropsychological signs regress after correction of the phosphocalcic disturbances [15,17,18]. In our patient, correction of the phosphocalcic disorders associated with neuroleptic treatment led to an improvement of the neuropsychiatric picture in less than two weeks. Our patient was on Risperidone, justified by the psychotic elements in the foreground of the clinical picture. According to Nicolas & Hannequin [8]

antipsychotics are strongly recommended when psychiatric symptoms are prominent.

Conclusion

Fahr's syndrome is a rare entity, even underestimated by many psychiatric physicians in our work context, mainly because of its clinical polymorphism. This observation shows the interest for physicians to look for abnormalities of phosphocalcic metabolism and cerebral calcifications in patients presenting a chronic psychiatric picture associated with neurological signs. The early diagnosis of this syndrome allows the introduction of adequate treatment and avoids the wandering of patients from one specialty to another, but also the use of traditional practitioners. A correction of the phosphocalcic disorders often leads to a clear improvement associated or not with a psychotropic treatment.

Declarations

Conflicts of interest:

No

Sources of funding

None

Author's contributions

All authors contributed to this work from the conception, reading and approval of the final version of the manuscript.

References

- [1] Fahr T. Idiopathische verkalkung der hirngefäße. Zentrabl Allg Pathol. 1930; 50:129-33.
- [2] Chevalier D, Marie I, Tillon J, Lévesque H. Une cause de calcifications intracérébrales à ne pas méconnaître: le syndrome de Fahr. Rev Med Interne 2005; 26:668-77
- [3] Manyam BV. What is and what is not "Fahr's disease". Parkinsonism Relat Disord 2005; 11(2): 73–80.
- [4] El Maghraoui A, Birouk N, Zaim A. Fahr syndrome and dyspara-thyroidism. 3 cases. Presse Med 1995; 24:1301-4.
- [5] Khadir K, Moussaid L, El Ouazzani T. Fahr syndrome associated to hypoparathyroidy, revealed by dermatologic manifestation. Ann Dermatol Venereol 2004; 131:979–83.
- [6] Morgante L, Trimarchi F, Benvenega S. Fahr's disease. Lancet 2002; 359:759.
- [7] El Hechmi S, et al. Trouble psychotique secondaire à un syndrome de Fahr: à propos d'une observation. Encéphale (2013), <http://dx.doi.org/10.1016/j.encep.2013.04.012>
- [8] Nicolas G, Hannequin D. Calcifications idiopathiques des noyaux gris centraux (maladie de Fahr). Prat Neurol FMC 2013; 4: 143–150.
- [9] Bagué B, Salifou Abdou MM, Sawadogo BKCCD, Nanema D, Kambou CS, Karfo K et al. Les manifestations psychiatriques du syndrome de Fahr: à propos d'un cas suivi au service de psychiatrie du Centre Hospitalier Universitaire de Yalgado Ouédraogo

- d'Ouagadougou, Burkina Fasso. *Jaccr Africa* 2020; 4 (4): 316-320.
- [10] Klein C, Vieregge P. Fahr's disease – far from a disease. *Mov Disord* 1998; 13:620-1.
- [11] Lauterbach EC, Cummings JL, Duffy J, et al. Neuropsychiatric correlates and treatment of lenticulostratial diseases: a review of the literature and overview of research opportunities in Huntington's, Wilson's, and Fahr's diseases. A report of the ANPA Committee on Research. *American Neuropsychiatric Association. J Neuropsychiatry Clin Neurosci* 1998; 10: 249–66.
- [12] Dombia M, Kouassi L, Kouame Assouan AE, et al. Maladie de Fahr révélée par des troubles de la marche et de la parole. *Rev Int Sc Méd* 2006; 8(2): 32-5.
- [13] Otheman Y, Khalloufi H, Benhima I, et al. Neuropsychiatric symptoms revealing pseudohypoparathyroidism with Fahr's syndrome. *Encéphale* 2011; 37: 54-8.
- [14] Chabot B, Roulland C, Dollfus S. Schizophrenia and familial idiopathic basal ganglia calcification: a case report. *Psychological Medicine* 2001; 31: 741-7.
- [15] Nicolas G, Battini JL, Giovannini D, Sitbon M, Hannequin D, (2015) De l'identification des bases moléculaires des calcifications cérébrales primaires aux mécanismes physiopathologiques: de nouvelles étapes. *Rev Neurol* 71: 685–687
- [16] Ring HA, Serra-Mestres J. Neuropsychiatry of the basal ganglia. *J Neurol Neurosurg Psychiatry* 2002; 72:12-21.
- [17] Ceccaldi B, el Maghraoui A, Mayaudon H, Dupuy O, Eulry F, Bauduceau B. Syndrome de Fahr et hyperparathyroïdie. *Presse Med.* 1999 Apr 3; 28(13):689.
- [18] Younes-Mhenni S, Tobois S, Streichenberger N, et al. Encephalomyopathie mitochondriale de type Melas associée à un syndrome de Fahr avec calcifications cérébelleuses. *Rev Med Interne.* 2002 Dec; 23(12):1027-9.



Open Access This article is licensed under a Creative Commons Attribution 4.0 International License, which permits use, sharing, adaptation, distribution and reproduction in any medium or format, as long as you give appropriate credit to the original author(s) and the source, provide a link to the Creative Commons license, and indicate if changes were made. The images or other third party material in this article are included in the article's Creative Commons license, unless indicated otherwise in a credit line to the material. If material is not included in the article's Creative Commons license and your intended use is not permitted by statutory regulation or exceeds the permitted use, you will need to obtain permission directly from the copyright holder. To view a copy of this license, visit <https://creativecommons.org/licenses/by/4.0/>.

© The Author(s) 2021