



To Determine the Diagnostic Accuracy of Magnetic Resonance Spectroscopy (MRS) In Detection of Prostate Cancer in Patients with Prostatomegaly and Elevated PSA Levels, Taking Biopsy as Gold Standard

Dr. Rafay Gul ¹, Dr. Hina Pathan ^{*1}, Dr. Jaideep Darira ¹, Dr. Kashif Shazlee ², Dr. Ashraf Amir Ali ³,
Dr. Sara Zafar ¹

¹Department of Radiology, Dr Ziauddin Hospital, Karachi, 74700, Pakistan

²Department of Radiology, Indus Hospital, Karachi, 75190, Pakistan

³Department of Radiology, National Institute of Child Health, Karachi, 75510, Pakistan

*Correspondence author: Dr. Hina Pathan; hn.pathan889@gmail.com

Received 31 December 2022;

Accepted 30 January 2021;

Published 02 February 2022

Abstract

Objective: To determine the diagnostic accuracy of magnetic resonance spectroscopy(MRS) in detection of prostatic cancer in patients with prostatomegaly and elevated PSA levels, taking biopsy as gold standard. **Study Design:** Cross sectional study. **Duration and place of study:** Department of Diagnostic Radiology, Dr. Zia Uddin University Hospital, Karachi from February 1 to August 31,2020. **Methods:** High risk patients for prostatic carcinoma and patients meeting inclusion criteria were referred to the radiology department of Dr, Zia Uddin hospital for MRI pelvis. Purpose and procedure of study were explained after taking an informed consent. All examinations were performed and the collected data on MR spectroscopic imaging protocol (spectra and associated metabolic ratios) was more pronounced than conventional spin echo sequences. Choline peak elevation and choline-creatinine ratios > 2 in a suspected area as compared to adjacent normal prostatic tissue was labelled as prostate cancer. This information along with the age, duration of symptoms, patient's educational status, and weight of patient and size of lesion were collected. **Results:** The specificity sensitivity, positive and negative predictive value and accuracy of MRS for diagnosis of Prostate cancer was 85.40%, 78.84%, 69.64%, 90.48% and 81.22%, respectively. **Conclusion:** The combined effectiveness of conventional MR images along with metabolic data of MRSI will help to enhance and make presumptive diagnosis of prostate carcinoma. The implementation and standardization of MRS will definitely help in future to diagnose disease in very early stage, thus reducing the chance of morbidity and mortality to a certain level.

Keywords: Magnetic resonance spectroscopy(MRS), Prostatic cancer, prostatomegaly, elevated PSA levels, biopsy.

Introduction

Prostate cancer remains the leading cause of death in men according to 2016 American cancer society statistics [1]. This cancer is most likely diagnosed when either it is in the glandular tissue (local disease) or spread in nearby by organs(advance disease).Mostly surgeon perform digital rectal examination for palpable nodule or enlarge prostate gland as a first line diagnostic tool but its sensitivity remains negative for non-palpable nodules [2]. Similarly the role of prostate specific antigen is uncertain with respect to the upper limit value for screening purpose and its low specificity creates clinical challenge. The elevated PSA value

above normal in patient who actually have cancer on biopsy have ratio of 4:1. One third of patients who are diagnosed to have carcinoma have normal PSA values [3]. Trans-rectal - Ultrasonography and guided biopsy provides a best method for glandular tissue biopsy. [4,5] but its use is limited to locally stage the disease because of operator dependency and failure to determine the extracapsular extent which limits the accuracy of using this technique [6,7]. The other upgrade tool for the diagnosis and evaluation of tumor stage is magnetic resonance imaging (MRI) which remains the modality of choice. The sensitivity of magnetic imaging resonance is higher (51–89%) than trans-rectal ultrasonography (TRUS) (27– 86%). However, both methods

present a low specificity (58–94%) [6,7]. Recently, a new diagnostic hope is emerging in the form of magnetic resonance spectroscopy. The initial anatomical data is provided by MRI, with the help of MRS, metabolic indicators are detected within the prostate gland, thus combined technique enhances the accuracy in the probable localization of the tumor [6,8-12]. Approximately 30% of cancers are missed on trans rectal ultrasound (TRUS) - guided sextant biopsies when compared with complete surgical excision for tumor localization, biopsy results had a positive predictive value (PPV) of 83% and a negative predictive value (NPV) 36% respectively [13]. As a result, unnecessary biopsies are performed in men do not have cancer. The significant cancer in clinically presented patients are sometime missed and insignificant cancers are often detected [14,15].

The low signal intensity on T2-weighted sequences, in the peripheral zone makes the diagnosis but it is not specific and similar change can be seen with infection, bleeding after biopsy, post radiation fibrosis or hormonal treatment [13-16,18,19]. There is some evidence that MP-MRI tends to systematically overlooks low-risk disease and detect higher risk disease [17] which makes it suitable for potential triage test. The recent introduction of 3D MR spectroscopy imaging (3D-MRSI) into clinical practice adds information to the morphological data of MR imaging, enabling a more specific diagnosis of prostate cancer. A number of studies in controlled environment [22-24] and in living beings [20,21] has found high choline levels and low citrate levels in the areas affected by prostate carcinoma. The promising results achieved with 3DMRSI in prostate cancer identification [25], its volume, extracapsular extension, post radiation changes, aggressiveness, are promising. Due to short number of studies its role is still to be proven. The reported values of sensitivity and specificity of 89% and 79% by Emanuele Cassini et al established the additional value of 3D magnetic resonance spectroscopy (3D-MRS) imaging to MR imaging in the diagnosis of prostate cancer. But when compared to my study, it includes sensitivity and specificity of 89% and 91% respectively. Furthermore, due to the fact that all the studies published to date have been conducted by a limited number of research groups.

The aim of this study is to define the contribution of MRSI to MR imaging in diagnosing the prostate cancer.

Materials and Methods

This cross-sectional study was conducted at the Department of Diagnostic Radiology, Dr. Zia Uddin University Hospital, Karachi. The duration of study was from February 1 to August 31, 2020. High risk patients for prostatic carcinoma and patients meeting inclusion criteria were referred to the radiology department of Dr. Ziauddin hospital for MRI pelvis. Purpose and procedure of study were explained after taking an informed consent. All examinations were performed using 1.5 TMR units Magnetom Harmony by (SIEMENS) using surface coil. The thin sections in Axial, coronal and sagittal in planes, T2 Weighted fast spin echo (FSE) images with high resolution were obtained from pelvis. The following parameters were taken: TR range 5000-7000 MS, TE 100 MS, field

of view (FOV) 20cms, slice thickness of 3mm, intersection gap of 1mm, matrix 256x256.

Initially the axial T2-weighted images were studied, followed by MR spectroscopic imaging volume that focuses on prostate gland and excluding the rectum and periprostatic fat. Three dimensional MR spectroscopic imaging data was acquired by using a water- and lipid-suppressed double-spin-echo point resolved spectroscopy sequence with spectral-spatial pulses for the two 180° excitation pulses, which was optimized for the quantitative detection of choline, creatine, polyamines, and citrate. Outer-voxel saturation pulses were used to further sharpen the volume selection and conform the selected volume to the shape of the prostate (to eliminate susceptibility artifact from periprostatic fat and rectal air). Data sets were acquired with 16 x 8 x 8 phase encoded spectral arrays (1024 voxels with a spatial resolution of 0.24–0.34 cm³), 1000/130, and a 17-minute acquisition time. Three-dimensional MR spectroscopic imaging data were processed offline at using in-house software that integrated peak area values for choline, creatine, and citrate, and peak choline-to-creatine and choline plus creatine –to-citrate area ratios were automatically calculated for each voxel. MR spectroscopic imaging data was more pronounced the corresponding axial T2-weighted MR image. The rising Choline peak and choline-creatinine ratios > 2 in a suspected area as compared to adjacent normal prostatic tissue was labelled as prostate cancer. This information was recorded along with other parameters like age, duration of symptoms, patient’s educational status, patient’s weight and size of lesion.

Results

378 patients fulfilling selection criteria were included in the study.

In table 1 descriptive statistics of all quantitative variables was calculates in term of mean and standard deviation. Patient’s mean age was 64.33±9.65 years, and mean height was 1.72±0.12 m, mean weight 72.87±8.54, mean BMI 27.54±6.15, size/volume of lesion was 28.6±3.9mls Duration of symptoms was 3.4±2.9 in months.

In table 2 Distribution of all qualitative variables was stated, where all study subjects were male and 162(42.9%) patients were illiterate. While 111(29.4%) patients have done primary or secondary and 105(27.8%) study subjects have done inter or higher education.

Distribution of findings stated in table 3 and 4 true positive values were 117, false positive values were 51, false negative values were 20 and true negative values were 190. Total positive findings on MR spectroscopy were 168(44.4%), total negative findings were 210(55.6%), Total positive findings on histopathology were 137(36.2%), and total negative findings were 241 (63.8%) The sensitivity, specificity, positive predictive value, negative predictive value and accuracy of MRS for diagnosis of Prostate cancer was 85.40%, 78.84%, 69.64%, 90.48% and 81.22%, respectively. Diagnostic accuracy was computed for stratified groups along with P-values at significance level <0.05.

Table 1: Descriptive statistics of quantitative variables (n=378)

Variables	N	Mean	Std. Diation
Age(yrs.)	378	64.33	9.65
Height(m)	378	1.72	0.12
Weight(kg)	378	72.87	8.54
BMI(kg/m ²)	378	27.54	6.15
Size/volume of lesion(mls)	378	28.6	3.9
Duration of Symptoms (months)	378	3.4	2.9

Table 2: Distribution of study variables (n=378)

Variables	Frequency	Percentages
Gender		
Male	378	100%
Educational status		
Illiterate	162	42.9%
Primary - secondary	111	29.4%
Inter or higher	105	27.8%

Table 3: Distribution of MR Spectroscopy and histopathology findings (n=378)

		Histopathology		Total	P-Value
		Negative	Positive		
MR Spectroscopy	Negative	190	20	210(55.6%)	0.0001
	Positive	51	117	168(44.4%)	
Total		241	137	378	
		63.8%	36.2%	100.0%	

Table 4: Diagnostic accuracy of MR Spectroscopy

Statistic	Formula	Value	95% CI
Sensitivity	$\frac{a}{a+B}$	85.40%	78.36% to 90.85%
Specificity	$\frac{d}{c + d}$	78.84 %	73.13% to 83.82%
Positive Likelihood Ratio	$\frac{Sensitivity}{1 - Specificity}$	4.04	3.13 to 5.20
Negative Likelihood Ratio	$\frac{1 - Sensitivity}{Specificity}$	0.19	0.12 to 0.28
Disease prevalence	$\frac{a + b}{a + b + c + d}$	36.24% (*)	31.39% to 41.31%
Positive Predictive Value	$\frac{da}{a + c}$	69.64% (*)	64.04% to 74.72%
Negative Predictive Value	$\frac{d}{b + d}$	90.48 % (*)	86.31% to 93.47%
Accuracy	$\frac{a + d}{a + b + c + d}$	81.22% (*)	76.91% to 85.03%

Discussion

Prostate cancer screening basics are based on the fact that patients diagnosed at screening tend to present a more favorable stage as compared with those clinically diagnosed, with a possible decrease in the rate of mortality due to prostate cancer.

Magnetic resonance imaging is commonly utilized for the tumor staging when a diagnosis is established by prostatic biopsy. If the disease is confined to the prostate, the capsule will appear intact, even if there is an extensive contact or regular bulging between the capsule and the tumor.

Additionally, MRI can also demonstrate the prostate anatomy particularly on spin echo sequences, identifying areas with alteration of signal intensity, which may represent focal lesions in the gland. Thus, this method provides an extensive evaluation of patients with prostate cancer and evaluating loco-regional lymph node involvement. On T1-weighted images, intraprostatic diseases are not demonstrated, the prostate appearance is homogeneous with iso-intense signal. The abnormality is observed on T2-weighted images, as the cancer presents itself as an area with signal hypo intensity at peripheral zone, which is normally hyper intense.

The development of endo-rectal coils have led to technical advances for better signal detection by MRI antennas. Endo-rectal coil presents > 97% accuracy in the localization of known prostate

lesions; however, the method performance is poor in the detection of focal small tumors of diameter less than 5mm.

Magnetic resonance spectroscopy of the prostate increases the diagnostic probability in cases of cancer, by adding metabolic data over the morphological information of the gland. The specificity of this method ranges from 70% to 91% and sensitivity from 68% to 95%.

Advantages of the utilizing this technique in the determination of prostate cancer include: accurate spectral localization of small morphologically abnormal region; precise correlation between the spectral mapping and the high-resolution magnetic resonance imaging; evaluation of the abnormal metabolism and its extent and three-dimensional coverage of the entire gland.

A variation is observed when the results of MRI and MRSI metabolic data are combined. Together, they result in 70-98% specificity and 56-94% sensitivity.

In 2004, Yuen et al observed that MRI data in association with those of MRSI, in the determination of suspicious areas with 100% sensitivity and 70.3% specificity.

In 2005, Prando et al [355] observed that MRI combined with MRSI presented high sensitivity (84% to 100%) and low specificity (44% to 71%) in the identification of target areas.

In the present study, alterations at MRI or at MRSI alone presented some how low specificity. Thus, the combined findings

should be considered when both peripheral zone hypo intense signal at MRI and metabolic inversions at MRSI are present (58% accuracy).

As regards sensitivity of MRI in association with MRSI in the detection of prostatic cancer (group A), the results of the present study are concurring with previous studies. However, with respect to specificity, the results were somehow below (47%) to those described in the literature, and agreeing only with Prando et al including in what refers to the group in study.

Therefore, information detected by MRSI with respect to the probable localization of prostate cancer may be useful in the programming of TRUS-guided biopsies, particularly in patients with PSA levels indicating cancer and those with previous negative biopsies. It can also improve the stratification of patients in clinical screening, monitoring and follow-up to a minimally aggressive treatment.

The implementation of study protocol underwent several phases. The first one occurred in 2004, with the installation of the Magnetom Sonata MRI in the Department of Imaging Diagnosis, where commercially available Siemens MRI and spectroscopy pulse sequences were modified and adjusted to the working conditions.

We wanted to assess accuracy of the non-contrast sequences including (DWI and MRS) in the MP-MRI in identifying and differentiating benign and malignant prostate lesions. There has been a similar study in Danish population by Thestrup KC et al., using bipartite MRI (T2 and DWI) they found that bipartite-MRI (BP-MRI) was as good as MP-MRI at detecting prostate carcinoma in their study of 204 patients. Their study revealed a sensitivity of 94–96% for the BP-MRI and 93%–100% for the MP-MRI.

In our study, the ADC values of the benign lesions were higher as compare to malignant lesion. Mean ADC value of the malignant and benign lesions were $0.884 \times 10^{-3} \text{ mm}^2/\text{s}$ and $1.19 \times 10^{-3} \text{ mm}^2/\text{s}$ respectively. Cho+ Cr/Ci ratios of the benign and malignant lesions in our study were 1.34 and 2.56 respectively. Li B et al., in their 56 patients found that DWI was more efficient than MRS in detection of malignant lesions. Combined ADC and MRS results were significantly better than MRS alone in differentiating malignant and benign lesions. The mean ADC value for malignant lesions was lower than that for benign lesions ($1.0603+0.1362 \times 10^{-3} \text{ mm}^2/\text{s}$ compared to $1.7053+0.3225 \times 10^{-3} \text{ mm}^2/\text{s}$). The mean Cho +Cr/Ci ratios for malignant and benign lesions were $2.7062+2.1746$ and $1.1197+0.8146$ respectively. These values were similar to the results in our study.

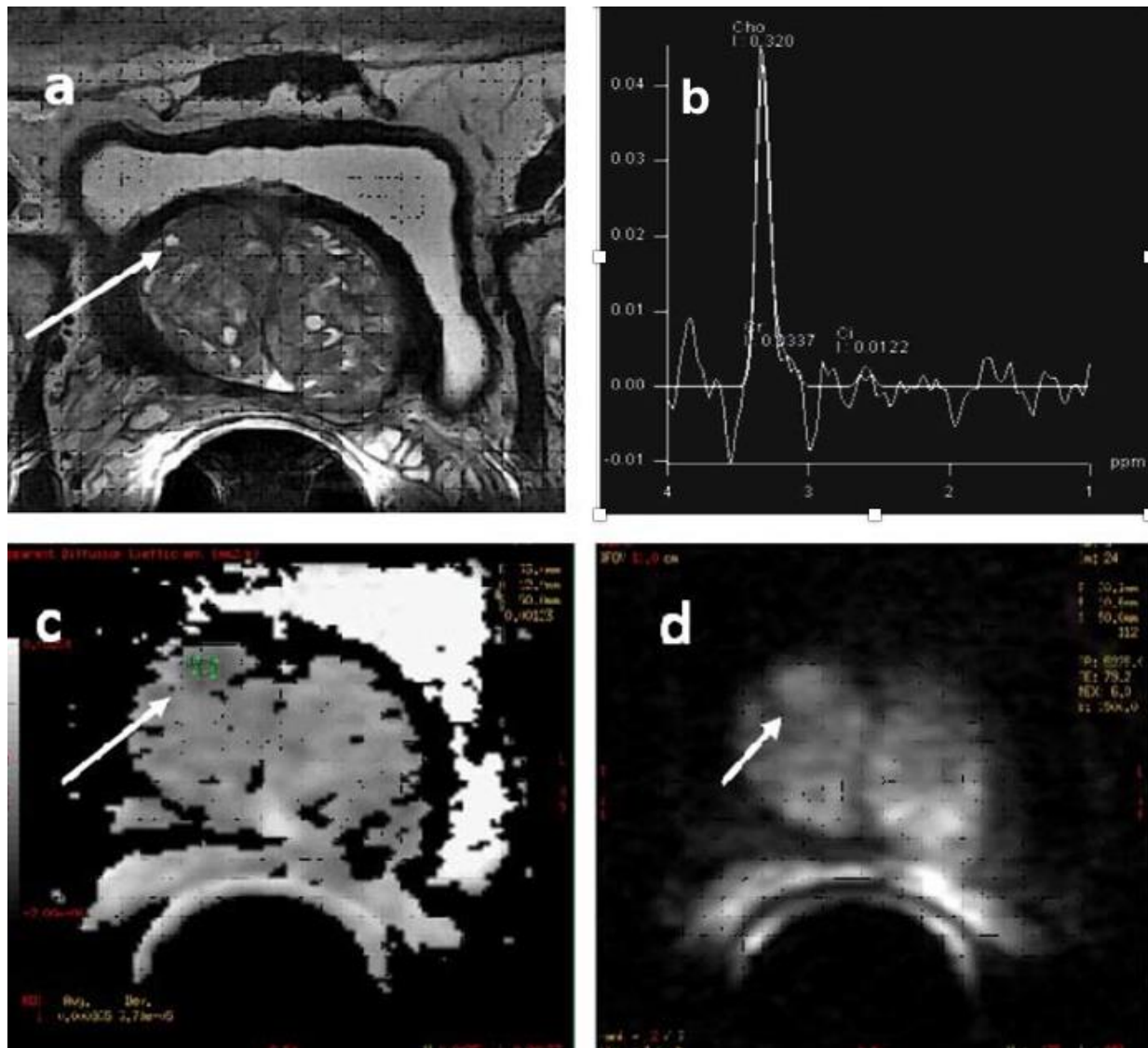


Figure 1: (a) Axial T2 sequences show benign enlargement of prostate gland with multiple scattered nodules. A well defined hypo intense lesion in the anterior aspect of the central mid gland on right side. b) The Cho /CR ratio is raised favouring neoplastic nodule. The nodule came out to be malignant on histopathology, suggesting importance of MRS.

In our study, sensitivity (89.5%) and specificity (85.7%) of the diagnosis of malignancy based on diffusion restriction were quite good. PPV and NPV were also very acceptable (94.4% and 75% respectively). Though, MRS had good sensitivity and PPV (84.2% and 76.2% respectively), specificity and NPV were poor (28.6% and 40% respectively). Imaging diagnosis based on combining T2, DWI and MRS had higher sensitivity and lower specificity than DWI alone (94.7% and 42.9 % respectively). PPV was lower at 81.8% and there was no change in the NPV (75%). Moreover, these values were the same as that of the results based on T2 signal alone. The diagnostic accuracy of DWI was 88.4 %. Hence, we would like to propose that DWI with ADC is the most important sequence in the MP-MRI and can be used in conjunction with T2 weighted images alone (avoiding MRS and DCE) to save time and cost. This proposal is similar to that made by Scialpi M et al.

Conclusion

MRS had higher specificity and sensitivity. Relative cost-effectiveness of alternative strategies seems to be sensitive to key parameters. Under certain conditions T2-MRI may be cost-effective compared with systematic TRUS. If MRS and DW-MRI can be shown to have high sensitivity for detecting high-risk cancer, while negating patients with no low-risk disease to undergo biopsy, their combined use can represent a cost-effective approach to diagnosis. However, due to the relative paucity of reliable data, further studies are required. In particular, further more prospective studies are required with suspected PC and elevated PSA levels but previously negative biopsy comparing the utility of the individual and combined components of a multi-parametric magnetic resonance (MR) approach (MRS, DCE-MRI and DW-MRI) with both a MR-guided/-directed biopsy session and an extended 14-core TRUS-guided biopsy scheme against a reference standard of histopathological assessment of biopsied tissue obtained via saturation biopsy, template biopsy or prostatectomy specimens.

The implantation and standardization of imaging through magnetic resonance spectroscopy allowed the acquisition of relevant data for the presumptive diagnosis of the presence of prostate cancer, combining the MR images with metabolic data from MRSI.

MRSI of the prostate can be a helpful diagnostic tool for detecting prostate cancer. More attention to detail and technical knowledge is needed for establishing and running a successful MRSI protocol. As it is an evolving functional tool in the assessment of prostate cancer, and this review should help readers understand the critical steps involved in performing a high-quality MRSI examination.

Ethical approval

The study was approved as per departmental protocol.

Funding

No finding.

Conflict of interest

None declared.

Acknowledgment

We would like to thank our patients without whom this study would not have had completed.

References

- [1] American Cancer Society. Cancer facts and figures 2016. Atlanta: American Cancer Society.
- [2] Carter HB, Sauvageot J, Walsh PC, Epstein JI. Prospective evaluation of men with stage T1c adenocarcinoma of the prostate. *The Journal of urology*. 1997 Jun 30;157(6):2206-9.
- [3] Thompson I, Leach RJ, Pollock BH, Naylor SL. Prostate cancer and prostate-specific antigen: the more we know, the less we understand.
- [4] Clements R. Contemporary ultrasound guided biopsy in the diagnosis of prostate cancer. *Imaging*. 2001 Apr;13(1):18-26.
- [5] Halpern EJ, Rosenberg M, Gomella LG. Prostate cancer: contrast-enhanced US for detection. *Radiology*. 2001 Apr;219(1):219-25.
- [6] Yu KK, Hricak H. Imaging prostate cancer. *Radiologic Clinics of North America*. 2000 Jan;38(1):59-85.
- [7] Punglia RS, D'amico AV, Catalona WJ, Roehl KA, Kuntz KM. Effect of verification bias on screening for prostate cancer by measurement of prostate-specific antigen. *New England Journal of Medicine*. 2003 Jul 24;349(4):335-42.
- [8] Scheidler J, Hricak H, Vigneron DB, Yu KK, Sokolov DL, Huang LR, Zaloudek CJ, Nelson SJ, Carroll PR, Kurhanewicz J. Prostate cancer: localization with three-dimensional proton MR spectroscopic imaging—clinicopathologic study. *Radiology*. 1999 Nov;213(2):473-80.
- [9] Qayyum A, Coakley FV, Lu Y, Olpin JD, Wu L, Yeh BM, Carroll PR, Kurhanewicz J. Organ-confined prostate cancer: effect of prior transrectal biopsy on endorectal MRI and MR spectroscopic imaging. *American Journal of Roentgenology*. 2004 Oct;183(4):1079-83.
- [10] Yu KK, Scheidler J, Hricak H, Vigneron DB, Zaloudek CJ, Males RG, Nelson SJ, Carroll PR, Kurhanewicz J. Prostate cancer: prediction of extracapsular extension with endorectal MR imaging and three-dimensional proton MR spectroscopic imaging. *Radiology*. 1999 Nov;213(2):481-8.
- [11] Kurhanewicz J, Vigneron DB, Males RG, Swanson MG, Kyle KY, Hricak H. The prostate: MR imaging and spectroscopy: present and future. *Radiologic Clinics of North America*. 2000 Jan 1;38(1):115-38.
- [12] Westphalen AC, Coakley FV, Qayyum A, Swanson M, Simko JP, Lu Y, Zhao S, Carroll PR, Yeh BM, Kurhanewicz J. Peripheral zone prostate cancer: accuracy of different interpretative approaches with MR and MR spectroscopic imaging. *Radiology*. 2008 Jan;246(1):177-84.
- [13] De la Rosette JJ, Wink MH, Mamoulakis C, Wondergem N, ten Kate FJ, Zvinderman K, et al. Optimizing prostate cancer detection: 8 versus 12-core biopsy protocol. *J Urol*. 2009 Oct;182(4):1329-36.
- [14] Caverly TJ, Hayward RA, Reamer E, Zikmund-Fisher BJ, Connochie D, Heisler M, Fagerlin A. Presentation of benefits and harms in US cancer screening and

- prevention guidelines: systematic review. Journal of the National Cancer Institute. 2016 Feb 24;108(6):djv436.
- [15] Abraham NE, Mendhiratta N, Taneja SS. Patterns of repeat prostate biopsy in contemporary clinical practice. The Journal of urology. 2015 Apr 30;193(4):1178-84.
- [16] Hricak H, White S, Vigneron D, Kurhanewicz J, Kosco A, Levin D, Weiss J, Narayan P, Carroll PR. Carcinoma of the prostate gland: MR imaging with pelvic phased-array coils versus integrated endorectal--pelvic phased-array coils. Radiology. 1994 Dec;193(3):7039.
- [17] Turkbey B, Brown AM, Sankineni S, Wood BJ, Pinto PA, Choyke PL. Multiparametric prostate magnetic resonance imaging in the evaluation of prostate cancer. CA: a cancer journal for clinicians. 2016 Jul 1;66(4):326-36.
- [18] White S, Hricak H, Forstner R, Kurhanewicz J, Vigneron DB, Zaloudek CJ, Weiss JM, Narayan P, Carroll PR. Prostate cancer: effect of postbiopsyhemorrhage on interpretation of MR images. Radiology. 1995 May;195(2):385-90.
- [19] Quint LE, Van Erp JS, Bland PH, Mandell SH, Del Buono EA, Grossman HB, Glazer GM, Gikas PW. Carcinoma of the prostate: MR images obtained with body coils do not accurately reflect tumor volume. AJR.American journal of roentgenology. 1991 Mar;156(3):511-6.
- [20] Casciani E, Gualdi GF. Prostate cancer: value of magnetic resonance spectroscopy 3D chemical shift imaging. Abdominal imaging. 2006 Aug 1;31(4):490-9.
- [21] Kurhanewicz J, Vigneron DB, Hricak H, Narayan P, Carroll P, Nelson SJ. Three-dimensional H-1 MR spectroscopic imaging of the in situ human prostate with high (0.24-0.7-cm³) spatial resolution.Radiology. 1996 Mar;198(3):795-805.
- [22] Yacoe ME, Sommer G, Peehl D. In vitro proton spectroscopy of normal and abnormal prostate.Magnetic resonance in medicine. 1991 Jun 1;19(2):429-38.
- [23] Cornel EB, Heerschap A, Smits GA, OosterhofGO, Debruyne FM, Schalken JA. Magnetic resonance spectroscopy detects metabolic differences between seven Dunning rat prostate tumorsublines with different biological behavior. The Prostate. 1994 Jul 1;25(1):19-28.
- [24] Cornel EB, Smits GA, Oosterhof GO, Karthaus HF, Debruyne FM, Schalken JA, Heerschap A. Characterization of human prostate cancer, benign prostatic hyperplasia and normal prostate by in vitro 1H and 31P magnetic resonance spectroscopy. The Journal of urology. 1993 Dec 1;150(6):2019-24.



Open Access This article is licensed under a Creative Commons Attribution 4.0 International License, which permits use, sharing, adaptation, distribution and reproduction in any medium or format, as long as you give appropriate credit to the original author(s) and the source, provide a link to the Creative Commons license, and indicate if changes were made. The images or other third party material in this article are included in the article's Creative Commons license, unless indicated otherwise in a credit line to the material. If material is not included in the article's Creative Commons license and your intended use is not permitted by statutory regulation or exceeds the permitted use, you will need to obtain permission directly from the copyright holder. To view a copy of this license, visit <https://creativecommons.org/licenses/by/4.0/>.

© The Author(s) 2021