



Robotic-Assisted Mini-Gastric By-Pass for Diabetes in Children: A First Case Report and Review of the Literature

Murat Cag ^{*1}, Yeşim Ozdemir ², Mahmut Civilibal ³, Askin Ali Korkmaz ⁴, Mesrur Selcuk Silay ⁵

¹Department of Bariatric/Metabolic and Robotic Surgery, Memorial Bahcelievler Hospital, Istanbul, Turkey

²Uskudar University Medical Faculty Medical Genetics Department Istanbul Turkey

³Department of Pediatrics, Memorial Bahcelievler Hospital, Istanbul, Turkey

⁴Department of Cardiovascular Surgery, Memorial Bahcelievler Hospital, Istanbul, Turkey

⁵Division of Pediatric Urology and Robotic Surgery, Department Of Urology, Biruni University, Istanbul, Turkey

*Corresponding Author: Murat Cag; cagmurat@hotmail.com

Received 12 February 2022;

Accepted 28 February 2022;

Published 01 March 2022

Abstract

Objectives: Obesity is one of the most common diseases of children across the globe with repercussion because of comorbidities like diabetes for the future followed by premature deaths. We aimed to report the world first case of robotic-assisted mini-gastric by-pass in 15 years old boy to treat diabetes and obesity. Surgical technique and review of the literature has been presented. **Patient and Methods:** Fifteen years old male with Body Mass Index (BMI) 58.6 at 125 percentile, and the patient was followed by dietetic counseling and with increasing metformin dosage treatment because of insulin resistance in his country. After 3 years of follow up the patient's treatment was not successful and therefore the family addressed to our obesity council. Our genetic consultant assured the boy doesn't have MC4R mutation. Other endocrinologic comorbidities was evaluated by a pediatrician specialist on obesity and referred to a pediatric endocrinologist. The Type 2 diabetes was diagnosed. Robotic assisted mini-gastric by-pass was planned. Under general anesthesia five instrument ports were placed. Then the robot was docked. The stomach was divided with stapler at the junction of the body and antrum, at a location where the jejunal loop can be brought up comfortably. The jejunal loop is brought up antecolic, and the stapler is used to anastomose the stomach and the small bowel at this point. The distal end of the gastric tube is anastomosed to the side of the small bowel. Methylene blue was given to ensure there was no leakage at the anastomosis and the stapling sites. The antidiabetics were stopped by the operation. The patient was followed for a month with a normalization of blood glucose levels and without medical nor surgical complication. **Results:** Operative time was 105 minutes. No intraoperative complication was encountered. The patient started walking 6 hours postoperatively. The first postoperative day glucose levels were within the normal limits. Oral contrast CT demonstrated neither leakage nor obstruction on the first day. Patient started oral intake within 24 hours and was discharged in 3 days without any postoperative complication. After 1 month of follow up we didn't saw any perturbation on blood glucose level. **Conclusion:** Robotic-assisted mini gastric by-pass is feasible in diabetic children. The main postoperative advantages are early recovery, less pain and better cosmesis with a easily revisable and reversible operation.

Keywords: Diabetes; Obesity; Robotics; Mini Gastric Bypass; Children; Pediatric

Introduction

The global epidemic of child and adolescent obesity affects all world regions, including countries where undernutrition remains common. In 2016, 155 million children were affected by stunting and 52 million children were wasted while 41 million children were overweight. However, being overweight or obese also has immediate physical and mental health implications for a child or adolescent, and both are major risk factors for cardiovascular disease, diabetes and premature death in adults ^[1].

Minimally invasive surgery, including robotic and laparoscopic surgery, has become the standard of care for treatment of most intra-abdominal pediatric conditions. After the laparoscopic era due to robotic use, the surgery is done with precision, miniaturization, smaller incisions; decreased blood loss, less pain, and quicker healing time. With robotic surgery the articulation beyond normal manipulation and three-dimensional magnification help to result in improved ergonomics. These techniques provide a reduced duration of hospital stays, blood loss, transfusions, and use of pain medication ^[2].

Robotic surgery is type of surgical procedures that are done using computer assisted systems. Robotically-assisted surgery was developed to try to overcome the limitations of pre-existing minimally-invasive surgical procedures and to enhance the capabilities of surgeons performing open surgery. The surgical robot can continuously be used by rotating surgery teams [3,4].

There is a steep learning curve for surgeons who adopt the use of the robotic (computer assisted) system and that there's a lack of studies that indicate long-term results are superior to results following traditional laparoscopic surgery [5,6].

The Swedish obese subjects study showed us mortality reduction, type 2 diabetes remission and fewer cardiovascular events after bariatric procedures [7].

Bariatric procedures can be grouped in three main categories: decreasing the absorption, restricting, and mixed, the latter understood to work by altering gut hormone levels responsible for hunger and satiety [8].

Different bariatric procedures may help patients lose more weight, while others have increased chances of adverse events [9].

A surgical technique known as Single-Anastomosis Gastric Bypass (SAGB) or Mini-Gastric Bypass (MGB) has been developed; its frequency of performance has increased considerably in the current decade. The main feature of the operation is a gastric pouch with a gastroenteric anastomosis in the ante-colic isoperistaltic loop [11].

This procedure proposes a simplification of roux-en-y bypass by performing a single anastomosis, with a significant reduction of technical complexity, shorter operative time and a potential reduction in morbidity and mortality. Several studies have demonstrated the benefits provided by this procedure than those observed after the roux-en-y gastric bypass [12-13].

Materials and Methods

Fifteen years old, male, tanner 4, BMI 58.6 at 125 percentile, was followed in his country by dietetic counseling and with increasing metformin dosage treatment. After 3 years of follow up, without success we took in charge the patient; reperformed several consultations including genetic researches and discussed in our obesity council following the guidelines [14]. The genetic result showed us no MC4R mutation [15].

The patient was evaluated by a pediatric specialist and referred to a pediatric endocrinologist. The Type 2 diabetes was diagnosed because of high successive HbA1c (6.7 %, 6.1 %, 7.1%) and insulin levels, and very elevated blood sugars.

The decision was to perform a technique: effective, revisable, safe. We choose for this child after revisiting the literature, a relatively new technique not described to treat diabetes type 2 and morbid obesity at same time: robotic assisted Mini-Gastric Bypass. The follow up period was limited to his stay in our country to 10 days and then in its country for 30 days.

This child patient's DNA was extracted from peripheral lymphocytes using standard protocols and found no mutation or variant in MC4R gene were performed via Sanger sequencing.

The XI Da Vinci Surgical System version (Intuitive Surgical, Sunnyvale, CA, USA) is also useful in the pediatric age, in the limited working space typical in small children [16].

For da Vinci Xi® system:

- P1: prograsp forceps
- P2: camera arm
- P3: prograsp forceps
- P4: ligasure system as energy and sealing device

We use trisapler 45 and 60 mm from assistant port to perform the anastomosis

Each operation is stocked on our harddrive

Under general anesthesia five ports are placed. We don't use "paddle" retractor to retract the liver. The stapler divides the stomach at the junction of the body and antrum, at a location where the jejunal loop can be brought up comfortably. An ewald tube, roughly the diameter of the esophagus, is passed by the anesthetist and held against the lesser curvature. The division of the stomach against the tube is completed, with 6 lines of staples that seal the gastric pouch. The division of the stomach is parallel to the lesser curvature and up to the angle of His. No short gastric vessels are divided. The bypassed stomach lies on the patients left, and the narrow lesser-curvature gastric pouch lies on the patient's midline to the right of the bypassed stomach. A point is selected on the small bowel about 200 cm distal to the ligament of Treitz. The jejunal loop is brought up antecolic, and the stapler is used to anastomose the stomach and the small bowel at this point. The inside of the anastomosis is inspected for bleeding before final closure. The second stapler closes the anastomosis. The greater omentum is tucked between the gastric tube and the bypassed stomach. The permeability and leakage tests with methylene blue are also performed.

Results and Discussion

The boy stayed in Intensive Care Unit during the first night where he extubated 2 hour after the 105 minutes of operation and walked 6 hour postoperatively. The first postoperative day the blood glucose results are already normal in the blood glucose follow up (Table 2). This day we made a control CT scanner with oral contrast medium showing any leakage, nor obstruction. We permitted oral liquid intake. He left our institution third day after the operation with the use of enoxaparine sodium for 6 weeks at a adequate dose without any anti diabetic medication. After a month of followup blood sugar levels were at normal range and stable (Figure 1)

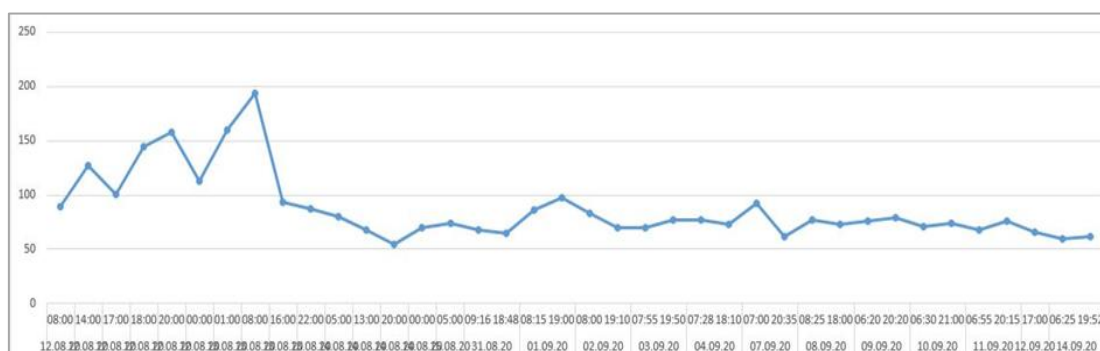


Figure 1: Blood glucose follow ups for a month without medication (Normal blood levels 74-100 mg /dl)

The literature research on Pubmed returned with any published paper about robotic assisted neither pediatric nor adolescent diabetes treatment at the very date of 16/09/2020 (Table 1)

Table 1: Review of the literature including minimally invasive gastric by-pass in children The literature research on pubmed returned with any published paper about robotic assisted pediatric nor adolescent diabetes treatment at the very date of 16/01/2022

Team	Aim Obesity0 Diabetes1	Robotic Assisted	Laparoscopic	Mgb
F. Niccolo [24]	0	0	1	0
M.Arafat [25]	0	0	1	0
W. El Hag [26]	0	0	1	0
T.Olbers [27]	0	0	1	0
Lin Qi [28]	0	0	1	0
E.J. Nehus [29]	0	0	1	0
T.H Inge [30]	0	0	1	0
G.F.Paulus [31]	0	0	1	0
R.Vilalonga [32]	0	0	1	0
J.L.Zitsman [33]	0	0	1	0
Y. Cozacov [34]	0	0	1	0
S. Nijhavan [35]	0	0	1	0
S. Bondada [36]	0	0	1	0
A. Osorio [37]	0	0	1	0
G.R.Silberhumer [38]	0	0	1	0
K.Widhalm [39]	0	0	1	0
De La Cruz-Munoz [40]	0	0	1	0
F.S. Papadia [41]	0	0	1	0
H.J. Sugerma [42]	0	0	1	0
Cag M	1	1	0	1

Discussion

Robotic systems require a dedicated team with special training. Each member must be experienced in robotic assisted surgery and communication between each of these individuals is vital for successful outcomes. It is generally recommended to have a dedicated team to work through the learning curve and if possible all robotic cases.

The reverse trendelenburg position is used during our surgery: This position provides the surgical team with adequate visibility of the surgical site by shifting the abdominal contents toward the pelvis.

The goals of positioning are to maintain circulation, in general protect the patient from injury; provide adequate exposure of the operative site; maintain a functional airway; and provide the anesthesiologist adequate access to IV lines and monitoring equipment [17].

The main limitation of robotic assisted laparoscopic mini gastric by-pass is the economic cost and the lack of availability at many institutions. The second limitation of our study was the single case report and without having a case series. However the main goal of our study was to report the feasibility of this novel approach in pediatric patients to treat diabetes as good as adults.

Bariatric surgery in youth is among the controversial topics related to surgery in children. Surgery on children requires consideration, which are not common in adult surgery. Children and adolescents are still developing physically and mentally making it difficult for them to make informed decisions and give consent for surgical treatments [18]. To make a good choice of treatment some algorithms are proposed that we preferred for our patient one of them : 1Body Mass Index bigger or equal than 95th percentile 2 high fasting blood glucose with high Hb A1C and the other endocrinologic research [14].

The MGB is safe, results in major weight loss, has a short operating-time, and has a short hospital stay. The MGB appears to meet many of the criteria of an "ideal" weight loss operation [10-11].

Wang et al’s study compared the effectiveness between two gastric bypass procedures. It concluded that SAGB had a better weight reduction effect and recommended larger sample size studies to compare outcomes. In addition, SAGB has been shown to be effective alternative procedure of choice in super and morbid obese patients [19-21].

The diabetes is resolved in bariatric and metabolic surgery groups. Even though weight loss-independent effects are important for short-term diabetes remission, the Swedish Obese Subjects (SOS) Study results suggest that degree of weight loss is more important for long-term reductions in fasting insulin and glucose than choice of bariatric surgery procedure [22].

By the times the patients more often were offered SAGB as a single intervention. This might explain the observed significant finding of the success of higher initial weight among the oagb cohort [23].

Conclusions

Based on the international literature and the current clinical research state, there is a clear evidence of feasibility and studies prove the relevance of robotic (computer assisted) approach. The ethic of the choice is valuable and respectable: if robotic surgery GUARANTEES a better functional outcome compared to open surgery, and if robotic surgery makes advanced minimally invasive surgery easy, then it’s morally mandatory to treat pediatric patients according to their health-care “specificity” and with the best available technologies, just like adult patients [43].

At this point of view this young patient was the winner of our decision to end his type 2 diabetes by surgical choice after 3 years dietetic and medical treatment and followup. Our choice of robotic assisted minigastric bypass could be justified by the precision of the robot and revisibility, easily convertibility in the

need of the Mini-Gastric Bypass for his long life ahead with only one anastomosis without changing abdominal anatomy against multiple anastomosis.

Ethics approval and consent to participate

Not applicable

Data Availability

Not applicable

Conflicts of Interest

The authors declare (that there is no conflict of interest regarding the publication of this paper

Funding Statement

No funding was received to assist with the preparation of this manuscript.

Authors' contributions

MC and YO were the major contributors in literature search writing the manuscript, and spelling and grammar check.

YO conducting the DNA analysis and NGS

MaC, Referred the patient

MuC is the surgeon operating the patient

All authors read and approved the final manuscript.

References

- [1] Report of the Commission on Ending Childhood Obesity. Geneva: World Health Organization;2016(http://apps.who.int/iris/bitstream/10665/204176/1/9789241510066_eng.pdf?ua=1).
- [2] Ep Estey. Robotic prostatectomy: the new standard of care or a marketing success?. Canadian urological association journal. 3 (6): 488-90, 2009. Doi:10.5489/cuaj.1182.
- [3] D. Gerhardus. Robot-assisted surgery: the future is here. Journal of healthcare management. 48 (4): 242-51. 2003. Doi:10.1097/00115514-200307000-00008.
- [4] L.R. Kavoussi, R.G. Moore, J.B. Adams, A.W. Partin. Comparison of robotic versus human laparoscopic camera control. The journal of urology. 154 (6): 2134-6, 1995. Doi:10.1016/s0022-5347(01)66715-6
- [5] G.I. Barbash, S.A. Glied. Robotic surgery has been criticized for its expense b "new technology and health care costs--the case of robot-assisted surgery. The new england journal of medicine. 363 (8): 701-4, 2010. Doi:10.1056/nejmp1006602.
- [6] J.B. Mahida, J.N. Cooper, D. Herz et al.. Utilization and costs associated with robotic surgery in children. J surg res;199(1):169-76, 2015
- [7] A.P. Courcoulas, S.Z. Yanovski, D. Bonds et al. Long-term outcomes of bariatric surgery: a national institutes of health symposium". Jama surgery. 149 (12): 1323-9. 2014 Doi:10.1001/jamasurg.2014.2440.
- [8] T.L. Abell, A. Minocha. Gastrointestinal complications of bariatric surgery: diagnosis and therapy. The american

- journal of the medical sciences. 331 (4): 214-8, 2006. Doi:10.1097/00000441-200604000-00008.
- [9] D. Arterburn, R. Wellman, A. Emiliano et al. Comparative effectiveness and safety of bariatric procedures for weight loss: a pcornt cohort study". Annals of internal medicine. 169 (11): 741-750, 2018. Doi:10.7326/m17-2786
- [10] R. Rutledge. The Mini-Gastric Bypass experience with the first 1,274 cases. Obes surg.;11(3):276-280, 2001.
- [11] R. Rutledge, TR. Walsh. Continued excellent results with the Mini-Gastric Bypass six-year study in 2,410 patients. Obes.surg.15(9):1304-1308, 2005.
- [12] W.J. Lee, K.H. Ser, Y.C. Lee, J.J. Ttsou, S.C. Chen, J.C. Chen. Laparoscopic roux-en-y vs. Mini-Gastric Bypass for the treatment of morbid obesity: a 10-year experience Obes surg. 22(12):1827-34, 2012.
- [13] M. Victorzon., Scand j surg. 104(1):48-53, 2015. Single-Anastomosis Gastric Bypass: better, faster, and safer.
- [14] SE Cuda, M. Censani. Pediatric Obesity Algorithm: A Practical Approach to Obesity Diagnosis and Management. Front. Pediatr. 6:43, 2018..doi: 10.3389/fped.2018.00431
- [15] M. Valette, F. Bellisle, C. Carette et. al. Behaviour in obese patients with melanocortin-4 receptor mutations: a literature review International Journal of Obesity volume 37, pages1027-1035, 2013
- [16] T.P. Cundy, H.J. Marcus, A. Hughes-hallett, S. Khurana, A. Darzi. Robotic surgery in children: adopt now, await, or dismiss? Pediatr surg int. 31:1119-25, 2015.
- [17] C. Hortman, S. Chung. Positioning considerations in robotic surgery. Aorn j.;102:434-9, 2015
- [18] M.A. Orvieto, M. Large, M.S. Gundeti. Robotic paediatric urology. Bju int. 110(1):2-13, 2012.
- [19] F.G. Wang, W.M. Yan, M. Yan, M.M. Song. Outcomes of mini vs roux-en-y gastric bypass: a meta-analysis and systematic review. Int. J. Surg.;56:7-14, 2018
- [20] A. Solouki, M. Kermansaravi, A. Davarpanah jazi. One-anastomosis gastric bypass as an alternative procedure of choice in morbidly obese patients. J. Res. Med. Sci.;23:84, 2018
- [21] V. Singla, S. Aggarwal, B. Singh, G. Tharun, V. Katiyar, A. Bhambri. Outcomes in super obese patients undergoing one anastomosis gastric bypass or laparoscopic sleeve gastrectomy. Obes. Surg. 29(4):1242-1247, 2019.
- [22] K. Sjolholm. Weight change-adjusted effects of gastric bypass surgery on glucose metabolism: 2- and 10-year results from the swedish obese subjects (sos) study diabetes care 39:625-631, 2016. | doi: 10.2337/dc15-1407
- [23] A. Mustafa, N.N.H. Rizkallah, N. Samuel, S. Balupuri. Laparoscopic roux-en-y gastric bypass versus one anastomosis (loop) gastric bypass for obesity: a prospective comparative study of weight loss and complications. Ann med surg (lond). 18;55:143-147, 2020. doi: 10.1016/j.amsu.2020.04.040
- [24] F. Niccolò, G. Francesca, C. Rosa, G. Francesco, F. Francesco. Teenagers with Obesity: Long-Term Results of Laparoscopic Adjustable Gastric Banding. Journal of Pediatric Surgery. 55(4):732-736, 2019. doi:10.1016/j.jpedsurg.2019.08.011
- [25] M. Arafat, A. Norain, S. Burjonrappa. Characterizing Bariatric Surgery Utilization and Complication Rates in

- the Adolescent Population *J Pediatr Surg*;54(2):288-292, 2019.
- [26] W. Elhag W.E. Ansari S. Abdulrazzaq Ali Abdullah, M. Elsherif, I. Elgenaie Evolution of 29 Anthropometric, Nutritional, and Cardiometabolic Parameters among Morbidly Obese Adolescents 2 Years Post Sleeve Gastrectomy. *Obes Surg*. 28(2): 474-482, 2018.
- [27] T. Olbers, A.J. Beamish, E. Gronowitz. Laparoscopic Roux-en-Y gastric bypass in adolescents with severe obesity: a prospective five year Swedish nationwide study (AMOS). *Lancet Diabetes Endocrinol*. 5(3): 174-183, 2017.
- [28] L. Qi, Y. Guo, C.Q. Liu, Z.P. Huang, Y. Sheng, D.J. Zou, Effects of bariatric surgery on glycemic and lipid metabolism, surgical complication and quality of life in adolescents with obesity: a systematic review and meta-analysis. *Surgery for Obesity and Related Diseases*, 13(12), 2037-2055. 2017 doi:10.1016/j.soard.2017.09.516
- [29] E.J. Nehus, J.C. Khoury, T.H. Inge et al. Kidney outcomes three years after bariatric surgery in severely obese adolescents. *Kidney Int*. 91(2):451-8, 2017.
- [30] Inge TH, Courcoulas AP, Jenkins TM, et al. Weight loss and health status 3 years after bariatric surgery in adolescents. *N Engl J Med*. 2016;374(2):113-23.
- [31] G.F. Paulus, G. Konings, N.D. Bouvy et al. Long-term follow-up is essential to assess outcome of gastric banding in morbidly obese adolescents: a retrospective analysis. *Obes Facts*. 9(5):344- 52, 2016.
- [32] R. Vilallonga, J. Himpens, S. van de Vrande. Long-term (7 years) follow-up of Roux-en-Y gastric bypass on obese adolescent patients. *Obes Facts*.; 9(2):91-100,2016. doi: 10.1159/000442758.
- [33] J.L. Zitsman, M.F. DiGiorgi, I. Fennoy et al. Adolescent laparoscopic adjustable gastric banding (LAGB): prospective results in 137 patients followed for 3 years. *Surg Obes Relat Dis*.;11(1):101-9,2015.
- [34] Y. Cozacov Y, Roy M, Moon S, et al. Mid-term results of laparoscopic sleeve gastrectomy and Roux-en-Y gastric bypass in adolescent patients. *Obes Surg*. 2014;24(5):747-52.
- [35] S. Nijhawan, T. Martinez, A.C. Wittgrove. Laparoscopic gastric bypass for the adolescent patient: long-term results. *Obes Surg*.;22(9):1445-9, 2012.
- [36] S. Bondada, H.C Jen, D. DeUgarte. Outcomes of bariatric surgery in adolescents. *Current Opinion in Pediatrics*, 23(5), 552-556, 2011.
- [37] A. Osorio, J. Moreira-Pinto, J. Pereira et al. 9 Years after the first laparoscopic adjusted gastric banding (LAGB) in adolescents: the Portuguese experience. *Eur J Pediatr Surg*.;21(5):331-4,2011.
- [38] G.R. Silberhumer, K. Miller, A. Pump et al. Long-term results after laparoscopic adjustable gastric banding in adolescent patients: follow-up of the Austrian experience. *Surg Endosc*.;25(9): 2993-9,2011.
- [39] K. Widhalm, M.Fritsch, H. Widhalm et al. Bariatric surgery in morbidly obese adolescents: long-term follow-up. *Int J Pediatr Obes*.;6(Suppl 1):65-9, 2011.
- [40] N. de la Cruz-Munoz, S.E. Messiah, J.C. Cabrera et al. Four-year weight outcomes of laparoscopic gastric bypass surgery and adjustable gastric banding among multiethnic adolescents. *Surg Obes Relat Dis*.;6(5):542-7,2010.
- [41] F.S. Papadia, G.F. Adami, G.M. Marinari et al. Bariatric surgery in adolescents: a long-term follow-up study. *Surg Obes Relat Dis*.;3(4):465-8,2007.
- [42] H.J. Sugerman, E.L. Sugerman, E.J. DeMaria, et al. Bariatric surgery for severely obese adolescents. *J Gastrointest Surg*.;7(1):102-8,2003.
- [43] G. Mattioli, P. Petralia Book. ISBN: 978-3-319-41863-6 Pediatric robotic surgery, Pediatric robotic surgery: technical and management aspects doi 10.1007/978-3-319-41863-6_2



Open Access This article is licensed under a Creative Commons Attribution 4.0 International License, which permits use, sharing, adaptation, distribution and reproduction in any medium or format, as long as you give appropriate credit to the original author(s) and the source, provide a link to the Creative Commons license, and indicate if changes were made. The images or other third party material in this article are included in the article's Creative Commons license, unless indicated otherwise in a credit line to the material. If material is not included in the article's Creative Commons license and your intended use is not permitted by statutory regulation or exceeds the permitted use, you will need to obtain permission directly from the copyright holder. To view a copy of this license, visit <https://creativecommons.org/licenses/by/4.0/>.

© The Author(s) 2021