



# Extensor Pollicis Brevis Transfer to Extensor Pollicis Longus for Delay Spontaneous Ruptures: A Case Series and Functional Outcomes at One Year Follow Up

Kastanis G <sup>\*1,2</sup>, Kapsetakis P <sup>2</sup>, Chaniotakis C <sup>2</sup>, Stavrakakis I <sup>2</sup>, Pantouvaki A <sup>1,3</sup>

<sup>1</sup>Reconstructive Hand Surgery Unit, General Hospital of Heraklion -Venizeleio, Crete, Greece

<sup>2</sup>Department of Orthopaedic, General Hospital of Heraklion -Venizeleio, Crete, Greece

<sup>3</sup>Department of Physiotherapy, General Hospital of Heraklion -Venizeleio, Crete, Greece

\*Corresponding Author: Grigorios Kastanis; [kastanisg@gmail.com](mailto:kastanisg@gmail.com)

Received 02 February 2022;

Accepted 26 February 2022;

Published 02 March 2022

## Abstract

**Introduction:** When Extensor Pollicis Longus (EPL) spontaneously ruptures, two major risk factors are present: rheumatoid arthritis and distal radius fracture. The gold standard treatment is the transfer of Extensor Indicis Proprius (EIP) to restore the functionality of the thumb. Utilization of Extensor Pollicis Brevis (EPB) was used initially, in patients with rheumatoid arthritis. The aim of this study is to ascertain if the EPB transfer technique is the most competent and efficient surgical method for rupture of EPL, analyzing functional outcomes, complications and final patient's satisfaction. **Material & Methods:** Eighteen patients (14 female and 4 men) with an average age of 43 years old were introduced in this study. All cases reported no history of trauma. From the derived clinical history, 8 cases suffered from rheumatoid arthritis, 4 patients reported initial corticosteroid injection in radial side of wrist, one case was revised surgery and in rest cases the etiology was unknown. Radiographic investigation was normal in all cases, while magnetic resonance studies detect EPL ruptures. All patients were operated in a mean time of 3, 4 weeks (ranging from 2 to 6 weeks) after the diagnosis and in all cases the tendon applied was the EPB. After surgery all patients followed the same rehabilitation program. **Results:** The mean follow-up was 20,5 months (range from 15 months to 36 months). None of patients missed the last re-examination. Results were evaluated according to complications, range of motion of the thumb (elevation deficit, opposition distance, difference flexion-extension deficit), Quick Dash Score, EQ-5D-5L, and satisfaction of the patients. No intra-or extra-operative complications or re-ruptures were noted. At the final follow up the mean range of elevation deficit was 0,7 (from 0,5 to 1,5), opposition distance was 0,8 (range from 0,5 to 1,8) and difference flexion-extension deficit was 1,6° (from 0° to 5°). The Quick Dash score was 1.38 (varied from 0.0- 6.8) and the EQ-5D-5L was 92. Finally, the majority of patients appeared to be very satisfied (66,7%) or satisfied (27,8%). **Conclusion:** Extensor Pollicis Longus tendon spontaneously ruptures due to specific factors. Restore of thumb functionality is achieved only with tendon transfer technique and the use of Extensor Indicis Proprius tendon has been described as the gold standard. Extensor Pollicis Brevis tendon transfer is an alternative technique with significant advantages which preserves good functionality of the thumb and excellent patient satisfaction.

**Keywords:** *Extensor Pollicis Longus, ruptures, tendon transfer, Extensor Pollicis Brevis*

## Introduction

Extensor tendons of the hand ruptures is an infrequent injury, which in majority of cases appears spontaneously without trauma and with the Extensor Pollicis Longus (EPL) rupture to be the most clinical entity <sup>[1]</sup>. The most common causes mentioned in literature for the spontaneous rupture of the EPL are: rheumatoid arthritis, synovitis, tenosynovitis, secondary to non-displaced fracture of distal radius (incidence 0,2-5%), repetitive use of the tendon and

the use of local steroid injection <sup>[3-6]</sup>. There are also reports in literature, describing EPL rupture after Listers tubercle fractures, after scaphoid nonunion advance collapse, or after lunette dislocation <sup>[18,19,10]</sup>.

Extensor Pollicis Longus tendon presents a multiplicate anatomical route in hand and the main function is the extension of the terminal phalanx of the thumb and adduction of the first metacarpal. It originates from posterior surface of the middle third of the ulna and membrane interosseous passing through the third

dorsal compartment of extensors, ulnar to Lister’s tubercle, turning to thumb and finally inserted on the base of the distal phalanx of the thumb [7]. While the EPL presents arterial supplies before (anterior interosseous artery) and after (radial artery) synovial sheath, into the third compartment at Lister’s tubercle the tendon has poor vascularity or is avascular [3,8]. This vascular distribution of the EPL may explain why in the majority of cases the rupture appeared at the point of reflection on Lister’s tubercle [9].

The treatment of EPL injuries is only surgical and comprised of end-to-end suture, graft or tendon transfer. In acute cases the end-to-end sutures is the best option, while in cases of delay repair, when EPL tendon is retracted, or in rheumatoid arthritis, the tendon transfer is the only solution to restore the extension function of the thumb [10]. From the very first report of extensor carpi radialis transfer for EPL ruptures, at 1876 until today, many publications exist in literature referring to various techniques for surgical treatment of this lesion including EPB, Abductor Pollicis Longus(APL), Palmaris Longus(PL), Extensor Proprius(EP) of the small finger, extensor digit minimi(EDM),but the extensor indicis proprius(EIP) has been recommended by many researchers as the gold standard technique for delay EPL ruptures [11-17].

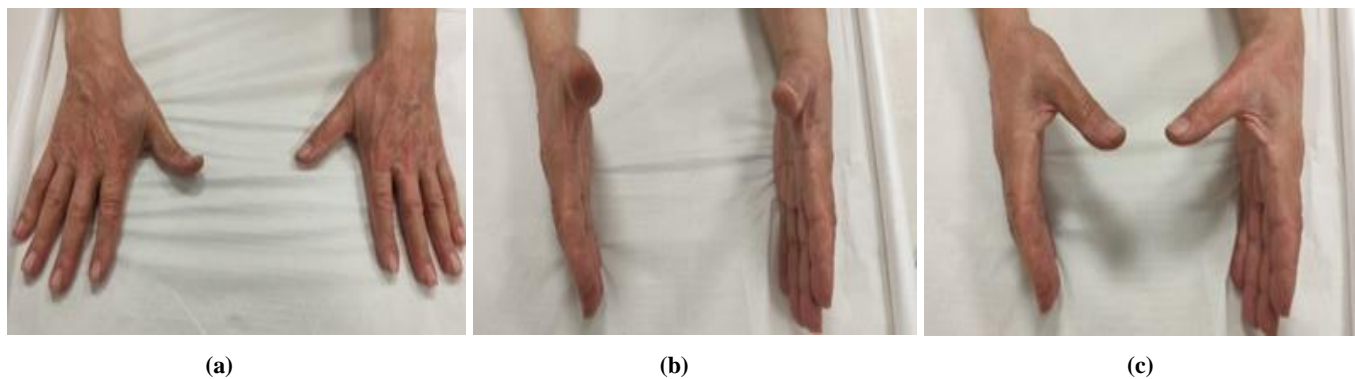
Harrison et al (1972) presented restoration of thumb after EPL ruptures with application as donor tendon the Extensor Pollicis Brevis in thirty-seven patients with rheumatoid arthritis and reported functional outcomes in a period of four year follow-up. The author suggests this donor tendon reserving Extensor Indicis Proprius for the extensor of the fingers and outlined that good functionally outcomes were achieved in the thumb [14].

The aim of this study is to answer the question: is the Extensor Pollicis Brevis transfer technique the most competent and

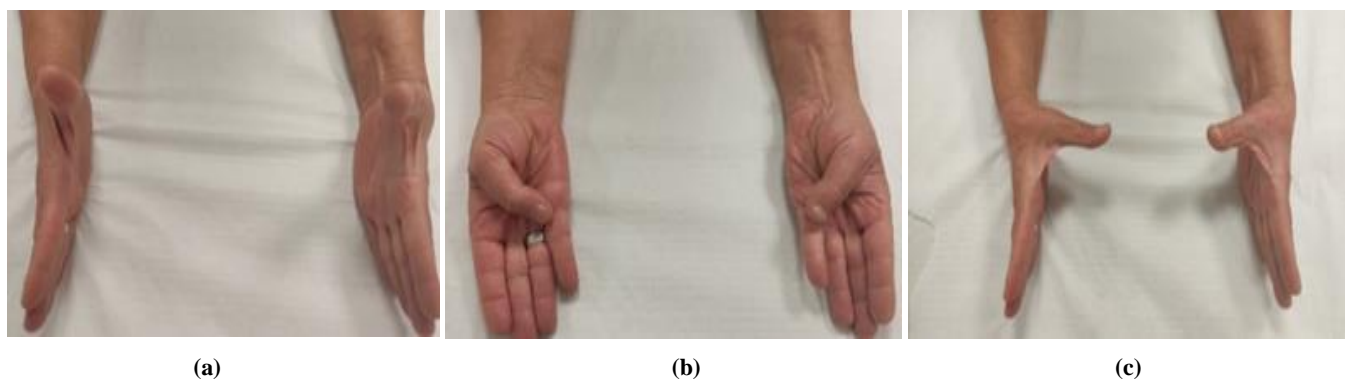
efficient surgical method for rupture of EPL, analyzing our functional outcomes in long term (minimum one year), complications (affecting the donor area, reoperation) and final patient’s satisfaction?

### Material and Methods

This study was performed at the Orthopaedic department of General Hospital of Heraklion- “Venizeleio-Pananeio” from January 2017 to February 2020. The Institutional Ethical Committee approved the study. In this study the following information was acquired: demographic elements (age, sex and occupation), clinical history of trauma or steroid injections, clinical sign of ruptures, co-morbidities and imaging findings (x-rays-magnetic resonance imaging). Eighteen patients with atraumatic spontaneous rupture of Extensor Pollicis Longus included in this study. Fourteen patients were female and four male with an average age of 43 years old (range from 34 to 58 years old). The right hand was involved in 12 cases while the left in 6. The dominant hand was the right in 12 patients, the left in 3 patients and the non-dominant in 3 cases. All patients reported no history of trauma. Eight cases detect rheumatoid arthritis while in 4 cases steroid injection was performed for dorsal wrist pain in a ranging period of twelve weeks (range from 10 to 16 weeks). One patient was operated for spontaneous rupture of EPL three months before, with transfer of EIP. Among various occupations most of the patients had professions that demand extensive and incessant motion of the hand. Six patients presented one or more comorbidities in their clinical history including diabetes mellitus II (3 cases), hypertension (2 patients), coronary artery disease (1 case). (Table I)



Case 1: male, 53 yrs old, with ruptures of left EPL after corticosteroid injection. Range of motion 19 months postsurgery (a,b,c)



Case 2: Female 56 yrs old, with clinical historic of rheumatoid arthritis, with rupture of left EPL. Range of motion 24 months postsurgery (a,b,c)

**Table I. Demographic characteristics of patients**

<b>Gender (male/female)</b>	<b>4/14 (22,2%/77,8%)</b>
Average Age	43(range 34-58)
Hand Involved (Right/Left)	12/6 (66,7%/33,3%)
Hand Dominance (Right/Left)	12/3 (66,7%/16,7%)
<b>Causes</b>	
Rheumatoid Arthritis	8 (44,4%)
Corticosteroid Injection	4 (22,2%)
Re- ruptures of tendon transfer	1 (5,6%)
Unknown	5 (27,8%)
<b>Comorbidities</b>	
Diabetes Mellitus	3 (16,7%)
Hypertension	2 (11,1%)
Coronary artery disease	1 (5,6%)
Rheumatoid Arthritis	8 (44,4%)

All patients on clinical examination presented weakness to extend the distal phalanx of the thumb, while flexion of the interphalangeal joint was not altered. Patients referred pain (varied from mild to severe) on the radial side of the wrist, before inability to extend the distal phalanx of the thumb, with a range of 10 days (from 4 days to 25 days) before rupture of EPL. In majority of cases pain did not ameliorate the daily living activity. Radiographic investigation was normal in all cases while, magnetic resonance studies detect Extensor Pollicis Longus ruptures. The distal portion of the EPL (MRI findings) was at Lister's tubercle while the proximal portion of the tendon was retracted in forearm. All patients were operated in a middle time of 3,4 weeks (range from 2 to 6 weeks) after the diagnosis.

## Surgical Technique

All patients were operated with regional anesthesia, in supine position with arm tourniquet and all operations were performed by author the same. A lazy S incision is made over metacarpophalangeal joint starting from the ulnar side of the proximal phalanx, centered at the MCP joint and extended on the radial side of the first metacarpal. The EPL was exposed and recognized firstly and then secondly the Extensor Pollicis Brevis tendon on the radial side of EPL. Extensor Pollicis Brevis was transected from the base of the proximal phalanx. The tendon was repaired using a pulvertaft suture with a nonabsorbable 4-0 suture. Initial tendon tension managed with interphalangeal and metacarpophalangeal joints in full extension. Closure of the wound was detected with nonabsorbable sutures 3-0. Postoperatively in all patients were applied a volar splint with the wrist in neutral and the thumb in abduction and extension to secure and to protect the tendon tension for four weeks. Patients were discharged the same day after a dose of antibiotic (cephalosporin) given. The stitches were removed two weeks later and after removal of the splint a rehabilitation program started with scope to recover motion and strength of the thumb.

Physical therapy was taken to control oedema and exercises were performed for the undamaged fingers. Scar massage was done when the wound looked dry and patients trained to do friction themselves, 4-5 times a day for 5mins to prevent adhesions. Patients were trained to perform the activities that are possible while wearing the post-operative splint in the first 2 weeks. In the early postoperative days, passive extension of the thumb, wearing a splint, was performed and early passive-active movements were done as well. Between the fourth and the sixth week a removable

nocturnal splint was applied and patients were advised to do flexion and extension exercises of the IP, MCF and CMC of the thumb, every 2 hour, with the wrist in neutral position. In some cases it was necessary to continue measures to control lymphoedema for 8 weeks and possibly longer. Approximately 4 weeks postoperatively, full active range of movement was achieved and patients were trained to repeat exercises 5 times every 2 h. Patients were trained to return progressively, in daily activities such as washing, eating and dressing at 5-6 weeks postoperatively. A graduate strengthening exercise program was initiated according to patients progress as soon as full range of movement was achieved after 8 weeks postoperatively and patients were assessed weekly for 3 months.

## Results

The mean follow-up is about 20.5 months (range from 15 months to 36 months). None of patients missed the last re-examination. Results were evaluated according to complications, range of motion of the thumb (elevation deficit, opposition distance, difference flexion-extension deficit), Quick Dash Score, EQ-5D-5L (which measures health status using three levels of severity in five dimension), and satisfaction of the patients using the "Patient satisfaction rating scale"<sup>[42,43]</sup>. We didn't notice any intra or extra-operative complication or re-ruptures of extensor tendon of the thumb. After removal of the splint all patients were capable to extend (initially a few degrees) the distal phalanx of the thumb and after rehabilitation program the majority of them returned to the previous daily activities without restriction, inability or pain. Postoperative functional range of motion was succeeded in all patients.

At final follow-up the mean range of elevation deficit (the maximum height obtained when placing both hands on the table and lifting the thumb as high as possible while kipping the fingers and palms flat on table) was 0,7(from 0,5 to 1,5), opposition distance(the distance of the thumb tip to the MP joint of the little finger) was 0,8(range from 0,5 to 1,8) and difference flexion-extension deficit(the difference in the combined movement of the flexion and extension of the thumb compared with the opposite thumb was 1,6° (from 0° to 5°). The Quick dash score was used to assess the retrieval status of patients after the surgical method of EPB applied and for the control final outcomes. At the final follow up the main score was 1.38(varied from 0.0- 6.8). Most of the patients were capable to perform the previous daily activities without pain or restriction. One patient with rheumatoid arthritis (reoperation for re-ruptures of EPL which was applied EIP) presented a final control Quick Dash score 6.8 and we believe that the functional status was influenced by the patient's disease because the extension of the thumb was restored and was pain-free.

The EQ-5D-EL was used to assess the self-care status and at final follow up, 90% of the patients did not report any severe problems on the EQ-5D-5L and in five dimensions: mobility, self-care, usual activities, pain and anxiety (health profile mean value in 5 levels was 11112) and the average EQ VAS was 92.

Finally, all patients' response to major question referred to the satisfaction rating scale with five elements (very satisfied, satisfied, neutral, unsatisfied, very unsatisfied). From eighteen patients twelve were very satisfied (66,7%), five satisfied (27,8%) and one case (5,5%) was unsatisfied from the final functional outcomes but all returned to previous functional activity. The one only case which was unsatisfied presented the poor Quick dash score.

## Discussion

Spontaneous rupture of EPL is a rare clinical entity, and few references exist in medical literature as case reports or groups of patients. First described from the Duplay at 1876, when it was a rare medical condition [21]. Two major basic theories (mechanical, vascular) have been described to the pathogenesis of spontaneous rupture of the EPL. Engkvist et al (1979) introduce the vascular theory, in which the researcher analyzed the vascularity of EPL, disclose that tendon around Lister's tubercle present an avascular zone. This led him to the conclusion that increased pressure within the tendon sheath at Lister's tubercle cause ischemia and delayed rupture of the tendon [3]. Bjorkman et al (2004) support the mechanical theory that after a distal radius fracture the rough bony edge cause friction of the tendon during its motion leading to rupture [5]. Opposite, Hu et al(2015) suggest that metabolic and vascular factors play substantial role in the etiology of spontaneous rupture of EPL (and probably pre-exist) than pure mechanical friction of the tendon [22].

Harris (1951) suggest that rheumatoid arthritis is a basic factor for the spontaneous ruptures of EPL, while Boussakri et al (2014) introduce that corticosteroid injection must be regarding predominant cause [24,25]. A category of patients presenting this injury are professional athletes who need violent motions of their hand, eventual possible injuries and other who used steroids [26,27]. Another basic risk factor for rupture of EPL is distal radius fracture(DRF) in which direct mechanical shearing force from the bone edges of the dorsal cortex of the radius can produce the rupture [22,28]. Female predominance of EPL rupture after distal radius fracture with an incidence of 60% and the paradoxes is that the DRF was nondisplaced [29].

Avci et al (2002) report that de Quervain's disease especially in woman during pregnancy or period of lactating because a disturbance of hormonal factors exists and repetitive activities contribute as risk factors for rupture of EPL [22,30]. In our study none of patients had history of trauma, seven cases suffered from rheumatoid arthritis, and four patients participated in sports. Three of the athlete's group reported corticoid injection, while the fourth patient had the injection because of manual work. In rest of cases the etiology was unknown.

The diagnosis of rupture based on the clinical examination in which the patient presented inability to extend the distal phalange of the thumb. Radiography examination distinguish secondary osteophytosis which may be liable for tendon rupture [1]. Magnetic resonance imaging demonstrate the location of the tendon rupture and quality of others extensor to use as donor tendon.

By retrospective literature among treatments many surgical techniques had been proposed with scope to restore the extension range of the thumb which included direct repair, tendon transfer and tendon grafting [22]. Direct repair of the ruptures tendon is very problematic with poor results because the two ends of tendon are breakable and thin and the results of suturing due to the degenerative process leads to re-rupture [1,22]. Tendon grafting with Palmaris Longus(PL) tendon has been mentioned by some authors [31,32]. Magnell et al (1988) present his results in 21 cases and suggest that respective technique offer the advantage that not jeopardize function of the index finger, and the patient is able to return in normal function because the donor tendon is a motor tendon. Disadvantages of the method are: the use of an avascular portion of the tendon, the use of two sutures proximal and distal can lead to failure of the tendon anastomoses [31]. Schaller (2007) and Pillukat (2008) compared to the results between tendon

grafting with PL and tendon transfer with EIP, and concluded that both techniques present good functional outcomes but free tendon grafting is more demanding, preserving function of the index and must be applied in patients with special demand of function(such as musicians). Opposite, the EIP transfer is not technically demanding, requires retrain of the patient, and maybe alterity the index function [32,33].

Backhouse (1981) introduced as donor tendon transfer the Abductor Pollicis Longus (APL) and report good functional motion (abduction, extension, radial deviation and opposition of the thumb) [34]. Advantages of the method are that APL is less affected by rheumatoid disease, needs only one incision, there is impaired abduction of the thumb, and the EIP can be preserved for other extensors rupture. The only limitation is that APL cannot be employed when the distal end of EPL is short and cannot access the wrist [12]. The same results report Chitnis et al (1993) and suggest to transfer the APL from the carpus to distal end of EPL to increase the excursion of the tendon [12]. Bullón A.(2007) report as tendon transfer the Accessory Abductor Pollicis Longus (AAPL) in 11 cases of ruptures of EPL after DRF and conclude that as donor APL is an alternative method especially in chronic ruptures with the advantages that thumb abduction is not sacrificed and good overall function of the thumb is maintained with high patient satisfaction [10].

Extensor Indicis Proprius has been reported as the gold standard tendon transfer recovery of the thumb after rupture of EPL [1,6,11,13,35,36]. There are reports in literature referring to the disadvantages of the method such as, reduced strength of index extension, loss of dexterity and independent extension of the index finger and shortfall in normal daily activities [19,31,37,38]. Tubiana (1986) suggest avoiding the EIP for tendon transfer in patients who require independence of finger motion(musicians) [39]. Anatomic study of EIP present an anomalous EIP muscle in an incidence of 4% and absence of the tendon in an incidence of 4%. In such cases, an alternative donor tendon must be preoperatively planning [3,40,41].

Harrison et al (1972) present the satisfied functional outcomes of 37 patients with spontaneous ruptures of EPL. All cases suffered with rheumatoid arthritis and the tendon which applied was EPB. The concept of this tendon selection was supported by the following parameters: I. preservation of the Extensor Indicis Proprius which might be needed later to repair other extensors, II. After surgical repair the extension of the thumb is in abduction position rather than in adduction, III. The operation technique is much easier to perform [14]. Author suggested this method and emphasized that using EPB to repair EPL, the thumb is held in the abducted position so that the tactile area can be used efficiently in pinch. We started to use the EPB as tendon transfer because the first 3 subjects suffered by rheumatoid arthritis and the fourth was a revision surgery. In our study, the majority of cases have excellent functional outcomes and approximately all subjects were presented as satisfied and returned to previous level of daily activities.

This study has the following limitations: the patient' sample is not similar (rheumatoid arthritis, corticosteroid injections, revision surgery, unknown etiology) so possibly a homogeneous sample at follow-up may show different results. The number of cases and the follow-up period are relatively small and short respectively. However, the above parameters cannot confine the satisfactory result of the method.

## Conclusion

Spontaneous ruptures of Extensor Pollicis Longus tendon are not rare injuries and are present with specific predisposing risk factors. As gold standard treatment has been described the transfer of Extensor Indicis Proprius to restore the functionality of the thumb. Nevertheless, the utilization of Extensor Pollicis Brevis is an alternative surgical method with significant advantages with no sacrificed thumb abduction and preservation of good functionality of the thumb, parallel with excellent patient satisfaction.

## Conflict of Interest

The authors declare that have no conflict of interest.

## Ethical Approval

The Institutional Ethical Committee approved this study.

## References

- [1] Gianluca S, Ceri L. Transposition of the Extensor Indicis Proprius (EIP) for inveterate post-traumatic rupture of the Extensor Pollicis Longus (EPL) of the hand. 12 clinical cases. *Acta Biomed* 2019;5(90):147-151, doi:10.23750/abm.v90i12-S.8884.
- [2] Goldner JL Tendon transfers in rheumatoid arthritis. *Orthop Clin North Am* 1974;5(42):425-44.
- [3] Engkvist O, Lundborg G. Rupture of the extensor pollicis longus tendon after fracture of the lower end of the radius: a clinical and microangiographic study. *Hand*. 1979;11(1):76–86, doi:10.1016/s0072-968x(79)80015-7.
- [4] Roth KM, Blazar PE, Earp BE, et al. Incidence of extensor pollicis longus tendon rupture after nondisplaced distal radius fractures. *J Hand Surg-Am*. 2012; 37:942–7. doi: 10.1016/j.jhsa.2012.02.006.
- [5] Bjorkman A, Jorgsholm P. Rupture of the extensor pollicis longus: a study of etiological factors. *Scand J Plast Reconstr Surg Hand Surg*. 2004;38(1):32–35, doi:10.1080/02844310310013046.
- [6] Gelb RI. Tendon transfer for rupture of the extensor pollicis longus. *Hand Clin*. 1995;1(3):411–422.
- [7] Platzer W. Color atlas of human anatomy, Vol. 1: locomotor system. In: Austin NM, editor. *Joint Structure and Function: A Comprehensive Analysis: The Wrist and Hand Complex*. Philadelphia: Thieme, FA Davis Co; 2011:588.
- [8] Hirasawa Y, Katsumi Y, Akiyoshi T, et al. Clinical and microangiographic studies on rupture of the E.P.L. tendon after distal radial fractures. *J Hand Surg Br*. 1990;15(1):51–57. doi:10.1016/0266-7681(90)90048-9.
- [9] Skoff HD. Postfracture extensor pollicis longus tenosynovitis and tendon rupture: a scientific study and personal series. *Am J Orthop* 2003;32(5):245-7.
- [10] Bullón A, Bravo E, Zarbahsh S, Barco R. Reconstruction after chronic extensor pollicis longus ruptures: a new technique. *Clin Orthop Relat Res*. 2007; 462:93-8, doi:10.1097/BLO.0b013e31806db4bc.
- [11] Hoch J, Losch GM, Schrader M. Long-term results following reconstruction of the tendon of the extensor pollicis longus muscle by transposition of the tendon of the extensor indicis muscle. *Handchir Mikrochir Plast Chir*. 1988;20(2):93–96.
- [12] Chitnis SL, Evans DM. Tendon transfer to restore extension of the thumb using abductor pollicis longus. *J Hand Surg Br*. 1993;18(2):234–238, doi:10.1016/0266-7681(93)90117-x.
- [13] Germann G, Wagner H, Blome-Eberwein S, Karle B, Wittemann M. Early dynamic motion versus postoperative immobilization in patients with extensor indicis proprius transfer to restore thumb extension: a prospective randomized study. *J Hand Surg Am*. 2001; 26(6):1111–1115, doi: 10.1053/jhsu.2001.28941.
- [14] Harrison S, Svannek AJ, Ansell BM. Repair of the extensor pollicis longus using extensor pollicis brevis in rheumatoid arthritis. *Ann Rheum Dis*. 1972;31(6):490–492, doi:10.1136/ard.31.6.490.
- [15] Choi JC, Kim WS, Na HY, Lee YS, Song WS, Kim DH, Park. Spontaneous rupture of the extensor pollicis longus tendon in a tailor. *Clin Orthop Surg*. 2011;3(2):167-9, doi:10.4055/cios.2011.3.2.167.
- [16] Verdan CE. Primary and Secondary Repair of Flexor and Extensor Tendon Injuries. In: Flynn JE, Ed. *Hand Surgery*. 2nd ed. Baltimore: Williams & Wilkins 1975.
- [17] Iyer S. Extensor digiti minimi transfer for thumb extension. *J Plast Reconstr Aesthet Surg*.2013;66(9): e264-6, doi: 10.1016/j.bjps.2013.03.010.
- [18] Schwartz MG, Green SM, Coville FA. Dorsal dislocation of the lunate with multiple extensor tendon ruptures. *J Hand Surg Am*. 1990;15(1):132–133, doi: 10.1016/s0363-5023(09)91120-0.
- [19] Stahl S, Wolff TW. Delayed rupture of the extensor pollicis longus tendon after nonunion of a fracture of the dorsal radial tubercle. *J Hand Surg Am*. 1988;13(3):338–341, doi: 10.1016/s0363-5023(88)80004-2.
- [20] Kojima T, Yasuda M, Hama S, Fukuda M, Minato K. Rupture of Extensor Pollicis Longus tendon caused by scaphoid non-union advanced collapse wrist. *Case Rep Orthop* 2020; 10; 2020:8850427. doi: 10.1155/2020/8850427.
- [21] Duplay S. Rupture souscutanee du tendon du long extensor du ponce. *Bull Mem Soc Chir Paris*. 1876;2:788.
- [22] Hu CH, Fufa D, Hsu CC, Lin YT, Lin CH. Revisiting spontaneous rupture of the extensor pollicis longus tendon: eight cases without identifiable predisposing factor. *Hand (NY)*. 2015;10(4):726–731. doi:10.1007/s11552-015-9746-y.
- [23] Gallucci GL, Pacher N, Boretto JG, De Carli P. Bilateral rupture of the extensor pollicis longus tendon. A case report. *Chir Main*. 2013;32(3):186–188. doi:10.1016/j.main.2013.04.001.
- [24] Harris R. Spontaneous rupture of the tendon of extensor pollicis longus as a complication of rheumatoid arthritis. *Ann Rheum Dis*. 1951;10(3):298–306. doi:10.1136/ard.10.3.298
- [25] Boussakri H, Bouali A. Subcutaneous rupture of the extensor pollicis longus tendon after corticosteroid injections for DeQuervain's stenosing tenovaginitis. *Case Rep Orthop*. 2014; 2014:934384, doi:10.1155/2014/934384.
- [26] Dawson WJ. Sports-induced spontaneous rupture of the extensor pollicis longus tendon. *J Hand Surg Am*. 1992;17(3):457–458, doi:10.1016/0363-5023(92)90348-s.
- [27] Fujita N, Doita M, Yoshikawa M, Fujioka H, Sha N, Yoshiya S. Spontaneous rupture of the extensor pollicis longus tendon in a professional skier. *Knee Surg Sports*

- Traumatol Arthrosc. 2005;13(6):489–491. doi:10.1007/s00167-004-0539-z.
- [28] Ferreres A, Llusà M, García-Eliás M, Lluch A. A possible mechanism of direct injury to the EPL tendon at Lister's tubercle during falls with the wrist fully extended. *J Hand Surg Eur Vol.* 2008;33(2):149–51, doi:10.1177/1753193407087575.
- [29] Roth KM, Blazar PE, Earp BE, Han R, Leung A. Incidence of extensor pollicis longus tendon rupture after nondisplaced distal radius fractures. *J Hand Surg-Am.* 2012;37(5):942–7, doi: 10.1016/j.hsa.2012.02.006.
- [30] Avci S, Yilmaz C, Sayli U. Comparison of nonsurgical treatment measures for de Quervain's disease of pregnancy and lactation. *J Hand Surg Am.* 2002;27(2):322–4, doi: 10.1053/jhsu.2002.32084.
- [31] Magnell TD, Pochron MD, Condit DP. The intercalated tendon graft for treatment of extensor pollicis longus tendon rupture. *J Hand Surg Am.* 1988;13(1):105–109doi:10.1016/0363-5023(88)90211-0.
- [32] Pillukat T, Prommersberger K-J, van Schoonhoven J. Comparison of the results between reconstruction of the extensor pollicis longus tendon using a free interposition tendon graft and extensor indicis transposition. *Handchir Mikrochir Plast Chir.* 2008;40(3):160-4, doi:10.1055/s-2007-965479.
- [33] Schaller P, Baer W, Carl HD, Extensor indicis – transfer compared with palmaris longus transplantation in reconstruction of extensor pollicis longus tendon: a retrospective study *Scand J Plast Reconstr Surg Hand Surg.* 2007;41(1):33-5, doi: 10.1080/02844310601070351.
- [34] Backhouse KM. Abductor pollicis longus musculotendinous split replacement motor for ruptured extensor pollicis longus. *Hand.* 1981;13(3):271–275, doi: 10.1016/S0072-968X(81)80008-3.
- [35] Zheng X, An H, Chen T, Wang H. Effectiveness of modified extensor indicis proprius tendon transfer for reconstruction of spontaneously ruptured extensor pollicis longus Tendon. *Zhongguo Xiu Fu Chong Jian Wai Ke Za Xhu,* 2012;26(9):1074-6.
- [36] Tsailas PG, Alvanos A. Delayed repair of spontaneous rupture of both the extensor pollicis longus and brevis: a case report. *Hand Surg.* 2012;17(1):105-8, doi:10.1142/S021881041270069.
- [37] Matter-Parrat V, Prunieres G, Collon S, Facca S, Liverneaux P, Hidalgo Diaz JJ. Active extensor indicis proprius extension strength after its use as a tendon transfer: 19 cases. *Hand Surg Rehabil.* 2017 Feb; 36(1):36-40, doi:10.1016/j.hansur.2016.09.013.
- [38] Lemmen MHM, Schreuders TAR, Stam HJ, Hovius SER. Evaluation of the restoration of the extensor pollicis function by transfer of the extensor indicis. *J Hand Surg Br.* 1999;24(1):46–49, doi:10.1016/s0266-7681(99)90025-6.
- [39] Tubiana R. Lèsions des tendons extenseurs du pouce. In: Tubiana R, ed. *Traite de Chirurgie de la Main.* Paris, France: Editorial Masson; 1986:168–173.
- [40] Zilber S, Oberlin C. Anatomical variations of the extensor tendons to the fingers over the dorsum of the hand: a study of 50 hands and a review of the literature. *Plast Reconstr Surg.* 2004;113(1):214–21, doi: 10.1097/01.PRS.0000091163.86851.9C.
- [41] Cauldwell EW, Anson BJ, Wright RR. The extensor indicis proprius muscle. A study of 263 consecutive specimens. *Q Bull Northwest Univ Med Sch.* 1943;17(4):267–79.



Open Access This article is licensed under a Creative Commons Attribution 4.0 International License, which permits use, sharing, adaptation, distribution and reproduction in any medium or format, as long as you give appropriate credit to the original author(s) and the source, provide a link to the Creative Commons license, and indicate if changes were made. The images or other third party material in this article are included in the article's Creative Commons license, unless indicated otherwise in a credit line to the material. If material is not included in the article's Creative Commons license and your intended use is not permitted by statutory regulation or exceeds the permitted use, you will need to obtain permission directly from the copyright holder. To view a copy of this license, visit <https://creativecommons.org/licenses/by/4.0/>.

© The Author(s) 2021