



# Severe Acute Colitis: A Countdown Diagnostic Challenge

Oussama Nacir <sup>\*1</sup>, Abbas Riyad <sup>3</sup>, Adil Ait Errami <sup>1</sup>, Sofia Oubaha <sup>1-2</sup>, Zouhour Samlani <sup>1</sup>, Khadija Krati <sup>1</sup>

<sup>1</sup>Department of Gastroenterology and Hepatology, Mohammed VI University Hospital of Marrakech, Morocco

<sup>2</sup>Department of Physiology, Faculty of Medicine and Pharmacy of Marrakech, Cadi Ayyad University, Morocco

<sup>3</sup>Faculty of Medicine of Laayoune, Ibn Zohr University, Morocco

\*Corresponding author: Oussama Nacir; [dr.oussamanacir71@gmail.com](mailto:dr.oussamanacir71@gmail.com)

Received 13 October 2022;

Accepted 12 November 2022;

Published 17 November 2022

## Abstract

**Introduction:** Severe acute colitis (SAC) complicates 10-15% of ulcerative colitis and more rarely Crohn's disease or infectious colitis [1]. It is a medical and surgical emergency requiring rapid diagnosis and early management. It can lead to major digestive mutilation, which can cause sequelae that often alter the quality of life of patients for decades [2]. In this study, spread over 10 years, we propose a descriptive analysis of the epidemiological, clinico-paraclinical and evolutionary aspects of a series of cases of SAC admitted to the Mohammed VI University Hospital of Marrakech. We will then review the diagnostic procedures that preceded, but did not prevent, recourse to surgery, discussing them in the light of the current literature. **Materials and Methods:** This is a retrospective observational study with a descriptive and analytical aim, spread over 10 years, from January 2011 to December 2020, including all patients admitted to the Mohammed VI University Hospital of Marrakech and operated on for acute severe colitis and whose diagnosis was retained on the basis of a set of arguments. An exploitation form was chosen as a means of investigation. Data collection was based on hospitalization registers, patients' medical records, the "Hosix" computerized system, and the collaboration of the medical and paramedical staff of the department and the operating room. Statistical analysis was performed using SPSS version 19.0 software. **Results:** Out of a total of 550 inflammatory bowel disease (IBD) cases admitted to the Mohammed VI University Hospital of Marrakech, 100 patients (18.2%) presented with severe acute colitis during the period of our study. The operated SACs meeting the inclusion criteria of our study represented 20% (20 cases) of the total number of targeted SACs. The mean age of the patients was 34 years. The age group between 20 and 40 years represented 65% of the cases with a sex ratio of 0.81. The SAC was inaugural in 7 patients (35%) and had complicated a known inflammatory bowel disease in 13 patients (65%). The clinical picture consisted of bloody glutinous emissions and abdominal pain in 100% of cases. Abdominal examination on admission revealed abdominal sensitivity in 85% of cases, and tenderness in 15% of cases. The Blood count was normal in 25% of cases with an average haemoglobin of 12 g/dl. The c-reactive protein was elevated in 85% of patients (17 cases) with an average of 120 mg/l. Hypoalbuminemia was noted in 17 patients (85%). The unprepared abdominal X-ray (UAP), performed in 80% of the patients, was normal in 60% of the cases, with pneumoperitoneum in 10% and colectasis in 10%. Abdominal ultrasound was performed in 95% of the patients and revealed digestive thickening in 75% of the cases and a medium-sized peritoneal effusion in 30% of the cases. Abdominal CT scan was performed in 75% (15 patients), confirmed digestive thickening in 73% of cases, a medium-sized effusion in 33% of cases, pericolic fat infiltration in 33% of cases, right iliac fossa abscess (6%) and colectasis in two cases (12%). Left colonoscopy was performed in 18 patients (96%). Endoscopic signs of severity were found in 77% of patients. The diagnosis of severe acute colitis was made on the basis of the criteria of Truelove and Witts. In terms of therapeutic management, rest of the digestive tract with parenteral nutrition was indicated in 7 patients (35%). Antibiotic treatment was initiated in 65% of cases. The first-line medical treatment of SAC consisted of intravenous corticosteroid therapy in 16 patients (85%). Local treatment with mesalazine or salazopyrin was used in 65% of cases (13 patients). Failure of first-line medical treatment in 9 patients (45%) led to emergency colectomy, and 6 non-operated patients were put on cyclosporine. Six patients underwent colectomy for failure of second-line treatment. In contrast, two patients were treated with third-line infliximab with poor clinical tolerance which also led to colectomy. At 2 years after colectomy, 3 of our patients (15%) had recurrence on the remaining rectal stump. The functional outcome was marked by an average of 2 to 3 daytime bowel movements, and 0 to 1 nighttime bowel movement in most patients, only one case of rectal imperiousness (5%) and no case of sexual disorders or infertility. **Conclusion:** Acute severe colitis is an alarming complication of chronic inflammatory bowel disease. Its management must be rapid, reasoned and coordinated from the outset, based on multidisciplinary collaboration. Our study focuses on the initial diagnostic and therapeutic difficulties of GAC, which always constitute a challenge in reverse count.

**Keywords:** Acute severe colitis, Inflammatory bowel disease (IBD), diagnosis, treatment, attitude

## Introduction

Cryptogenetic inflammatory bowel diseases (IBD), including ulcerative colitis (UC), Crohn's disease (CD) and indeterminate colitis, are inflammatory conditions affecting the digestive tract in part or in whole and evolving through flare-ups interspersed with

periods of remission. They are chronic diseases resulting from a combination of genetic and environmental factors, the exact etiology of which remains unknown [3].

Severe acute colitis (SAC) complicates 10-15% of UC and more rarely CD or infectious colitis. It may be inaugural in 21% of cases, or it may occur during the course of an already known disease

[4]. It can lead to major digestive mutilation, which can cause sequelae that often alter the quality of life of patients for decades [5]. The diagnosis of SAC is based on a combination of clinical and biological criteria and may be supported by endoscopic and radiological morphological criteria. SAC is a medical and surgical emergency requiring rapid diagnosis and early management. The mortality rate fell from 30% in 1952 to around 2% in the 1970s thanks to early recourse to surgery after failure of well-managed medical treatment [6,7].

In this retrospective study spread over 10 years, we propose an observational analysis of the different epidemiological, clinico-paraclinical and evolutionary aspects of a series of severe acute colitis cases admitted to the Mohammed VI University Hospital of Marrakech. We will then focus on the diagnostic approaches that preceded, but did not prevent, recourse to surgery, discussing them in the light of the current literature.

**Materials and Methods**

This is a retrospective observational study with descriptive and analytical aims, spread over 10 years, from January 2011 to December 2020, on a series of 550 cases followed for IBD at the hepato-gastroenterology department of the Mohammed VI University Hospital in Marrakech. We included in our series all patients admitted to the Mohammed VI University Hospital of Marrakech and operated on for acute severe colitis and whose diagnosis was retained on the basis of clinical and biological criteria (modified Truelove and Witts criteria) solidified by morphological data, patients operated on for the same diagnosis, as well as patients admitted with a complication in this sense.

In addition, we excluded patients with IBD who underwent elective surgery for chronic complications, and records that were unusable, empty or lost.

An operating form was chosen as a means of investigation. The latter contained clinico-biological, morphological, therapeutic and evolutionary parameters allowing the collection and multimodal analysis of all the data of our patients. Data collection was based on hospitalization registers, patients' medical records, the "Hosix" computerized system for biological and morphological data, and the collaboration of the medical and paramedical staff of the department and the operating room. Statistical analysis was performed using SPSS version 19.0 software. The descriptive analysis consisted of a calculation of absolute and relative frequencies for the qualitative variables, and of the (mean, standard deviation) for the quantitative variables. The collection of sociodemographic, clinical and paraclinical data was done taking into consideration the global ethical rules concerning the respect of confidentiality and the protection of patients' data.

**Results**

Out of a total of 550 cases of IBD hospitalized in the hepato-gastroenterology department of the Mohammed VI University Hospital in Marrakech, 100 patients, (18.2%) presented with severe acute colitis during the period of our study. The operated SACs meeting the inclusion criteria of our study represented 20% (20 cases) of the total number of SACs targeted.

The average age of the patients was 34 years with extremes ranging from 17 to 52 years. The age group between 20 and 40 years represented 65% of the cases, divided into 11 women (55%) and nine men (45%) with a sex ratio of 0.81. SACs was inaugural in 7 patients (35%) and had complicated a known IBD in 13 patients (65%). These were eleven cases of ulcerative colitis and two cases of crohn's disease. Among the known IBD patients, 6 patients (30%) had a previous history of severe relapse. Two patients were on 6-Mercaptopurine (6MP) and two patients on Azathioprine. The average disease course was 32 months with extremes of 15 days and eight years. The extent of the disease in the history was pancolitis in

30% of the cases, ileocolic in 25% of the cases, the extent was not specified in 30% of the cases (Figure 1).

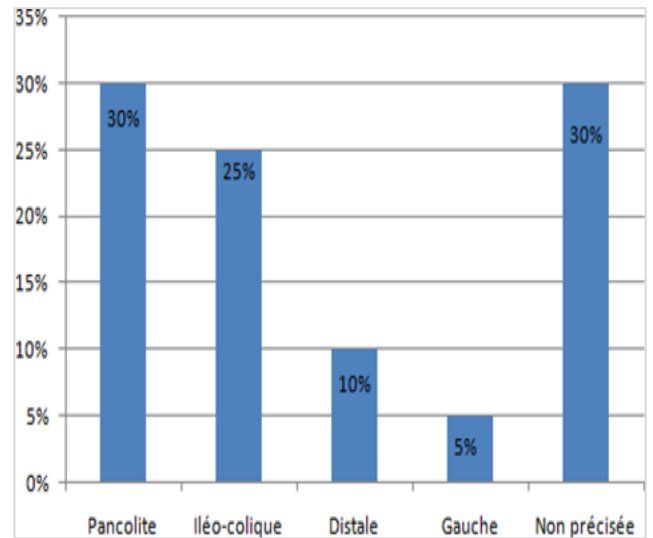


Figure 1: Extent of disease in our patients

The clinical picture consisted of consisted of bloody glutinous emissions and abdominal pain in 100% of cases. Liquid Diarrhea and rectal syndrome were present in 90% of the patients (18 cases) with a number of stools varying from 6 to 10 per 24 hours (Table I). The calculation of the body mass index indicated the presence of undernutrition in 30% of the patients. The average was 19.3 kg/m2 with extremes of 13 kg/m2 and 27.3 kg/m2. Abdominal examination on admission revealed abdominal sensitivity in 85% of cases, and tenderness in 15% of cases. The rectal examination was painful in 25% of cases, bloody in 15%, with sphincter weakness in 10% of cases. The presence of enterocutaneous fistulas was reported in two patients (10% cases).

Table I: Functional signs on admission

Clinical signs	Work force	Percentage
Bloody and glutinous broadcasts	20	100
Abdominal pain	20	100
Liquid diarrhoea	18	90
Rectal syndrome	18	90
Undernutrition and altered general condition	8	40
Extra digestive signs	13	65
Rectorrhagia	4	20
Koenig's syndrome	4	20

On admission, all our patients underwent a biological assessment. The Blood count was normal in 25% of cases with an average haemoglobin of 12 g/dl. Microcytic hypochromic anaemia was found in 75% of cases and hyperleukocytosis in 35% of cases. the c-reactive protein was elevated in 85% of patients (17 cases) with a mean of 120 mg/l and extremes of 10 mg/l and 340 mg/l. the sedimentation rate was accelerated in 95% of cases (19 patients). Renal function was normal in 19 patients (95%). Hyponatremia was found in 7 patients (35%) and hypokalemia in 10 patients (50%). Stool coproparasitology was performed in 100% of patients. It was normal in 35% of cases, indicating the presence of vegetative amebiasis in 35% of cases, and Entamoeba histolytica (EH) cysts in 30% of cases (Figure 2). Blood albumin was measured in all patients and showed hypoalbuminemia in 17 patients (85%). Blood cultures were sterile in 50% of patients.

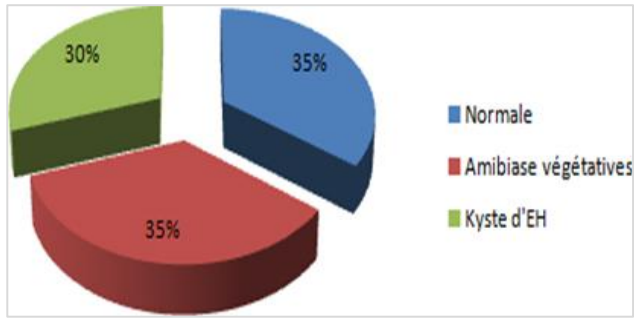


Figure 2: Copro-parasitological study of stools in our patients

An unprepared abdominal X-ray (UXR) was performed in 80% of patients. It was normal in 60% of cases, with pneumoperitoneum in 10% and colectasis in 10%. Abdominal ultrasound was performed in 95% of the patients, and revealed a thickening of the digestive tract in 75% of the cases, a medium-sized peritoneal effusion in 30% of the cases, and infiltration of the pericolic fat with mesenteric adenopathies in 15% of the cases (Figure 3).

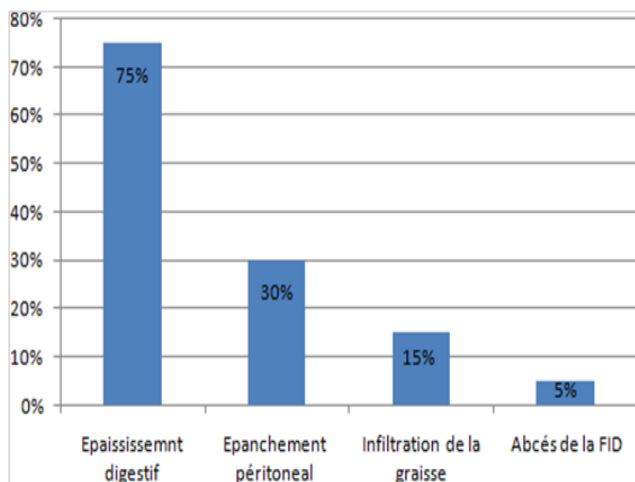


Figure 3: Distribution of ultrasound anomalies in our series

Abdominal CT scans were performed in 75% (15 patients), revealing digestive thickening in 73% of cases (Figure 4), medium-sized effusion in 33%, pericolic fat infiltration in 33%, right iliac fossa abscess (6%) and two cases of colectasis (12%). Entero-MRI was performed in 2 patients, revealing a retro-caecal collection in one and an entero-vesical fistula in the other.

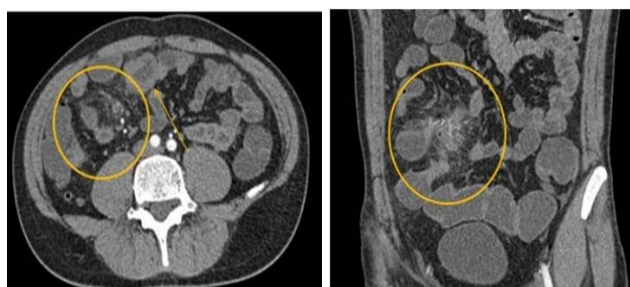


Figure 4: A+B: Abdominal CT scan after injection of PDC in axial sections: circumferential thickening enhanced in target (arrow), associated with infiltration of neighboring fat with a combed appearance of mesenteric fat (circle).

Left colonoscopy was performed in 18 patients (96%) excluding 2 patients with colectasis. The time to completion was 3 to 5 days. Endoscopic signs of severity were found in 77% of patients (Table II, Figure 5). All patients who underwent colonoscopy underwent pathology (Table III). The diagnosis of severe acute colitis was made in 100% of patients, based on the criteria of Truelove and Witts. The Lichtiger score ranged from 9 to 14 with an average of 12 in 17 of our patients.

Table II: Endoscopic signs of severity

	Number	Percentage %
Mucosal detachment	2	11
Deep ulcerations	5	27
Exposure of the musculature	2	11
Bleeding on contact	11	61
Pit ulcers	5	27

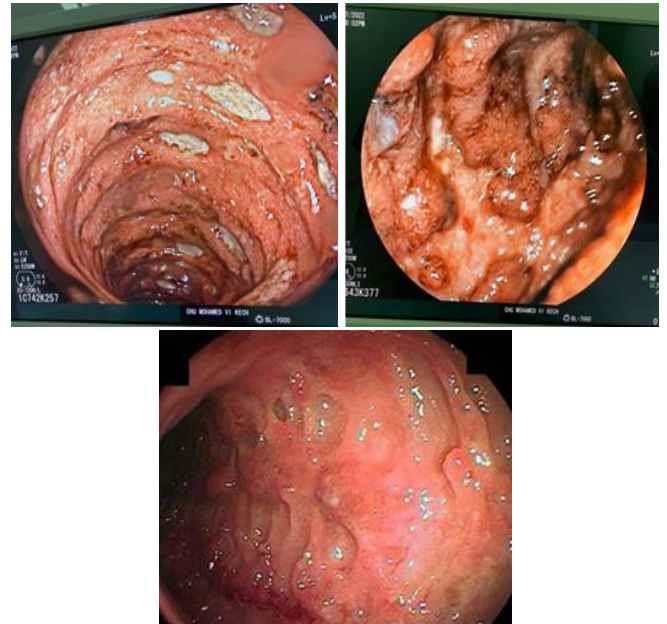


Figure 5: (a) Deep ulceration with mucosal detachment/(b) Pitted ulceration

Table III: Histological signs of patients in our series

	Number	Percentage
Architectural changes	6	33
Inflammatory infiltrate	7	38
Cryptic abscesses	9	50
Epithelial detachment	10	55
Decrease in mucus secretion	3	16

In terms of therapeutic management, rest of the digestive tract with parenteral nutrition was indicated in 7 patients (35%). Antibiotic treatment was initiated in 65% of the cases in which the temperature was above 37.8. The antibiotics used were metronidazole (84%), ciprofloxacin (46%), amoxicillin clavulanic acid (38%) and amikacin (23%). Prophylactic anticoagulation with LMWH was administered to all patients.

The first-line medical treatment of GCA consisted of intravenous corticosteroid therapy with Methylprednisolone at a mean dose of 60mg/day, initiated in 16 patients (85%). The duration of treatment varied from 2 to 7 days with an average of 5 days. Local treatment with mesalazine or salazopyrin was used in 65% of cases (13 patients). Failure of first-line medical treatment in 9 patients (45%) led to emergency colectomy, and 6 non-operated patients were put on cyclosporine. Only one patient in our series was started on cyclosporine without steroids. Six patients underwent colectomy for failure of second-line treatment. In contrast, two patients were treated with third-line infliximab with poor clinical tolerance which also led to colectomy. In addition, three patients were included in our series who underwent emergency surgery, two for colectasis (10%) and one for abdominal abscess (5%) without prior medical treatment.

All patients were readmitted to the IBD consultation of the gastroenterologists for background treatment and follow-up (Table IV). After 2 years after colectomy, 3 of our patients (15%) had a recurrence on the remaining rectal stump. No chronic complications were observed in any of the patients in our series. As for the

functional results, we noted an average of 2 to 3 diurnal stools, and 0 to 1 nocturnal stool, only one case of rectal imperiousness (5%) and no case of sexual disorders or infertility problem.

**Table IV: Post-operative maintenance treatment**

Maintenance treatment	Workforce	Percentage
Purinethol	1	5
Purinethol + mesalazine	1	5
Azathioprine	1	5
Azathioprine + mesalazine	2	10
Azathioprine + salazopyrin	2	10
Humira	2	10
Salazopyrin	3	15
Mesalazine	6	30
L'acide 5-aminosalicylique	1	5
corticosteroid therapy	1	5
Total	20	100

## Discussion

Severe acute colitis (SAC) is one of the dreaded complications of IBD and is a classic complication of UC seen in 15% of cases [4]. The vast majority of our patients admitted for SAC, both inaugural forms and forms complicating known IBD, occurred in the context of UC (84.6%) or CD (15.3%) [8]. The average age of our patients was 34 years with a slight female predominance. This average is consistent with the results of various Moroccan and Western series (Table V and VI).

**Table V: Comparison of the age distribution of patients.**

Series	Age	Extremes
Ouassi et al (2006) [9]	39	15-59
KABBAGE (2014) [10]	34	17-63
ALJAZZAR (2016) [11]	33,5	17-70
Our series (2018)	34	17-52

**Table VI: Comparison of the distribution of patients by gender.**

Series	Number of SACs	Female gender	Male gender	Sex ratio
Ouassi et al [9]	18	7	11	1,5
KABBAGE [10]	23	12	11	0,91
ALJAZZAR [11]	81	47	34	0,72
Our series	20	11	09	0,81

The diagnosis of SAC is based on a combination of clinico-biological criteria and may be supported by morphological criteria. In the case of inaugural SAC, the question is whether it is a first attack of IBD (UC or CD) or another colitis, particularly infectious. The clinical elements in favour of IBD are a family history of IBD, a progressive onset of symptoms with notions of repeated gastroenteritis, a duration of the current signs of more than 15 days, the existence of extra-digestive signs associated with or having preceded the attack, and more evocative still, the presence of old or recent anal lesions up to and including typical lesions, which indicate CD [12]. Indeed, a severe UC attack can inaugurate the disease in 21% of cases [4]. It is therefore important not to ignore an infectious cause and to systematically search for it on the patient's arrival, at least by a stool culture guided by a parasitological examination of the stool. Although there is no specific endoscopic aspect to confirm the infectious origin of a SAC, unprepared recto sigmoidoscopy allows biopsies to be taken, the diagnostic yield of which is better than stool analysis [12].

In addition, SAC can complicate 10-15% of patients with UC and can occur at any time in the life of patients being followed for IBD [8,13]. In practice, it is essential to look for an infectious agent that may have triggered or aggravated a severe attack. Thus, the

search for *Clostridium difficile* and its toxin in the stools must be systematic. A colonic superinfection with cytomegalovirus should also be sought, especially in the case of a corticoreistant relapse, and particularly in patients previously treated with immunosuppressants. In our series, the severe relapse complicated the course of known IBD in 65% of cases. In a similar study conducted at the University Hospital of Fez, SAC was the first episode of IBD in 58.3% of cases, and had complicated an already known IBD in 47.7% of cases [14]. These data are similar to the results of our study. In a cohort published in 2010 and including 1800 patients, 25% of UC patients were hospitalised for at least one episode of severe acute colitis [15] (Table VII).

**Table VII: Comparison of the distribution of patients according to the mode of onset of the disease**

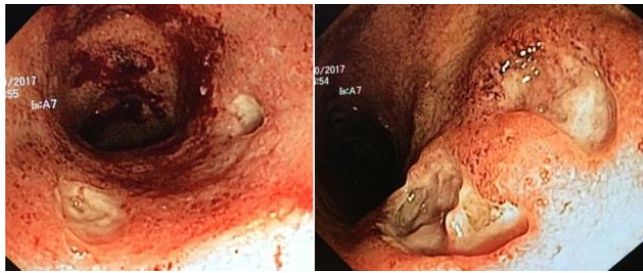Study	Inaugural GAC	GAC complicating IBD
ALJAZZAR	60,5%	39,5
University Hospital of FES [14]	58,3%	47,7%
L.C. Dinesen et al	34%	42%
Our study	35%	65%

Assessing the severity of colitis is an important goal for the clinician, and one on which drug treatment strategies and the possibility of emergency surgery to improve both prognosis and reduce mortality depend. No single reference clinical or imaging score can be preferred, but the combination of different prognostic criteria is useful [12].

The definition of a severe flare is based on clinico-biological scores developed specifically for UC [16]. In CS, a Crohn's Disease Activity Index (CDAI) score of more than 450 indicates a severe disease flare, but the need for seven-day collection limits its use in GAC [6,15]. The Truelove and Witts criteria, described in 1955 by the Oxford team, are still used to identify severe UC [13]. The sensitivity of these criteria is insufficient, and many patients are not classified as severe even though their prognosis is vital [17]. These criteria were adapted in 1974 by the same team, adding the level of plasma albumin [18]. More recently, the Lichtiger score has been proposed for the diagnosis and follow-up of GAC [19,16]. This score, which is purely clinical and very simple to use, can be performed daily at the patient's bed. It is currently the reference score, used in daily practice and in therapeutic trials.

In our series, we used this score to monitor our patients undergoing 1<sup>st</sup> line medical treatment, in order to assess their evolution and decide on the indication of a 2<sup>nd</sup> line treatment, in this case surgical treatment. The criteria of Travis et al. [20] criteria allow us to define a predictive score for colectomy [21].

Endoscopic examination, limited to a simple unprepared recto-sigmoidoscopy, is an essential part of the positive diagnosis of SAC, as well as the diagnosis of IBD. It is not essential to go beyond the left colonic angle if the distal endoscopic lesions are severe. Insufflation should be minimal and the examination interrupted as soon as the first severe lesions are visualised. Sigmoidoscopy, performed in 18 patients, i.e.96% of our series, plays a crucial role in the evaluation of the severity of the relapse, several scores have been devised but the most frequently used is the modified Baron score [22]. Macroscopic examination most often leads to a diagnosis of indeterminate colitis. However, its main interest is to look for signs of endoscopic severity (ES) [23]. The latter, present in 77% of the patients in our series, are located in the rectosigmoid in 89% of cases [24] (Figure 6).



**Figure 6: Recto-sigmoidoscopy in a patient with severe acute colitis: (deep ulcerations exposing the muscularis are visible in the sigmoid colon; the mucosa between the ulcerations has lost its vascular framework and bleeds spontaneously [15])**

The positive diagnosis of IBD is based on the association of architectural changes (rarefaction and disorganisation of crypts) and inflammatory lesions (predominantly plasma cell infiltrate). Cryptic abscesses have no specificity. Epithelioid granulomas are rarely seen in SAC [12]. The search for cytomegalovirus (CMV) inclusions should be made and should not exclude the diagnosis of IBD. Lesions may be associated with [25,26]. Pathological examination of 95% of patients did not reveal any inclusions in our patients.

The various imaging methods are requested essentially in search of complicated forms. An unprepared X-ray of the abdomen must be performed systematically on admission [27]. In our series, it allowed the diagnosis of colectasis in 2 patients and 2 pneumoperitoneum showing the presence of an intestinal perforation. Ultrasound is increasingly used in acute abdominal pathology, in search of peritoneal effusion or complications such as abscesses, fistulas or phlegmons. High resolution ultrasound seems to be interesting for monitoring patients undergoing treatment, however poor inter-observer reproducibility has limited its use to a few teams [25,28]. It can, in rare cases, illustrate the parietal thickening of colitis or the scalloped appearance of intra-mural hematomas in ischemia. In our series, ultrasound was requested in 95% of cases, essentially because of a doubt about a complication.

Abdominal CT is nowadays the most commonly used examination for severe relapse [4,26]. It is currently considered the reference imaging method for detecting abdominal complications related to IBD, and should be performed without delay in the event of any clinical suspicion of complication, both on arrival and during follow-up [2,12]. Abdominal CT scans, performed in 75% of patients, confirmed the diagnosis of right iliac fossa abscess and assessed its extent in one case; in the other cases, it showed an effusion and/or thickening of the intestinal wall.

Colo-MRI with or without low-level opacification appears to be a promising option. This specific, moderately sensitive technique can be reserved for patients who fail endoscopy. A comparative trial of the performance of colonic MRI and video colonoscopy reported a sensitivity of 59% and a specificity of 91% for colonic MRI in UC [29]. In addition, in an oral communication at the JFHOD, Roset Jean-Baptiste demonstrated that colo-MRI is an easily performed examination, the results of which are significantly correlated with those of rectosigmoidoscopy in severe UC attacks. It allows to look for signs of severity on the whole colonic framework difficult to explore totally by endoscopy in this situation, with moreover a zero risk of complications (perforation +++) [30]. In our series, 2 patients benefited from this radiological examination which showed a retro-caecal collection in one patient, and a trans-parietal fistula communicating with the bladder wall. However, these encouraging results deserve to be evaluated by prospective studies.

## Conclusion

Severe acute colitis is a severe complication of chronic inflammatory bowel disease. Its diagnosis is based on a combination of clinico-biological criteria supported by endoscopic and radiological morphological criteria. Its management must be rapid,

reasoned and coordinated from the outset, based on multidisciplinary collaboration. Surgery remains a crucial part of the therapeutic arsenal for GCA, and failure of medical treatment is the main indication. Our study highlights the initial diagnostic and therapeutic difficulties of GAC, which always constitute a challenge in reverse counting.

## Conflicts of interests

The authors declare no conflicts of interest.

## Authors' contributions

All authors contributed to the conduct of this work. All authors have read and approved the final manuscript.

## Acknowledgments

Not applicable

## Funding

The authors received no financial support for the research, authorship and/or publication of this article.

## Bibliography

- [1] G. BOUGUEN, "Personalised treatment in IBD ("treat-to-target"): concept and clinical reality".
- [2] D. Laharie, "How to optimize the management of severe acute colitis?", *Hepato-Gastro & Digestive Oncology*, vol. 17, no 4, pp. 21-27, 2010.
- [3] C. Fine, C. Stefanescu, and Y. Bouhnik, "IBD, the refractory disease".
- [4] G. P. De Chambrun et al, "État des lieux sur les MICI en France: Enquête nationale du GETAID", *Hepato-Gastro and Digestive Oncology*, vol. 26, no 2, 2019.
- [5] A. ATTAR, "Lesions élémentaires et scores endoscopiques dans les MICI".
- [6] M. Tapily, "Cancers of the colon in occlusion: Diagnostic and therapeutic aspects in the surgical service "A" of the CHU du Point G.", PhD Thesis, USTTB, 2019.
- [7] B. Olaiya, B. D. Renelus, M. Filon, and S. Saha, "Trends in morbidity and mortality following colectomy among patients with ulcerative colitis in the biologic era (2002-2013): a study using the national inpatient sample," *Digestive Diseases and Sciences*, vol. 66, no 6, pp. 2032-2041, 2021.
- [8] B. S. Pabla and D. A. Schwartz, "Assessing severity of disease in patients with ulcerative colitis," *Gastroenterology Clinics*, vol. 49, no 4, pp. 671-688, 2020.
- [9] M. Ouaissi, A. Alves, Y. Bouhnik, P. Valleur, and Y. Panis, "Three-step ileal pouch-anal anastomosis under total laparoscopic approach for acute or severe colitis complicating inflammatory bowel disease," *Journal of the American College of Surgeons*, vol. 202, no 4, pp. 637-642, 2006.
- [10] S. KABBAGE, "Morbidity and mortality of operated severe acute colitis. Experiences from surgical clinic C about 23 cases", PhD Thesis, 2014.
- [11] Mounia AIT AL JAZZAR, "Prise en charge des poussées sévères au cours des maladies inflammatoires intestinales". [Online]. Available at: <http://wd.fmpm.uca.ma/biblio/theses/annee-hm/FT/2016/these02-16.pdf>
- [12] T. Kucharzik, S. Koletzko, K. Kannengiesser, and A. Dignass, "Ulcerative colitis-diagnosis and therapeutic

- algorithms," *Deutsches Ärzteblatt International*, vol. 117, no 33-34, p. 564, 2020.
- [13] A. C. Moore and B. Bressler, "Acute severe ulcerative colitis: The Oxford criteria no longer predict in-hospital colectomy rates," *Digestive Diseases and Sciences*, vol. 65, no 2, pp. 576-580, 2020.
- [14] H. BENZOUINA, "La rectocolite hémorragique: l'évolution post traitement chirurgical. Service chirurgical "C" hopital avicenne Rabat," PhD Thesis, 2015.
- [15] S. Ribiere, M. Leconte, S. Chaussade, and V. Abitbol, "Severe acute colitis," *La Presse Médicale*, vol. 47, no 4, pp. 312-319, 2018.
- [16] P. Hruz, P. Juillerat, G.-A. Kullak-Ublick, A. M. Schoepfer, G. J. Mantzaris, and G. Rogler, "Management of the elderly inflammatory bowel disease patient", *Digestion*, vol. 101, no 1, pp. 105-119, 2020.
- [17] J. Du et al, "Characteristics and prognosis of isolated small-bowel Crohn's disease," *International Journal of Colorectal Disease*, vol. 35, no 1, pp. 69-75, 2020.
- [18] B. Zahira et al, "Epidemiological Study and Clinical Characteristics of Crohn's Disease in The West Algerian Population", *Egyptian Academic Journal of Biological Sciences. C, Physiology and Molecular Biology*, vol. 14, no 1, p. 47-54, 2022.
- [19] M. T. Abreu and N. Harpaz, "Diagnosis of colitis: making the initial diagnosis", *Clinical Gastroenterology and Hepatology*, vol. 5, no 3, pp. 295-301, 2007.
- [20] S. P. Travis et al, "Predicting outcome in severe ulcerative colitis", *Gut*, vol. 38, no 6, pp. 905-910, 1996.
- [21] E. De Cristofaro et al, "Long-Term Risk of Colectomy in Patients with Severe Ulcerative Colitis Responding to Intravenous Corticosteroids or Infliximab," *Journal of Clinical Medicine*, vol. 11, no 6, p. 1679, 2022.
- [22] C. Verdon, T. Bessissow, and P. L. Lakatos, "Management of acute severe colitis in the era of biologicals and small molecules," *Journal of Clinical Medicine*, vol. 8, no 12, p. 2169, 2019.
- [23] S. L. Jakobovits and S. P. L. Travis, "Management of acute severe colitis", *British medical bulletin*, vol. 75, no 1, pp. 131-144, 2005.
- [24] M. Boudabous, L. Mnif, L. Chtourou, A. Amouri, and N. Tahri, "Severe acute colitis: an old concept still in search of a consensual definition!", *African Journal of Hepato-Gastroenterology*, vol. 7, no 3, pp. 125-129, 2013.
- [25] T. Kucharzik et al, "ECCO guidelines on the prevention, diagnosis, and management of infections in inflammatory bowel disease", *Journal of Crohn's and Colitis*, vol. 15, no 6, pp. 879-913, 2021.
- [26] K. Matsuoka et al, "Evidence-based clinical practice guidelines for inflammatory bowel disease," *Journal of gastroenterology*, vol. 53, no 3, pp. 305-353, 2018.
- [27] A. Yaras et al, "The inflammatory bowel disease questionnaire in randomized controlled trials of treatment for ulcerative colitis: systematic review and meta-analysis", *Journal of patient-centered research and reviews*, vol. 7, no 2, p. 189, 2020.
- [28] M. G. E. RABBAA, "Prise en charge chirurgicale des colites aiguës graves au CHU Mohammed VI de Marrakech", 1995.
- [29] F. Varyani and S. Samuel, "Can Magnetic Resonance Enterography (MRE) replace ileo-colonoscopy for evaluating disease activity in Crohn's disease?", *Best Practice & Research Clinical Gastroenterology*, vol. 38, p. 101621, 2019.
- [30] J.-B. Roset, S. Hommel, G. Savoye, E. Lerebours, J. N. Dacher, and C. Savoye-Collet, "Apport de la colo-IRM dans la prise en charge des poussées sévères de rectocolite hémorragique", *Journal de Radiologie*, vol. 90, no 10, p. 1469, 2009.



Open Access This article is licensed under a Creative Commons Attribution 4.0 International License, which permits use, sharing, adaptation, distribution and reproduction in any medium or format, as long as you give appropriate credit to the original author(s) and the source, provide a link to the Creative Commons license, and indicate if changes were made. The images or other third-party material in this article are included in the article's Creative Commons license, unless indicated otherwise in a credit line to the material. If material is not included in the article's Creative Commons license and your intended use is not permitted by statutory regulation or exceeds the permitted use, you will need to obtain permission directly from the copyright holder. To view a copy of this license, visit <https://creativecommons.org/licenses/by/4.0/>.

© The Author(s) 2022