



To Study the Correlation between Acetabular Cup Size and Vertical Offset in Primary Total Hip Arthroplasty

Dr. Mohit Singh¹, Dr. Inder Pawar², Dr. Aakash Tomar³, Dr. Rohan Krishnan^{*1}, Dr. Amit Bisht¹

¹SR, PGIMSR, New Delhi.

²Professor, PGIMSR, New Delhi.

³AP, PGIMSR, New Delhi.

*Corresponding Author: Dr. Rohan Krishnan; rohannkrishnan@gmail.com

Received 07 November 2022;

Accepted 25 November 2022;

Published 01 December 2022

Abstract

Study design: Prospective Observational study.

Objectives:

- To study whether the acetabular cup size and vertical offset in primary total hip arthroplasty are correlated or both are independent of each other.
- If correlated, whether the acetabular cup size and vertical offset in primary total hip arthroplasty are directly related to each other or inversely.

Methods: A prospective study was conducted in Department of Orthopaedics, PGIMSR, New Delhi. 25 cases of ages 20 to 70 years were identified who had undergone primary total hip arthroplasty for various indications were included in the study. All the patients were assessed post operatively for acetabular cup size and vertical offset using plain X-ray pelvis with bilateral hip joints- AP view the very next day of surgery and Lower limb length discrepancy was assessed. **Results:** There is a significant positive correlation between acetabular cup size and vertical offset in patients undergoing primary THA with a correlation coefficient of 0.893 and p-value < 0.001. **Conclusion:** Accurate size and correct positioning of implant is essential in THA for restoration of normal biomechanics of hip joint and correction of LLD thereby providing a good functional outcome to the patient and there is a significant positive correlation between acetabular cup size and vertical offset in patients undergoing THR.

Keywords: Total Hip Arthroplasty, Avn, Acetabular Cup, Vertical Offset, Posterior Approach to Hip

Introduction

Total Hip Arthroplasty (THA) is one of the most eminent orthopedicsurgery performed and is also termed as the 'Operation of the century'^[1]. In THA, the head and proximal neck of the femur are surgically excised and the acetabular cartilage and subchondral bone are removed followed by replacement by an artificial prosthesis^[2].

THA provides reliable outcomes for patients suffering from degenerative hip osteoarthritis (OA), avascular necrosis (AVN) of the femoral head, congenital hip disorders, inflammatory arthritis. etc. It relieves pain, provides functional restoration and improves the overall quality of life^[3].

The goal of THA includes reduction in pain and restoration of normal function of the hip permitting the patient to do his/her normal activities again. THA also tries to restore the femoral head center of rotation and acetabular center of rotation as near to normal as feasible. When these centers are not restored near normal, there is a decrease in the functioning of the abductors and increased wearing of the implants^[4].

One of the major concern in THR is restoration of the lower limb length. Limb length must be restored to as much extent as possible without compromising the stability of the prosthesis. Lower Limb Length Discrepancy (LLD) following THA is one of the common source of patient dissatisfaction^[6].

Vertical offset may be defined as the perpendicular distance between the femoral head center of rotation (COR) and the medial apex of the lesser trochanter. In cases where femoral head COR could not be located, vertical offset can be considered as the perpendicular distance between a horizontal line extending from the base of the teardrop and the medial apex of the lesser trochanter^[7]. Vertical offset is an important reflector of the displacement of the femur from the pelvis^[8].

The acetabular COR undergoes a change in THA due to acetabular reaming and cup implantation. Thus, the vertical offset alone is no longer an indicator of the displacement of the femur from the pelvis and the displacement is influenced by both the vertical offset as well as the acetabular cup^[8].

The acetabulum is a cup-shaped socket which articulates with the head of the femur to form the hip joint which is a ball and socket type of joint. The name 'acetabulum' is derived from its resemblance to a shallow Roman vinegar cup. Normally the average diameter of acetabulum is 52 ± 4 mm^[9].

The size and positioning of the acetabular cup imposes a great impact on the results of THA as it affects dislocation, gait, limb length, strength of the abductors, impingement, range of motion (ROM), loosening and wearing and ultimately resulting in cup failure^[10]. Therefore, Pre-operative determination of acetabular cup size is important because if the acetabular cup size is not accurate, it may either be too loose or may not fit adequately in the acetabulum.

The acetabular cup size can be determined pre-operatively by radiographic templating using conventional X-rays after correction of the magnification error. Radiographically the acetabular cup size can be measured as the distance between the base of the teardrop and supero-lateral margin of the acetabulum after correction of the magnification error [11].

THA has an excellent 10-year survival of greater than 95% and 25-year implant survival more than 80% [1].

Methods

Pre-operative

- Informed consent taken from all the patients.
- Routine PAC blood and urine investigations, Chest X-ray and ECG were done.
- Plain X-ray pelvis with bilateral hip joints- anteroposterior view done of all the patients in the study. Acetabular cup size (distance between the base of teardrop and supero-lateral margin of the acetabulum) and vertical offset (perpendicular distance between center of rotation of femoral head and medial apex of lesser trochanter) measured using template with correction of magnification error.
- Bilateral lower limb lengths measured and lower limb length discrepancy noted.

Intra-operative

- Position of the patient: Lateral
- Incision: Hardinge approach, Southern-Moore approach.

Post-operative

- All the patients assessed post operatively for acetabular cup size and vertical offset using plain X-ray pelvis with bilateral hip joints- anteroposterior view the very next day of surgery.
- Lower limb length discrepancy measured (mean discrepancy ranges from 3 to 17 mm)[7]. Acetabular cup size and vertical offset (pre & post-operative) compared.

Surgical Technique

All the patients underwent Total Hip Arthroplasty. The hip joint and proximal femur were exposed either through anterolateral approach or posterolateral approach.

Anterolateral approach

- Straight and longitudinal incision centred over the tip of greater trochanter is given.
- Subcutaneous tissue is cut to reach fascia over posterior margin of greater trochanter.
- Fascia lata is incised to expose vastus lateralis muscle.
- There is no true internervous plane in this approach. The plane is made between tensor fascia lata and gluteus medius.
- Superior margin of joint capsule is exposed by retracting gluteus medius and minimus proximally and laterally.
- Capsule is incised and hip dislocated anteriorly by external rotation at hip joint.

Posterolateral approach

- Curved incision is given centred over the posterior aspect of greater trochanter.
- Subcutaneous tissue is cut to reach fascia.
- Fascia lata is cut to expose vastus lateralis muscle. The fibres of gluteus maximus are split very gently.
- Gluteus medius is retracted to expose the short external rotator muscles of the hip.

- These are divided close to their insertion and inverted posteriorly protecting the sciatic nerve.
- The capsule is exposed superiorly, posteriorly and inferiorly and is incised along the attachment of the femur.
- The acetabular labrum is excised and the hip dislocated posteriorly by flexing, adducting and internally rotating the hip.

Statistical analysis

Table 1: Comparison of pre and post-operative acetabular cup size (mm) of study subjects

Acetabular cup size(mm)	Mean ± SD	Median (25th-75 th percentile)	Range
Pre-operative	49.44 ± 3.4	49(47-52)	42-58
Post-operative	50.48 ± 3.53	50(48-52)	44-60
Percentage change in acetabular cup size(mm)	2.12 ± 2.01	2.13(0-3.846)	0-6.38

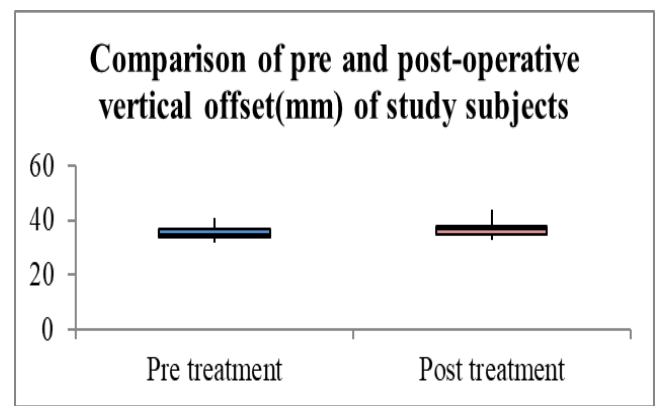


Figure 1: Comparison of pre and post-operative vertical offset (mm) of study subjects

Mean value of pre-operative, post-operative and percentage change in vertical offset(mm) of study subjects was 35.4 ± 2.18, 37.12 ± 2.6 and 4.85 ± 3.08 with median (25th-75th percentile) of 35(34-37), 37(35-38) and 5.56(2.941-7.317) respectively. Vertical offset (mm) was significantly increased from pre to post-operative. (p value<.0001)

Table 2: Correlation of percentage change in acetabular cup size (mm) and vertical offset (mm)

Variables	Correlation coefficient	P value
Acetabular cup size(mm) and vertical offset (mm)	0.893	<0.001

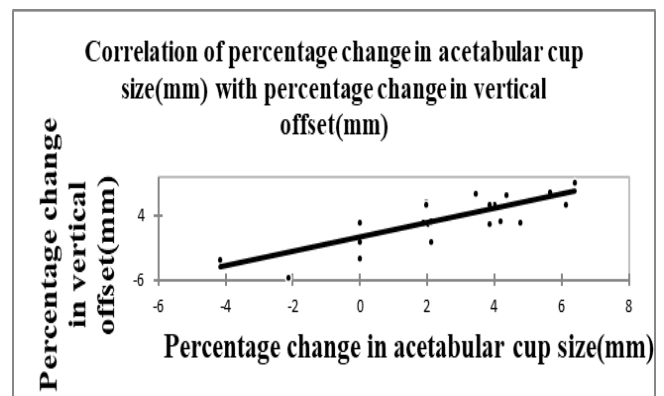


Figure 2: Correlation of percentage change in acetabular cup size (mm) with percentage change in vertical offset (mm)

Significant positive correlation was seen between percentage change in acetabular cup size (mm) with percentage change in vertical offset(mm) with correlation coefficient of 0.893 and p-value <0.001.

Result & Conclusion

- Accurate size and correct positioning of implant is essential in THA for restoration of normal biomechanics of hip joint and correction of LLD thereby providing a good functional outcome to the patient.
- Pre-operative templating helps in determining the size of the implant such as acetabular cup to be used intra-operatively.
- We were able to accurately predict the size of acetabular cup in 40% of the cases using pre-operative templating with accuracy increasing to 96% if prostheses within ± 2 mm size are included.
- Pre-operative shortening of the affected limb was seen in all the cases with pre-operative LLD being 9.36 ± 2.29 mm (mean \pm SD).
- In the present study, an increase in vertical offset was noted post-operatively with percentage change in vertical offset being 4.85 ± 3.08 mm (mean \pm SD) thereby correcting pre-operative shortening of the affected limb.
- Post-operative LLD was less than 10 mm in all the cases except one with no over lengthening found in any of the cases thus, providing an acceptable and good functional outcome to the patient.
- There is a significant positive correlation between acetabular cup size and vertical offset in patients undergoing primary THA with a correlation coefficient of 0.893 and p-value < 0.001.

Abbreviations

THA: Total Hip Arthroplasty
OA: Osteoarthritis
AVN: Avascular Necrosis
COR: Center of Rotation
ROM: Range of Motion
LLD: Lower limb Length Discrepancy
LFA: Low Frictional torque Arthroplasty
LLI: Lower limb Length Inequality
THR: Total Hip Replacement
HRA: Hip Resurfacing Arthroplasty
PMMA: Poly Methyl Mec Acrylate
PO: Pelvic Obliquity
MRI: Magnetic Resonance Imaging
PAC: Pre-Anaesthetic Check-up
SD: Standard Deviation
MM: Millimeter
CM: Centimeter
AP: Antero-posterior
ECG: Electrocardiography

Conflicts of Interest

None declared.

Funding Statement

No funds were sought from any agency

Acknowledgments

None

References

- [1] Kayani B, Pietrzak J, Donaldson MJ, Konan S, Haddad FS. Treatment of limb length discrepancy following total hip arthroplasty. *Br J Hosp Med (Lond)* 2017; 78:633–637.
- [2] Siopack JS, Jergesen HE: Total hip arthroplasty. *West J Med* 1995; 162:243-249.
- [3] Varacallo M, Luo TD, Johanson NA. Total Hip Arthroplasty Techniques. [Updated 2021 Jul 9]. In: StatPearls [Internet]. Treasure Island (FL): StatPearls Publishing; 2021 Jan.
- [4] Dastane M, Dorr LD, Tarwala R, Wan Z. Hip offset in total hip arthroplasty: quantitative measurement with navigation. *Clin OrthopRelat Res* 2011; 469:429–436.
- [5] Mahmood SS, Mukka SS, Crnalic S, Wretenberg P, Sayed-Noor AS. Association between changes in global femoral offset after total hip arthroplasty and function, quality of life, and abductor muscle strength. A prospective cohort study of 222 patients. *Acta Orthop* 2016; 87:36–41.
- [6] Flecher X, Ollivier M, Argenson JN. Lower limb length and offset in total hip arthroplasty. *OrthopTraumatolSurg Res* 2016;102(Suppl): S9-S20.
- [7] Sathappan, Santhanes & Ginat, Daniel & Patel, Vipul & Walsh, Michael & Jaffe, William & Dicesare, Paul. (2008). Effect of Anesthesia Type on Limb Length Discrepancy After Total Hip Arthroplasty. *The Journal of arthroplasty*. 23. 203-9. 10.1016/j.arth.2007.01.022.
- [8] D. Mainard, O. Barbier, Y. Knafo, R. Belleville, L. Mainard-Simard, and J.-B. Gross, "Accuracy and reproducibility of preoperative three-dimensional planning for total hip arthroplasty using biplanar low-dose radiographs: a pilot study," *Orthopaedics & Traumatology: Surgery & Research*, vol. 103, no.4, pp. 531–536, 2017.
- [9] Dr. Jawahar Mehmood Khan, Dr. Mohd Irfan Banday, Dr. Jabreel Muzaffar. A study of measurement of acetabular diameter radiologically in northern Indian population of Jammu region. *Int J Orthop Sci* 2018;4(3):78-81. DOI: 10.22271/ortho.2018.v4.i3b.16
- [10] G. Lecerf, M. H. Fessy, R. Philippot et al., "Femoral offset: anatomical concept, definition, assessment, implications for preoperative templating and hip arthroplasty," *Orthopaedics & Traumatology: Surgery & Research*, vol. 95, no. 3, pp. 210



Open Access This article is licensed under a Creative Commons Attribution 4.0 International License, which permits use, sharing, adaptation, distribution and reproduction in any medium or format, as long as you give appropriate credit to the original author(s) and the source, provide a link to the Creative Commons license, and indicate if changes were made. The images or other third-party material in this article are included in the article's Creative Commons license, unless indicated otherwise in a credit line to the material. If material is not included in the article's Creative Commons license and your intended use is not permitted by statutory regulation or exceeds the permitted use, you will need to obtain permission directly from the copyright holder. To view a copy of this license, visit <https://creativecommons.org/licenses/by/4.0/>.

© The Author(s) 2022