



# Subcutaneous Implantable Cardioverter: Defibrillator: Is the Conventional Pre-Implant Screening Enough to Assess Eligibility?

Galizia Brito Victoria \*, Falcó Martínez Teresa, Bibiloni Cladera Aina , Lozano Medina Diego, Peral Disdier Vicente , Expósito Pineda María del Carmen , Grande Morales Carlos

Fundación Instituto de Investigación Sanitaria Illes Balears (IDISBA) - Hospital Universitario Son Espases Carretera de Valldemossa 79, 07120, Palma de Mallorca, Spain

\*Corresponding author: Galizia Brito Victoria; [vgaliziabrito@gmail.com](mailto:vgaliziabrito@gmail.com) [victoria.galizia@ssib.es](mailto:victoria.galizia@ssib.es)

Received 13 December 2022;

Accepted 30 December 2022;

Published 01 January 2023

## Abstract

**Aims:** The subcutaneous implantable cardioverter-defibrillator (S-ICD) requires screening prior to implantation. Surface anatomical landmarks (SAL) guide the screening. The heart silhouette shows variations, therefore, these landmarks may differ. We aimed to determine the concordance between SAL and fluoroscopy guided screening, and analyze discordance predicting factors. **Methods:** We performed a conventional SAL guided screening (CS) in left and right parasternal electrode position (LPP/RPP) to candidates for S-ICD. Subsequently, we performed a fluoroscopy guided screening (FGS) according to cardiac silhouette. Screenings in which at least the result of one sensing vector did not coincide were considered “discordant”. A comparison was done between discordant vs. concordant cases. A simple binary logistic regression analysis was performed to assess the risk of being discordant individually for each of the variables. **Results:** The results of CS and FGS were compared in 110 patients (220 comparisons: 110 LPP and 110 RPP). 90 (40.91%) were discordant in at least one sensing vector (46 in LPP and 44 in RPP). In 3 patients (2.73%) the indication of which type of defibrillator was implanted changed according to the FGS. There were no significant differences between the discordant and concordant screening patients. **Conclusion:** There is a level of discordance between CS and FGS. There were no analyzed factors that were able to predict discordance between these two screening methods. It might be reasonable to perform FGS before implant.

**Keywords:** *defibrillator, implantable cardioverter-defibrillators, subcutaneous ICD, X-ray*

## Introduction

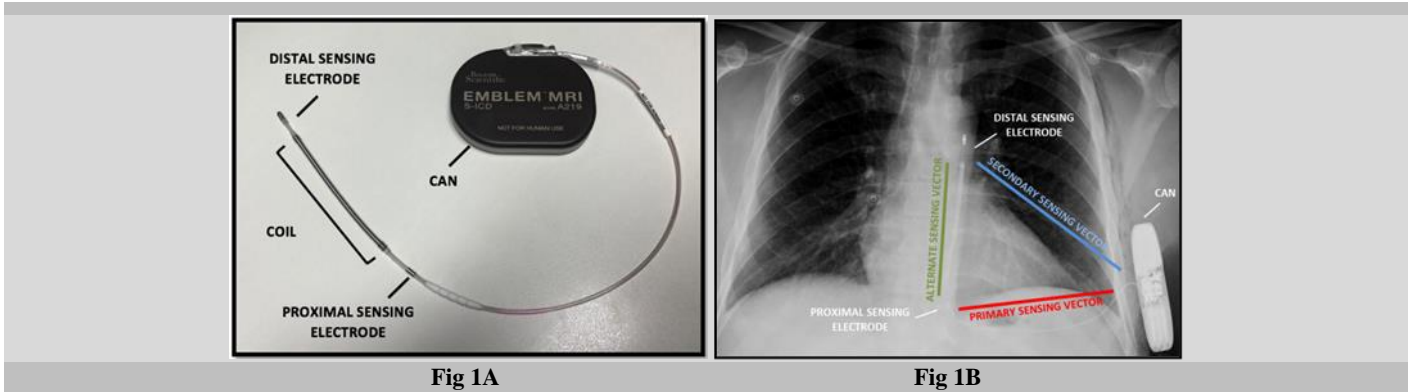
The implantable cardioverter-defibrillator (ICD) is a well-established therapy for both primary <sup>[1-3]</sup> and secondary prevention <sup>[4]</sup> of sudden cardiac death (SCD). The conventional transvenous ICD (TV-ICD) has disadvantages related to the venous access and to the leads such as: hemo/pneumothorax, cardiac effusion or tamponade, lead infection, endocarditis, future extraction associated risks, chronic lead malfunction due to endovascular mechanical stress, vein thrombosis, among others <sup>[5-8]</sup>.

The subcutaneous ICD (S-ICD) was developed to overcome these limitations, avoiding vascular access completely <sup>[9]</sup>. The S-ICD has emerged as an attractive alternative to TV-ICD in a selected group of patients (e.g. young patients, after device infection, difficult venous access, arrhythmogenic syndromes) and made its way into clinical practice guidelines <sup>[10-11]</sup>.

Pivotal studies evaluating this device developed over the past years have proven its safety and efficacy in detecting and terminating induced and spontaneous ventricular arrhythmias <sup>[12-15]</sup>.

Several studies compared the S-ICD to the traditional TV-ICD, showing lower complication rates (predominantly related to lead failures) in patients receiving an S-ICD, no differences in terms of major complications and death <sup>[16]</sup>, similar improvement in patients' quality of life <sup>[17]</sup> as well as comparable rates of appropriate and inappropriate shocks <sup>[18]</sup>. One study in particular, showed higher costs with the use of TV-ICD, due to complications <sup>[19]</sup>.

The current S-ICD (Emblem® MRI S-ICD A219 model - Boston Scientific) uses a morphology-based algorithm that relies on subcutaneous rather than endocardial electrogram sensing <sup>[12]</sup>. The lead has a proximal and a distal sensing electrode (on both sides of the 8-cm shock coil). The S-ICD system detects cardiac rhythm between the two sensing electrodes or from either of them and the can [Fig 1A]. Consequently, it can construct three possible sensing vectors: primary vector (horizontally between the proximal sensing electrode and can), secondary vector (diagonally between the distal sensing electrode and can), and alternate vector (vertically between the distal and proximal sensing electrodes) [Fig 1B].



Taking this into account, in order to assess eligibility of patients for S-ICD implant, and avoid implantation in patients who are susceptible to sensing problems and inappropriate shocks in the future, the manufacturer recommends pre-implant screening.

Screening can be done with the manual and/or automatic screening tool, positioning surface electrodes in the locations resembling the implanted S-ICD system sensing electrodes intended position (simulating the aforementioned sensing vectors).

This screening will determine whether there is suitable sensing for rhythm identification and therapy delivery. This is why, only carefully selected patients who undergo and pass this pre-implant screening should be deemed candidates for S-ICD implant [20].

It is important to note that the screening is done by positioning electrodes guided by surface anatomical landmarks (SAL) [21] but the anatomy and position of the heart is not the same in every patient. The geometric position of the heart varies largely from patient to patient [22] and anatomical structures underneath bones may differ among healthy individuals with variations of thoracic anatomy [23].

Hence, both pre-implant screening surface electrodes position, as well as the S-ICD system definitive position may and probably should vary depending on actual heart position in each individual patient.

To our knowledge, there is only one published study evaluating fluoroscopy guided pre-implant S-ICD screening: a case report in which this technique increased eligibility for S-ICD in one patient [24].

The aim of this study was to investigate the concordance between conventional screening (CS) and fluoroscopy guided screening (FGS). We analyzed discordance predictor factors between the two screening methods.

## Materials & Methods

### Patient selection and screening

Once a patient was considered a potential candidate for S-ICD implantation in accordance with clinical practice guidelines [10-11], a CS was performed. CS was done positioning the electrodes in left parasternal position (LPP) and right parasternal position (RPP), both in supine and sitting/standing posture, according to manufacturer

User's Manual [25]: the left arm electrode (LA) 1 cm lateral (left for LPP or right for RPP) to the xiphoid midline, the right arm electrode (RA) 14 cm cranially from the LA along the parasternal line, and left leg electrode (LL) at mid-axillary line at 5th intercostal space.

Once in the operating room, prior to the sterile draping process for device implantation, an S-ICD demonstration system was positioned and secured by adhesive tape on the patient's chest [Fig 2A]. The position was checked by fluoroscopy (and afterwards repositioned if needed) to fit the cardiac silhouette in the simulated defibrillation vector [Fig 2B]. Once this was achieved, the system position was drawn onto the patient's chest with a marker [Fig 2C]. Subsequently, surface electrodes were positioned to match proximal and distal sensing electrodes and the can intended position and therefore perform the FGS [Fig 2D].

An operator using suitable radiation protection performed the above mentioned few seconds of fluoroscopy. The staff members rotated for each patient, as a way to contribute to reducing individual radiation exposure. We aimed to minimize radiation as low as reasonable achievable, by using low frame rate per second, optimal collimation, minimal magnification and fluoroscopy instead of cinefluorographic acquisition, and by decreasing the distance between patient and detector. We performed a few seconds of fluoroscopy once again at the end of the implant procedure to confirm the final position.

Patients were considered appropriate candidates for S-ICD and implant was done following the previously drawn demonstration device landmarks, if all of the following conditions were met after FGS:

- At least one sensing vector was acceptable in supine and standing/sitting postures.
- QRS morphology stable and with no significant change across postures.

Those patients who did not meet these criteria in the FGS, received a conventional TV-ICD.

In every screening, each sensing vector was classified as ACCEPTABLE if it passed both in supine and sitting/standing posture, and FAIL if it did not (in either of the two postures).

We then compared the results of the CS vs. the FGS both in LPP and RPP.

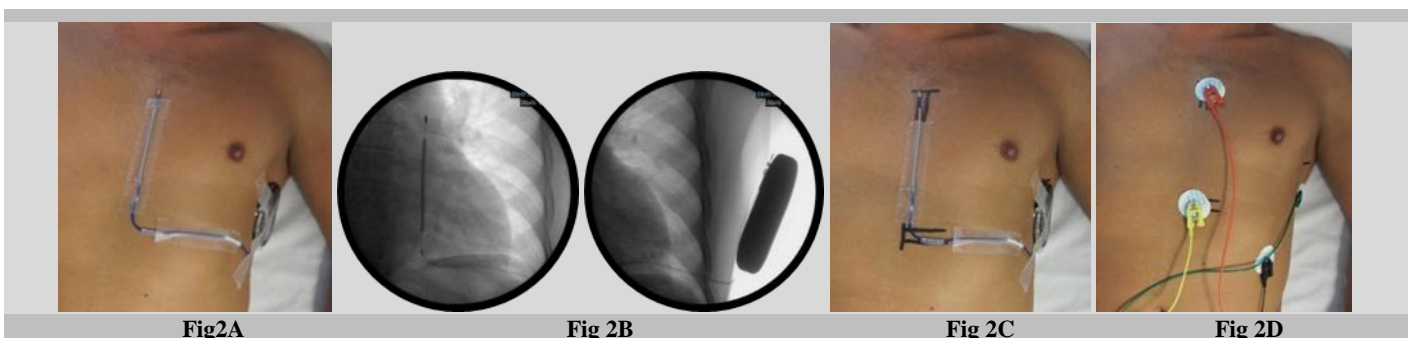


Fig 2: Step by step of the fluoroscopy guided screening.

## Statistical Analysis

We performed a descriptive analysis of all documented variables to define the characteristics with frequencies and percentages for qualitative variables and with measure of central position and dispersion for quantitative variables. In the case of normal distribution, variables were expressed as mean ± standard deviation (SD) and in the case of non-normal distribution with median and interquartile range (Pc25-75).

We compared CS vs FGS: if there was one discordant result in any sense vector (primary/secondary/alternate) the screenings were considered DISCORDANT. Screening results with matching results in all three vectors were considered CONCORDANT.

We compared patient characteristics in the two groups: DISCORDANT cases vs. CONCORDANT cases both in RPP and LPP. To analyze the differences between them, the chi-square test or Fisher's exact test was used for the qualitative variables and the Man-Whitney U test or the Student's T test for the quantitative variables according to their distribution. At the same time, a simple binary logistic regression analysis was carried out to evaluate the advantages or disadvantages that each of the variables can individually grant on whether or not to obtain a discordant result. A p value <0.05 and p <0.10 was considered an indicator of a significant difference; this level was not obtained in any case. SPSS was the statistical software used for the analysis (Statistical Package for the Social Sciences [SPSS Statistics for Windows], Version 19.0., IBM Corp., Armonk, NY, USA).

Our study was carried out in accordance with internationally accepted recommendations for clinical investigation (Declaration of Helsinki of the World Medical Association, revised October 2013).

## Results

We included 110 consecutive patients who were potential candidates for S-ICD and underwent screening between June 2017 and May 2021. Results for the primary, secondary and alternate sensing vectors obtained in the CS and the FGS of 110 patients were analyzed separately, resulting in 220 comparisons (110 in LPP and 110 in RPP). 90 comparisons (40.91%) were discordant in at least one vector: 46 (41.8%) in LPP and 44 (40%) in RPP. The alternate sensing vector was the most discordant (n=39 17.73%), followed by the secondary vector (n=29 13.18%) and the primary vector (n=22 10%) [Table 1].

In 3 patients (2.73%) the indication of the type of ICD changed according to the FGS result.

There were no differences in patient characteristics with discordant and concordant screening results [Table 2].

There were no patients with congenital heart disease and therefore, we were not able to include this factor in our analysis.

Overall, there were no statistically significant differences obtained between the two groups and there were no independent predictors of discordance [Table 3].

Regarding radiation exposure data: mean fluoroscopy time was 3.91±0.82 seconds and mean effective dose was 0.049±0.08mSv.

**Table 1. Discordant results in each sensing vector and parasternal electrode position**

	Primary	Secondary	Alternate	Total
LPP	9	14	23	46/110 (41.8%)
RPP	13	15	16	44/110 (40%)
Total	22/220 (10%)	29/220 (13.18%)	39/220 (17.73%)	90/220 (40.91%)

**Table 2. Comparison of concordant and discordant cases**

	LPP			RPP		
	Concordant	Discordant	p	Concordant	Discordant	p
	N=64	N=46		N=66	N=44	
Age (years), median (Pc25-75)	52 (39-58)	51 (42.5-58)	0.53	51 (41.5-57)	52 (39-60)	0.21
Male, n (%)	55 (85.9%)	31 (67.4%)	0.11	53 (80.3%)	33 (75%)	0.15
Body mass index (BMI), median (Pc25-75)	26.44 (24.1-29.4)	24.6 (22.9-28.2)	0.4	25.9 (23.1-28.4)	23.4 (24.1-29)	0.73
Obesity (BMI≥30), n (%)	12 (18.7%)	6 (13.1%)	1	11 (16.6%)	7 (15.9%)	1
Height (cm), mean ±SD	170.6 ± 8.4	171.1 ± 9.2	0.9	170.7 ± 9.3	170.9 ± 9.6	0.74
Taller than mean height, n (%)	35 (54.7%)	24 (52.2%)	0.8	31 (48.5%)	23 (52.2%)	0.62
Chest deformity, n (%)	2 (3.1%)	1 (2.2%)	0.87	2 (3.03%)	1 (2.3%)	0.92
LV ejection fraction (%), median (Pc25-75)	35 (28-62)	30 (26-59)	0.6	33 (28-55)	24.5 (28-60)	0.51
RV dilation, n (%)	7 (10.9%)	5 (10.8%)	1	8 (12.1%)	5 (11.3%)	0.71
LV dilation, n (%)	35 (54.7%)	22 (47.8%)	0.6	30 (45.4%)	19 (43.2%)	0.81
Ischemic cardiomyopathy, n (%)	31 (48.4%)	23 (50%)	0.47	31 (46.9%)	23 (52.0%)	1
Hypertrophic cardiomyopathy, n (%)	10 (15.6%)	5 (10.8%)	1	8 (12.1%)	5 (11.4%)	0.44
Idiopathic dilated cardiomyopathy, n (%)	6 (9.4%)	5 (10.8%)	1	6 (9.1%)	5 (11.4%)	0.69
History of cardiothoracic surgery, n (%)	5 (7.8%)	2 (4.3%)	1	4 (6.1%)	3 (6.8%)	0.65

**Table 3: Odds Ratio of obtaining a discordant result for each variable**

	Discordant result			
	LPP		RPP	
	OR (95% CI)	p	OR (95% CI)	P
Age	0.98 (0.95 – 1.02)	0.41	0.97 (0.93 – 1.01)	0.07
Male gender	0.40 (0.14 – 1.21)	0.11	0.42 (0.14 – 1.26)	0.12
Body mass index (BMI)	0.95 (0.85 – 1.06)	0.34	1.01 (0.91 – 1.21)	0.89
Obesity (BMI≥30)	0.87 (0.25 – 3.1)	0.83	0.93 (0.25 – 3.45)	0.91
Height	1.03 (0.98 – 1.09)	0.24	0.98 (0.93 – 1.04)	0.45
Higher than mean height	1.16 (0.46 – 2.96)	0.75	1.44 (0.54 – 3.84)	0.47
LVEF	0.99 (0.97 – 1.02)	0.73	1.01 (0.99 – 1.04)	0.32
LV dilation	0.72 (0.28 – 1.85)	0.49	0.81 (0.31 – 2.15)	0.67

Ischemic cardiomyopathy	0.66 (0.26 – 1.71)	0.39	1.06 (0.39 – 2.82)	0.91
Hypertrophic cardiomyopathy	1.29 (0.29 – 5.6)	0.74	2.05 (0.47 – 9.01)	0.34
Idiopathic dilated cardiomyopathy	0.93 (0.19 – 4.49)	0.93	1.47 (0.3 – 7.14)	0.64
History of cardiothoracic surgery	0.82 (0.13 – 5.24)	0.84	0.45 (0.05 – 4.24)	0.49

## Discussion

To our knowledge, this is the first study comparing the results between pre-implant CS vs FGS. We found an overall 40.91% discordance between CS and FGS. The sensing vector that showed more discordant results was the alternate, followed by the secondary (thus the most discordant were those involving the distal sensing electrode). In our study, FGS changed the device type indication, although this happened in a small number of patients. Patients with concordant versus discordant screening results did not show significant clinical characteristics differences; therefore, we did not find any discordance predicting factor.

Although the use of x-ray is not strictly required for the S-ICD implant, fluoroscopy can be used to confirm the system position [26]. To our knowledge, there is only one case report in the literature mentioning FGS [24]. This report describes the case of a patient with high risk of prosthetic valve infective endocarditis with a negative result in the CS. Performing a modified FGS made him eligible for the therapy. While the possibility of implanting the device with no exposure to radiation is actually one attractive feature of the S-ICD, there are a number of studies that mention performing a few seconds of fluoroscopy during the procedure. In the pivotal study by Bardy et al. [12] the S-ICD was implanted and its position was observed under fluoroscopy after de pocket was closed and only after testing was complete. In one patient, the device failed to terminate the induced VF at maximum output and the subsequent fluoroscopy image showed the electrode was malpositioned laterally, with the electrode coil outside the left lateral margin of the cardiac silhouette. Subsequently, there have been reports of fluoroscopy done after a failed defibrillation threshold testing at high output, accounted for by the mass of ventricle in between the defibrillation vector not being optimized due to migration of the electrode [27-29].

Other studies used a brief time of fluoroscopy before prepping, placing a demonstration device on the patients' chest to guide the incisions and assure a good defibrillator vector [30-32]. Some studies mention using fluoroscopy to determine incision site to position the lead and pulse generator in the best position relative to the heart silhouette [33-34].

Patients with congenital heart disease (CHD) can have unusual cardiac geometry [35] and therefore make it particularly challenging to obtain adequate shock and sensing vectors. In these situations, there are authors describing the use short sequences of fluoroscopy to secure the exact electrode and can placement, implanting them in non-standard positions [28,31]. Indeed, there are a few observational studies in patients with CHD and dextrocardia showing that locating the can in the right lateral chest wall is feasible and effective [36-39]. In contrast, adults with CHD tend to have larger hearts, located more centrally in the thorax (usually larger right chambers). A study described lack of variation in the R and T wave amplitude as well as the R:T ratio when measuring from the LPP and RPP [40]. We observed a tendency to less discordance (although non-significant) between the CS and FGS, in patients with dilated hearts in general: in these patients the heart is larger and this might result in surface signals not being substantially modified in diverse locations on the chest. Patients with dilated cardiomyopathy often have bundle branch block and suffer from symptomatic heart failure, so they are frequently candidates to cardiac resynchronization therapy: we believe this accounts for the low proportion of these patients in our study.

Regarding patients with previous history of thoracic surgery, a successful S-ICD implant was described in a patient with

dextrocardia secondary to lobectomy, highlighting the importance of examining the cardiac position in a chest X-ray when planning the procedure [41].

Chest deformity, particularly in pectus excavatum, is a concern that might limit the use of S-ICD, as it may be challenging to place the electrode parallel to sternum due to the concavity. There are several case reports that describe standard implant with no incidences in these patients [42-44]. Nevertheless, in severe cases, sternal depression may result in cardiac compression (particularly right cardiac chambers) and lead to morphological and functional alterations such as leftward displacement [45-48]. In our study there were a very small number of patients with congenital chest abnormalities and thus, we were not able to come to any conclusion on this particular factor.

Unusually large body sizes can determine challenging circumstances as well. There is one published study that described an S-ICD implant in a very tall patient in which a very short sequence of fluoroscopy to delineate the inferior and lateral border of the heart resulted useful. This led to a more cranial final location of the electrode [49].

Patients with extreme body mass index (BMI) (above or beyond the median) are challenging scenarios as well, but we did not find any significant difference between different BMI patients.

Regarding patients with hypertrophic cardiomyopathy, there was one study that described an atypical position of the S-ICD as a solution in patients with initially negative screening. The ECG screening was repeated for the S-ICD pulse generator placed more dorsally and the lead in RPP and one vector was deemed acceptable [50]. Based on that case, the same study group described that the alternative placement of screening surface electrodes (precordial electrodes shifted to rightwards and lateral electrode dorsally) could be a valuable method to increase eligibility for the S-ICD in these patients, consequently implanting the S-ICD system according to the alternative screening landmarks [51].

Although screening done by SAL is recommended by the manufacturer, these unusual situations underline the need to adapt the implant location (at least slightly) individually to each patient's body and heart structure.

As radiation exposure is a major concern for interventional physicians, nowadays, the strive to achieve near-zero or even zero fluoroscopy interventional procedures has become increasingly popular. Consequently, the possibility of performing an ICD implant without using x-ray is certainly an attractive attribute of the S-ICD. Despite the fact that suggesting the use of fluoroscopy when it is not absolutely necessary seems unreasonable, the radiation doses used in our study were remarkably low (mean effective dose of 0.049mSv), considering that for TV-ICD implantation, the median radiation dose is 4mSv (1.4-17mSv), increasing to 22mSv (2.2-95mSv) for CRT implants [52]. All operators aimed to minimize the radiation as low as reasonable achievable, following recommendations of the major cardiovascular societies [53-55].

There are a number of limitations to this study. Firstly, although the databased was completed prospectively, this is a retrospective analysis and therefore there is an inherent risk of selection bias. Secondly, the relatively small number of investigated patients. And last but not least, we did not perform systematic screening to every patient who was candidate for ICD, just to those who were considered adequate candidates for the S-ICD.

*Our study has an important clinical implication:* performing a modified pre-implant screening can change the ICD indication. The definitive S-ICD system position may and certainly should vary

depending on the actual position of the heart in each individual patient.

## Conclusion

There is a level of discordance between CS and FGS according to the position of the cardiac silhouette as observed under fluoroscopy. There were no analyzed factors that were able to predict discordance between these two screening methods. In three patients, FGS led to a different device indication. It might be reasonable to perform FGS before implant.

## Key Points

### What do we know?

Patients must undergo pre-implant EKG screening in order to assess eligibility for S-ICD and to avoid implantation in those patients who are susceptible to sensing issues and inappropriate shocks. The conventional screening is guided by surface anatomical landmarks.

### What's new?

The position of the S-ICD can be different from patient to patient, to obtain an adequate shock vector. We present a technique to perform pre-implant screening guided by the cardiac silhouette as seen under fluoroscopy. The FGS has a level of discordance with the CS.

## List of abbreviations

S-ICD: Subcutaneous implantable cardioverter-defibrillator  
SAL: Surface anatomical landmarks  
CS: Conventional screening  
LPP: Left parasternal electrode position  
RPP: Right parasternal electrode position  
FGS: Fluoroscopy guided screening  
ICD: Implantable cardioverter-defibrillator  
TV-ICD: transvenous implantable cardioverter-defibrillator  
LA: Left arm electrode  
RA: Right arm electrode  
LL: Left leg electrode

## Declarations

## Ethics approval and consent to participate

The research was approved by the ethics committee. Patients signed written consent before procedure.

## Sources of funding

The research did not receive any specific grant from funding agencies in the public, commercial, or not-for-profit sectors.

## Conflict of interest

CGM and MEP have received honoraria for proctoring from Boston Scientific. Other authors: no disclosures.

## Data availability

The authors confirm that the data supporting the findings of this study are available upon request.

## Authors' contributions

All authors collaborated in the conception and design of the research. VGB collected and analyzed the data and wrote the first draft. VGB, CGM and MEP edited the paper and all authors read and approved the final manuscript.

## References

- [1] Moss A, Hall W, Cannom D, et al. Improved Survival with an Implanted Defibrillator in Patients with Coronary Disease at High Risk for Ventricular Arrhythmia. *N. Engl. J. Med.* 1996;335(26):1933-1940.
- [2] Moss A, Cannom D, Daubert J, et al. Multicenter Automatic Defibrillator Implantation Trial II (MADIT II): Design and Clinical Protocol. *Ann Noninvas Electro.* 1999;4(1):83-91.
- [3] Bardy G, Lee K, Mark D, et al. Amiodarone or an Implantable Cardioverter-Defibrillator for Congestive Heart Failure. *N. Engl. J. Med.* 2005;352(3):225-237.
- [4] Connolly S, Hallstrom A, Cappato R, et al. Meta-analysis of the implantable cardioverter defibrillator secondary prevention trials. *Eur. Heart J.* 2000;21(24):2071-2078.
- [5] Van Rees J, de Bie M, Thijssen J, et al. Implantation-Related Complications of Implantable Cardioverter-Defibrillators and Cardiac Resynchronization Therapy Devices. *J. Am. Coll. Cardiol.* 2011;58(10):995-1000.
- [6] Kleemann T, Becker T, Doenges K, et al. Annual Rate of Transvenous Defibrillation Lead Defects in Implantable Cardioverter-Defibrillators Over a Period of >10 Years. *Circ.* 2007;115(19):2474-2480.
- [7] Olde Nordkamp L, Postema P, Knops R, et al. Implantable cardioverter-defibrillator harm in young patients with inherited arrhythmia syndromes: A systematic review and meta-analysis of inappropriate shocks and complications. *Heart Rhythm.* 2016;13(2):443-454.
- [8] Ezzat V, Lee V, Ahsan S, et al. A systematic review of ICD complications in randomised controlled trials versus registries: is our 'real-world' data an underestimation?. *Open Heart.* 2015;2(1):e000198.
- [9] Al-Khatib S, Friedman P, Ellenbogen K. Defibrillators: selecting the right device for the right patient. *Circ.* 2016;134(18):1390-1404.
- [10] Priori S, Blomström-Lundqvist C, Mazzanti A, et al. 2015 ESC Guidelines for the management of patients with ventricular arrhythmias and the prevention of sudden cardiac death: The Task Force for the Management of Patients with Ventricular Arrhythmias and the Prevention of Sudden Cardiac Death of the European Society of Cardiology (ESC). *Eur. Heart J.* 2015;36(41):2793-2867.
- [11] Al-Khatib S, Stevenson W, Ackerman M, et al. 2017 AHA/ACC/HRS Guideline for Management of Patients with Ventricular Arrhythmias and the Prevention of Sudden Cardiac Death: A Report of the American College of Cardiology/American Heart Association Task Force on Clinical Practice Guidelines and the Heart Rhythm Society. *Circ.* 2018 Oct; 15(10):e73-e189.
- [12] Bardy G, Smith W, Hood M, et al. An Entirely Subcutaneous Implantable Cardioverter-Defibrillator. *N. Engl. J. Med.* 2010;363(1):36-44.
- [13] Aziz S, Leon A, El-Chami M. The Subcutaneous Defibrillator. *J. Am. Coll. Cardiol.* 2014;63(15):1473-1479.
- [14] Gold M, Theuns D, Knight B, et al. Head-To-Head Comparison of Arrhythmia Discrimination Performance of Subcutaneous and Transvenous ICD Arrhythmia Detection Algorithms: The START Study. *J. Cardiovasc. Electrophysiol.* 2011;23(4):359-366.
- [15] Theuns D, Brouwer T, Jones P, et al. Prospective blinded evaluation of a novel sensing methodology designed to reduce inappropriate shocks by the subcutaneous implantable cardioverter-defibrillator. *Heart Rhythm.* 2018;15(10):1515-1522.
- [16] Mithani AA, Kath H, Hunter K, et al. Characteristics and early clinical outcomes of patients undergoing totally subcutaneous vs. transvenous single chamber implantable

- cardioverter defibrillator placement. *Europace* 2018;20:308–14.
- [17] Pedersen S, Mastenbroek M, Carter N, et al. A Comparison of the Quality of Life of Patients with an Entirely Subcutaneous Implantable Defibrillator System Versus a Transvenous System (from the EFFORTLESS S-ICD Quality of Life Substudy). *The American Journal of Cardiology*. 2016;118(4):520-526.
- [18] Brouwer TF, Yilmaz D, Lindeboom R, et al. Long-term clinical outcomes of subcutaneous versus transvenous implantable defibrillator therapy. *J. Am. Coll. Cardiol.* 2016;68:2047–55.
- [19] Honarbakhsh S, Providencia R, Srinivasan N, et al. A propensity matched case-control study comparing efficacy, safety and costs of the subcutaneous vs. transvenous implantable cardioverter defibrillator. *Int. J. Cardiol.* 2017;228:280–5.
- [20] Poole JE, Gold MR. Who Should Receive the Subcutaneous Implanted Defibrillator?. *Circ. Arrhythm Electrophysiol.* 2013;6(6):1236-1245.
- [21] Boston Scientific. EMBLEMTM S-ICD Automatic Screening Tool (AST). Instructions for use. 2015. Available at: [https://www.bostonscientific.com/content/dam/Manuals/us/current-rev-en/360195-001\\_AST\\_IFU\\_multi-GLOBAL\\_S.pdf](https://www.bostonscientific.com/content/dam/Manuals/us/current-rev-en/360195-001_AST_IFU_multi-GLOBAL_S.pdf). Accessed December 10th, 2021.
- [22] MacLeod RS, Ni Q, Punske B, Ershler PR, et al. Effects of heart position on the body-surface electrocardiogram. *J. Electrocardiol.* 2000; 33(Suppl 1):229–237.
- [23] Papadimitriou P, Chalkias A, Mastrokostopoulos A, et al. Anatomical structures underneath the sternum in healthy adults and implications for chest compressions. *Am. J. Emerg. Med.* 2013;31(3):549-555.
- [24] Galizia Brito V, Bibiloni Cladera A, Exposito Pineda M, et al. Pre-implant screening guided by cardiac silhouette fluoroscopy: a way to increase eligibility for the subcutaneous implantable cardioverter-defibrillator: a case report. *Eur. Heart J. Case Rep.* 2020;5(1).
- [25] Boston Scientific. USERS’S MANUAL. EMBLEMTM S-ICD, EMBLEMTM MRI S-ICD. SUBCUTANEOUS IMPLANTABLE CARDIOVERTER DEFIBRILLATOR. REF A209, A219. 2015. Available at: [https://www.bostonscientific.com/content/dam/bostonscientific/Rhythm%20Management/portfolio-group/EMBLEM\\_S-ICD/Download\\_Center/359481-001%20EMBLEM%20S-ICD%20PTM\\_English.pdf](https://www.bostonscientific.com/content/dam/bostonscientific/Rhythm%20Management/portfolio-group/EMBLEM_S-ICD/Download_Center/359481-001%20EMBLEM%20S-ICD%20PTM_English.pdf). Accessed December 10th, 2021.
- [26] Ali H, Lupo P, Cappato R. The Entirely Subcutaneous Defibrillator – A New Generation and Future Expectations. *Arrhythm Electrophysiol Rev.* 2015;04(2):116.
- [27] Levine JD, Ellins C, Winn N, et al. Failed maximal defibrillation threshold testing in the subcutaneous implantable cardioverter defibrillator. *Cardiology.* 2016;136(1):29-32.
- [28] Peters B, Will A, Berger F, et al. Implantation of a fully subcutaneous ICD in a patient with single ventricle morphology and Eisenmenger physiology. *Acta Cardiol.* 2012;67(4):473-5.
- [29] Levine J, Ellins C, Winn N, et al. Failed Maximal Defibrillation Threshold Testing in the Subcutaneous Implantable Cardioverter Defibrillator. *Cardiology.* 2016;136(1):29-32.
- [30] Al-Ghamdi B, Shafquat A, Alruwaili N, et al. Subcutaneous Implantable Cardioverter Defibrillators Implantation Without Defibrillation Threshold Testing: A Single Center Experience. *Cardiol Res.* 2017;8(6):319-326.
- [31] Ferrero P, Ali H, Barman P, et al. Entirely subcutaneous defibrillator and complex congenital heart disease: Data on long-term clinical follow-up. *World J. Cardiol.* 2017;9(6):547.
- [32] Ferrari P, Giofrè F, De Filippo P. Intermuscular pocket for subcutaneous implantable cardioverter defibrillator: Single-center experience. *J Arrhythmia.* 2016;32(3):223-226.
- [33] Kempa M, Budrejko S, Raczak G. Subcutaneous implantable cardioverter-defibrillator (S-ICD) for secondary prevention of sudden cardiac death. *Arch. Med. Sci.* 2016;5:1179-1180.
- [34] Migliore F, Mattesi G, Franceschi P, et al. Multicentre experience with the second-generation subcutaneous implantable cardioverter defibrillator and the intermuscular two-incision implantation technique. *J. Cardiovasc. Electrophysiol.* 2019;30(6):854-864.
- [35] Moore J, Mondésert B, Lloyd M, et al. Clinical Experience with the Subcutaneous Implantable Cardioverter–Defibrillator in Adults With Congenital Heart Disease. *Circ. Arrhythm Electrophysiol.* 2016;9(9).
- [36] Ceresnak S, Motonaga K, Rogers I, et al. Right-sided subcutaneous implantable cardioverter-defibrillator placement in a patient with dextrocardia, tetralogy of Fallot, and conduction disease. *Heart Rhythm Case Reports.* 2015;1(4):186-189.
- [37] Al-Ghamdi B. Right-Sided Subcutaneous Implantable Cardioverter Defibrillator System Implantation in a Patient with Complex Congenital Heart Disease and Dextrocardia: A Case Report and Literature Review. *Case Rep. Cardiol.* 2019;2019:1-6.
- [38] Waller J, Salmon A, Roberts P. A right-sided subcutaneous implantable cardioverter defibrillator in a patient with congenital heart disease. *EP Europace.* 2014;17(1):77-77.
- [39] Van Opstal J, Blaauw Y, Pison L. A Completely Subcutaneous Implantable Cardioverter Defibrillator in a Patient With Situs Inversus Totalis. *J. Cardiovasc. Electrophysiol.* 2011;23(3):333-333.
- [40] Wilson D, Zeb M, Veldtman G, et al. Left and Right Parasternal Sensing for the S-ICD in Adult Congenital Heart Disease Patients and Normal Controls. *Pacing Clin Electrophysiol.* 2016;39(3):282-290.
- [41] Monkhouse C, Koutsogeorgis I, Schilling R, et al. Subcutaneous implantable defibrillator in dextrocardia secondary to Lobectomy. *Clin. Case Rep.* 2018;6(9):1727-1729.
- [42] Hamoud A, Barry J. Subcutaneous Implantable Cardioverter Defibrillator in a Patient with Pectus Excavatum. *Pacing Clin Electrophysiol.* 2012;36(5):e138-e139.
- [43] Karvouni E, Zografos T, Winter J, et al. Successful implantation of subcutaneous implantable cardioverter-defibrillator in a patient with severe pectus excavatum. *EP Europace.* 2018;20(11):1848.
- [44] Osca J, Cano Ó, Izquierdo M, et al. Feasibility of a subcutaneous implantable cardioverter-defibrillator in a patient with pectus excavatum. *Rev Esp Cardiol.* 2020;73(1):92-94.
- [45] Rodriguez-Granillo G, Raggio IM, Deviggiano A, et al. Impact of pectus excavatum on cardiac morphology and function according to the site of maximum compression: effect of physical exertion and respiratory cycle. *Eur. Heart J. Cardiovasc Imaging.* 2019;21(1):77-84.

- [46] Velazco C, Pulivarthi V, Arsanjani R, et al. Cardiopulmonary Function in Thoracic Wall Deformities: What Do We Really Know?. *Eur. J. Pediatr. Surg.* 2018;28(04):327-346.
- [47] Abu-Tair T, Turial S, Hess M, et al. Impact of Pectus Excavatum on Cardiopulmonary Function. *Ann. Thorac. Surg.* 2018;105(2):455-460.
- [48] Oezcan S, Attenhofer Jost CH, Pfyffer M, et al. Pectus excavatum: echocardiography and cardiac MRI reveal frequent pericardial effusion and right-sided heart anomalies. *Eur. Heart J. Cardiovasc. Imaging.* 2012;13:673-679.
- [49] Peters B, Will A, Berger F, et al. Implantation of a fully subcutaneous ICD in a patient with single ventricle morphology and Eisenmenger physiology. *Acta Cardiol.* 2012;67:473-475.
- [50] Kaczmarek K, Winter J, Wranicz J, et al. Atypical position of subcutaneous implantable cardioverter-defibrillator as a solution in hypertrophic cardiomyopathy patient with initially negative electrocardiographic screening. *Eur. Heart J.* 2015;36(37):2542-2542.
- [51] Kaczmarek K, Kałowski M, Krzysztof Wranicz J, et al. Conventional and alternative preimplantation ECG screening for subcutaneous ICD in high risk hypertrophic cardiomyopathy patients. *J. Electrocardiol.* 2020;58:68-73.
- [52] Heidebuechel H, Wittkamp FHM, Vano E, et al. Practical ways to reduce radiation dose for patients and staff during device implantations and electrophysiological procedures. *EP Europace.* 2014;16(7):946-964.
- [53] Picano E, Vano E, Rehani M, et al. The appropriate and justified use of medical radiation in cardiovascular imaging: a position document of the ESC Associations of Cardiovascular Imaging, Percutaneous Cardiovascular Interventions and Electrophysiology. *Eur. Heart J.* 2014;35(10):665-672.
- [54] Fazel R, Gerber T, Balter S, et al. Approaches to Enhancing Radiation Safety in Cardiovascular Imaging. *Circ.* 2014;130(19):1730-1748.
- [55] Hirshfeld J, Ferrari V, Bengel F, et al. 2018 ACC/HRS/NASCI/SCAI/SCCT Expert Consensus Document on Optimal Use of Ionizing Radiation in Cardiovascular Imaging—Best Practices for Safety and Effectiveness, Part 1: Radiation Physics and Radiation Biology. *J. Am. Coll. Cardiol.* 2018;71(24):2811-2828.



Open Access This article is licensed under a Creative Commons Attribution 4.0 International License, which permits use, sharing, adaptation, distribution and reproduction in any medium or format, as long as you give appropriate credit to the original author(s) and the source, provide a link to the Creative Commons license, and indicate if changes were made. The images or other third-party material in this article are included in the article's Creative Commons license, unless indicated otherwise in a credit line to the material. If material is not included in the article's Creative Commons license and your intended use is not permitted by statutory regulation or exceeds the permitted use, you will need to obtain permission directly from the copyright holder. To view a copy of this license, visit <https://creativecommons.org/licenses/by/4.0/>.

© The Author(s) 2023