



Ultrasound Guided Cervical Plexus Block for Parathyroidectomy-Our First Experiences

Marina Stojanovic^{1,2,3}, Anka Toskovic^{2,3}, Irena Mojsic^{2,3}, Milan Jovanovic^{1,3}, Goran Zoric³,
Bozidar Odalovic^{3,4}, Nikola Slijepcevic^{1,3}, Katarina Tausanovic^{1,3}, Branislav Rovcanin^{1,3}, Matija Buzejic³,
Duska Vucen³, Boban Stepanovic³, Vladan Zivaljevic^{1,3}

¹Medical Faculty, University of Belgrade, Belgrade, Serbia.

²Centre of Anaesthesia and Resuscitation, University Clinical Centre of Serbia, Belgrade, Serbia.

³Clinic for Endocrine Surgery, University Clinical Centre of Serbia, Belgrade, Serbia.

⁴Faculty of Medicine Pristina/K. Mitrovica, University of Pristina/K. Mitrovica, K. Mitrovica, Serbia.

*Corresponding author: Marina Stojanovic; marinailicstojanovic@gmail.com

Received 22 February 2023;

Accepted 16 March 2023;

Published 19 March 2023

Abstract

Ultrasound guided Cervical Plexus Block (CPB) is a technique that has been applied in parathyroid surgery. Main advantages of ultrasound technique include a direct view of nerves; local anaesthetic (LA) spreading during injection; reduced volume of LA; blood vessels and other structures injury is significantly reduced. It is especially useful in patients with serious comorbidities, in which possible peri-operative consequences and risks of general anaesthesia can be avoided. Based on our first results of the presented cases, we can say that superficial CPB is a safe and simple procedure in order to provide perioperative analgesia in parathyroid surgery.

Keywords: *parathyroidectomy, regional anaesthesia, ultrasound.*

Introduction

Primary hyperparathyroidism (HPT) is the 3rd most common endocrine disorder, especially in elderly women, with a prevalence of up to 2.1% in postmenopausal women^[1]. The women to men ratio is approximately 3:1. In more than 80% of cases primary HPT presents as a solitary adenoma, multiglandular hyperplasia in 15-20% of cases, while a malignant tumour of the parathyroid gland is extremely rare^[2]. Surgery is the only available curative treatment.

Thanks to the advancements in preoperative localization (scintigraphy, ultrasound), measurement of perioperative PTH levels and above all the fact that most patients have a unilateral parathyroid adenoma, minimally invasive surgical techniques have been developed. Along with the progress of surgical treatment, modern anaesthetic techniques are also being developed. Standard anaesthetic practice in parathyroid surgery is general endotracheal anaesthesia. Ultrasound guided Cervical Plexus Block is a technique that has been applied in parathyroid surgery. The first five successfully operated patients in our institution are presented.

Case Reports

Female patient, 46 years old, obese, BMI-38,97, preoperative calcium (Ca) concentration -3,09 mmol/L, preoperative parathyroid hormone concentration - 219 pg/ml, ultrasound confirmed enlargement of the upper left parathyroid gland with a diameter of 1 cm. Chronic diseases: pituitary tumour - prolactinoma, Hashimoto's thyroiditis, hypertension, diabetes mellitus, previous deep vein thrombosis. Previous operations: cholecystectomy, tonsillectomy.

Female patient, 73 years old. Preoperative calcium (Ca) concentration -2,72 mmol/L, preoperative parathyroid hormone concentration - 254 pg/ml, ultrasound confirmed enlargement of the lower left parathyroid gland. Chronic diseases: hypertension, osteoporosis. Denies previous operations. Varicose veins of the lower extremities. Physical findings: systolic murmur over the precordium.

Female patient, 62 years old. Preoperative calcium (Ca) concentration - 3,11 mmol/L, preoperative parathyroid hormone concentration - 481 pg/ml, ultrasound confirmed enlargement of the lower left parathyroid gland. Previous operations: left shoulder surgery due to leiomyosarcoma in 2006, reoperation in 2007 followed by radiotherapy; right lower lobectomy in 2010 due to leiomyosarcoma metastasis, metastasectomy in the right lung in 2011 and in the left lung in 2013. In 2016, bowel resection with T-T anastomosis due to a meta-change of leiomyosarcoma. In 2017, scapula surgery due to metastases. 2018. resection of the sigmoid colon due to metastases. Chronic diseases-haemorrhoids, kidney calculus. Radiography of lungs - trachea dislocated to the left side, without significant narrowing.

Female patient, 68 years old. Preoperative calcium (Ca) concentration - 3,07 mmol/L, preoperative parathyroid hormone concentration - 185 pg/ml, ultrasound confirmed enlargement of the lower left parathyroid gland. Previous operations: lithotripsy x 2, tumour of the oral cavity, right breast after injury, left eye due to glaucoma, uterine prolapse. Chronic diseases: hypertension, nephrolithiasis, osteoporosis, glaucoma. Varicose veins of the lower extremities.

Female patient, 71 years old. Preoperative calcium (Ca) concentration - 3,03 mmol/L, preoperative parathyroid hormone concentration - 307pg/ml, ultrasound confirmed enlargement of the lower left parathyroid gland. Previous operations: intestine tumour with ileo-ileal anastomosis, cholecystectomy, left patella operation due to injury, lumbar spine operation 2 times due to benign tumour. Chronic diseases: neuroendocrine tumour of the intestine with meta changes in the liver, hypertension, asthma, nephrolithiasis of the right kidney, chronic renal failure gr II. Systolic ejection murmur over the aorta with neck.

Applied technique

The procedure was explained to the patients in detail and written and oral consent was obtained. All patients received premedication: Dormicum 0.05mg/kg and Atropine 0.5mg intramuscularly 30 minutes before the planned surgical intervention. In the operating theatre, vital parameters were monitored: electrocardiogram (ECG) and pulse oximeter continuously, while blood pressure was measured at 5-minute intervals.

The patients were posed in the supine position, with the head turned away from the side to be blocked to facilitate operator access (Figure 1 A). The ultrasound machine was placed on the contralateral side opposite the physician to optimize ergonomics. After identifying the posterior edge of the sternocleidomastoid muscle (SCM) and skin disinfection, the transducer was placed on the lateral neck, overlying the SCM at the level of its midpoint

(approximately the level of the cricoid cartilage). The probe marker was pointed medially towards the thyroid cartilage (Figure 1 B). Once the SCM has been identified, the underlying LSM (musculus levator scapulae), the IJV (internal jugular vein), and the pulsating carotid artery (CA) were also identified. The transducer was moved posteriorly until the tapering posterior edge was positioned in the middle of the screen. Using an in-plane approach, needle was inserted until the tip is visualized within the fascial plane just deep to the SCM and superficial to the prevertebral fascia overlying the LSM and scalene muscles (Figure 1 C). After negative pressure aspiration, 2 ml local anaesthetic was injected to confirm appropriate position, after which the remainder 6ml of local anaesthetic was applied, with confirmation of hydro dissection between the SCM and the deeper muscle layer (Figure 1 D). The same procedure was done on the opposite side of the neck. A total of 16 ml of local anaesthetic was applied, 8 ml for each side (10 ml 0.5% levobupivacaine and 6 ml 2% lidocaine). Twenty minutes later, a sensitive test was performed (pinching with tweezers), and after receiving a negative response (the patient does not feel the pain), 1 ampoule of 1% lidocaine was applied to the incision site. During the operation, the patients were slightly sedated, they did not require additional analgesics, and no side effects of local anaesthetics were registered. The average duration of the operation was 30 minutes. In the postoperative period, all patients were hemodynamically stable with good pain control and no need for rescue analgesics.

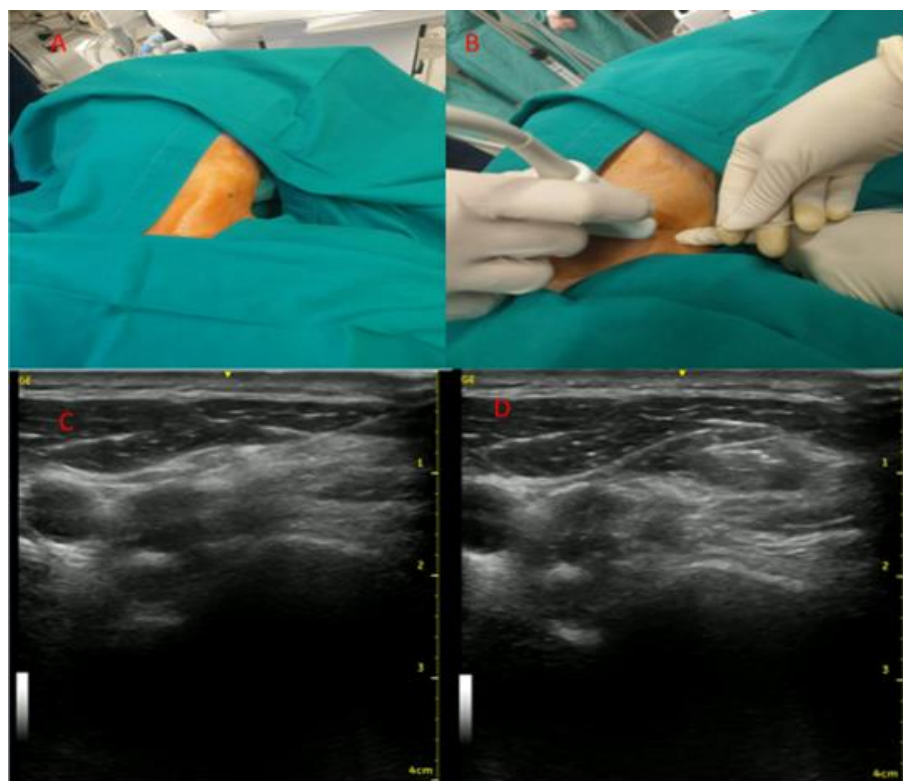


Figure 1: Technic of ultrasound guided superficial cervical plexus block

A - Position of the patient on the operating table; B - probe display; C - localization of the probe before applying local anesthetic; D - confirmation of hydro dissection between the SCM and the deeper muscle layer.

Discussion

Based on our first results of the presented cases, we can say that superficial CPB is a safe and simple procedure in order to provide perioperative analgesia in parathyroid surgery. Miccoli et al found similar results in their study [3] where minimally invasive video-assisted parathyroidectomy (MIVAP) conducted under regional anaesthesia (RA) compared with the results of or general anaesthesia (GA). In contrast to our study, RA involved a bilateral deep cervical block. The interval from skin incision to closure was similar in the

two groups, whereas the total operating time (from induction of anaesthesia to return to the ward) was significantly lower with RA (72.1 versus 90.2 min; $P = 0.001$). Similar to our results, they found that postoperative requirement for pain medication, was significantly lower in the RA group ($P < 0.001$). Study of Pintaric et al investigated the impact of adding deep CPB to superficial CPB in efficacy and success rate of CPB in patients undergoing MIP, using 0.35 mL/kg of 0.5% levobupivacaine. Their results showed that this intervention does not improve the success rate of CPB and that combination of superficial and deep CPB provided similar onset

time of surgical block, similar consumption of intraoperative rescue analgesics, and similar patient satisfaction compared to superficial CPB alone [4]. Other authors published similar results, using this combination in carotid surgery [5-7]. Certain inconsistencies in the literature also exist regarding the definition of the superficial and deep fascia of the neck. Nash et al. [8] reported that the investing layer of the deep cervical fascia (DCF) in the anterior triangle of the neck does not exist and demonstrated that the fatty and connective tissues around nerves and vessels in the neck provide a direct communication between the subcutaneous tissue and the prevertebral layer of the DCF. These results were also confirmed in the research of Pandint et al. [9].

The recommended dosage for performing surficial CPB is 0.35 mL/kg 0.5% levobupivacaine. Pintaric et al. [10] investigated pharmacokinetic profile of 0.35 mL/kg of 0.5% levobupivacaine during superficial and combined (deep and superficial) cervical plexus block (CPB) in patients undergoing minimally invasive parathyroidectomy. They measured levobupivacaine plasma concentration 5,10,15,20,30,45 and 60 minutes after administration and found that the median (range) time required to reach the maximal concentrations was 30 minutes (20-30 min) in group superficial and 20 minutes (15-30 min) in group combined (P = 0.45). No signs of central nervous system or cardiovascular toxicity or other untoward events were observed in any patient using that concentration.

In certain clinical situations, it is necessary to convert the cervical block to general anaesthesia. Carling et al [11] reported that 10.6% of patients in their study (441 patients included) required conversion to GA. The reasons were: simultaneous thyroid resections; the intraoperative parathyroid hormone level failed to decrease by at least 50% from the baseline and extensive exploration was required; technical difficulties related to ensuring adequate protection of the recurrent laryngeal nerve; intraoperative recognition of parathyroid carcinoma; patient discomfort and one patient experienced a toxic reaction to lidocaine.

Conclusion

Ultrasound guided regional anaesthesia in neck surgery is rapidly expanding and the main advantages of ultrasound technique include a direct view of nerves; local anaesthetic (LA) spreading during injection; reduced volume of LA; blood vessels and other structures injury is significantly reduced. It is especially useful in patients with serious comorbidities, in which possible peri-operative consequences and risks of general anaesthesia can be avoided. It also saves money. Our first experiences with superficial CPB are more than encouraging.

Declarations

Ethics approval and consent to participate

The author/s confirm that written consent for submission and publication of this case report including image(s) and associated text has been obtained from the patient in line with Committee on Publication Ethics (COPE) guidance.

List of abbreviations

LA: local anaesthetic
CPB: Cervical Plexus Block
HPT: Hyperparathyroidism
BMI: Body Mass Index
Ca: Calcium
ECG: Electrocardiogram
SCM: Sternocleidomastoid muscle
LSM: Musculus levator scapulae
IJV: Internal jugular vein

CA: Carotid artery

MIVAP: Minimally invasive video-assisted parathyroidectomy

RA: Regional anaesthesia

GA: General anaesthesia

DCF: Deep cervical fascia

Data Availability

All analysed documents during the current study are available from the corresponding author on reasonable request.

Conflicts of Interest

The authors declare that there is no conflict of interest regarding the publication of this paper.

Funding Statement

This work was not supported by any funding.

Authors' contributions

MS, IM, AT, MJ, GZ, BO, MB, DV and BS wrote the draft and collected data; MS, NS, KT, BR analyzed and interpreted the patient data; MS was a major contributor in writing the manuscript; MS and VZ revised the manuscript and provided final approval. All authors read and approved the final manuscript.

Acknowledgments

Not applicable.

References

- [1] E Lundgren, Rastad J, E Thurfjell, G Akerström, S Ljunghall. Population-based screening for primary hyperparathyroidism with serum calcium and parathyroid hormone values in menopausal women. *Surgery* 1997; 121:287-94.
- [2] Carling T. Molecular pathology of parathyroid tumors. *Trends Endocrinol Metab* 2001;1253- 58.
- [3] Miccoli P, Barellini L, Monchik JM, Rago R, Berti PF. Randomized clinical trial comparing regional and general anaesthesia in minimally invasive video-assisted parathyroidectomy. *Br J Surg*. 2005 Jul;92:814-8
- [4] Pintaric TS, Hocevar M, Jereb S, Casati A, Novak Jankovic V. A prospective, randomized comparison between combined (deep and superficial) and superficial cervical plexus block with levobupivacaine for minimally invasive parathyroidectomy. *Anesth Analg*. 2007;105:1160-3
- [5] Pandit JJ, Bree S, Dillon P, Elcock D, McLaren ID, Crider B. A comparison of superficial versus combined (superficial and deep) cervical plexus block for carotid endarterectomy: a prospective, randomized study. *Anesth Analg* 2000; 91:781-6.
- [6] Stonham MD, Doyle AR, Knighton JD, Dorje P, Stanley JC. Prospective, randomised comparison of deep or superficial cervical plexus block for carotid endarterectomy surgery. *Anesthesiology* 1998; 89:907-12.
- [7] De Sousa AA, Filho MA, Faglione W Jr, Carvalho GT. Superficial vs combined cervical plexus block for carotid endarterectomy: a prospective, randomized study. *Surg Neurol* 2005;63: S22-5.
- [8] Nash L, Nicholson HD, Yhang M. Does the investing layer of the deep cervical fascia exist? *Anesthesiology* 2005; 103:962-8.

- [9] Pandit JJ, Dutta D, Morris JF. Spread of injectate with superficial cervical plexus block in humans: an anatomical study. *Br J Anaesth* 2003; 91:733-5.
- [10] Pintaric TS, Kozelj G, Stanovnik L, Casati A, Hocevar M, Jankovic VN. Pharmacokinetics of levobupivacaine 0.5% after superficial or combined (deep and superficial) cervical plexus block in patients undergoing minimally invasive parathyroidectomy. *J Clin Anesth.* 2008 Aug;20(5):333-337
- [11] Carling T, Donovan P, Rinder C, Udelsman R. Minimally invasive parathyroidectomy using cervical block: reasons for conversion to general anesthesia. *Arch Surg.* 2006 Apr;141(4):401-4.



Open Access This article is licensed under a Creative Commons Attribution 4.0 International License, which permits use, sharing, adaptation, distribution and reproduction in any medium or format, as long as you give appropriate credit to the original author(s) and the source, provide a link to the Creative Commons license, and indicate if changes were made. The images or other third-party material in this article are included in the article's Creative Commons license, unless indicated otherwise in a credit line to the material. If material is not included in the article's Creative Commons license and your intended use is not permitted by statutory regulation or exceeds the permitted use, you will need to obtain permission directly from the copyright holder. To view a copy of this license, visit <https://creativecommons.org/licenses/by/4.0/>.

© The Author(s) 2023