



Giant Condyloma of Bushke-Löwenstein (GCBL) in Pregnancy: A Case Report

Priscila Delgado-Macías ^{*1}, Omar Varela-Barraza ², Alfonso Iván Sánchez-Terán ², Fernando Germes-Piña ¹, Michelle Alejandra Macías-Grageda ², Arturo Luévano-González ³

¹Gynecology and Obstetrics Department, General Hospital of Chihuahua Dr. Salvador Zubirán Anchondo, 31200, Chihuahua, México.

²General Surgery Department, Regional Hospital of High Specialty of Bajío, 37660 León, México.

³Structural and Molecular Pathology Department, Autonomous University of Chihuahua, 31125, Chihuahua, México.

*Corresponding author: Priscila Delgado-Macías; priscila_delgado12@hotmail.com

Received 27 July 2023;

Accepted 12 August 2023;

Published 16 August 2023

Abstract

We present a case of Giant condyloma of Bushke-Löwenstein (GCBL) in a 15-year-old pregnant woman from the Tarahumara ethnic group. GCBL is a rare sexually transmitted disease caused by the the Human Papillomavirus (HPV) with a high risk of malignant transformation. Surgical resection is the main treatment, but managing GCBL during pregnancy requires careful consideration. This case highlights a rare and challenging condition that shares features with both classic condyloma acuminata and squamous cell carcinoma, making its differentiation difficult and the importance of comprehensive sexual education, culturally sensitive healthcare, and follow-up care in underserved communities. Challenges in post-surgical monitoring and limited knowledge of perinatal outcomes underscore the need for increased awareness, prevention, and early detection strategies, including HPV vaccination.

Keywords: *Bushke-Löwenstein, surgical oncology, HPV and pregnancy, perinatal outcomes, Giant condyloma.*

Introduction

Giant condyloma acuminata, or Buschke-Löwenstein tumor, is a rare and challenging sexually transmitted disease caused by HPV, particularly serotypes 6 and 11 [1]. This condition manifests as an exophytic papillomatous lesion with a cauliflower appearance and can reach excessive dimensions, affecting the genital area [2,3]. The disease's clinical presentation makes it visually distinctive, aiding in its identification.

Histologically, Buschke-Löwenstein tumor is characterized as a well-differentiated benign squamous proliferation with locally invasive activity and a significant risk of malignant transformation [4]. This transformation is a concerning aspect of the disease, as it can progress to squamous cell carcinoma, making its differentiation from benign lesions challenging.

Notably, this disease is more prevalent in individuals with an active sexual life [2]. Risk factors such as multiple sexual partners, poor body hygiene, and low socioeconomic status contribute to its incidence [4,6]. Early detection and timely management are crucial to prevent complications, particularly in high-risk populations. In the context of pregnancy, co-infection with HPV occurs in up to 18.9% of pregnant patients [5].

Although the appearance of Buschke-Löwenstein tumor during pregnancy is infrequent, its management poses unique challenges. The limited therapeutic options available for pregnant

patients necessitate a careful approach to treatment. Surgical resection remains the preferred treatment option for this condition [6]. However, "en bloc" surgical resection during pregnancy is associated with higher risks of abortion, hemorrhage, and preterm delivery, making it advisable to defer the procedure until the puerperium.

During pregnancy, close monitoring and follow-up are vital to ensure the well-being of both the mother and the fetus. This article highlights that continued research is necessary to explore and establish effective therapeutic strategies, especially for pregnant patients, to optimize outcomes and minimize complications associated with this rare and challenging disease.

Case Presentation

A 15-year-old woman of the Tarahumara ethnic group was referred for presenting a 20-week pregnancy with the presence of a giant lesion in the genital area. Indirect questioning was carried out with the support of the hospital's certified translator since she only speaks rarámuri. She started an active sexual life at the age of 14 with the same sexual partner at present. At 15 weeks of gestation, she notices a warty lesion on the genital area and then observed accelerated growth during the next 5 weeks, associated to progressive difficulty in defecation and urination, vulvar pruritus and perineal pain that worsened while walking.

On physical examination, an exophytic, condylomatous, irregular, wart-like lesion of 25 x 9 x 7 cm was found, with an appearance like a cauliflower, extending to the vulva and perineum (**Figure 1**) associated to the presence of abundant purulent and fetid leucorrhoea. No palpable inguinal lymph nodes were detected. Laboratory studies showed bacteriuria, leukocyturia and the presence of *Trichomonas vaginalis* in the general urine test. The presence of human immunodeficiency virus and syphilis infections was ruled out.

The patient was admitted and evaluated by the dysplasia clinic who recommended resection under anesthesia due to the size of the tumor and the associated symptoms. Under epidural anesthesia, the patient was placed in the lithotomy position and “en bloc” surgical resection was performed with electrofulguration

(**Figure 2**). During surgery there were no alterations in fetal monitoring. Presenting an adequate post-surgical evolution. The pathology department reported a lesion with a papillomatous pattern, covered with keratinocytes with marked acanthosis and whose cells show impaired maturation (**Figure 3**), characterized by nuclear growth with loss of the nuclear-cytoplasmic relationship, areas of hypergranulosis and koilocytic changes (**Figure 4 and Figure 5**) and a basal layer intact without zones of invasion or atypia.

Upon discharge, an appointment was made at the maternal-fetal medicine clinic for follow-up 2 weeks after the surgery but the patient did not attend and it was not possible to locate her due to the remote area where she lives. The perinatal outcome, maternal-fetal complications, or recurrence that may have occurred is unknown.

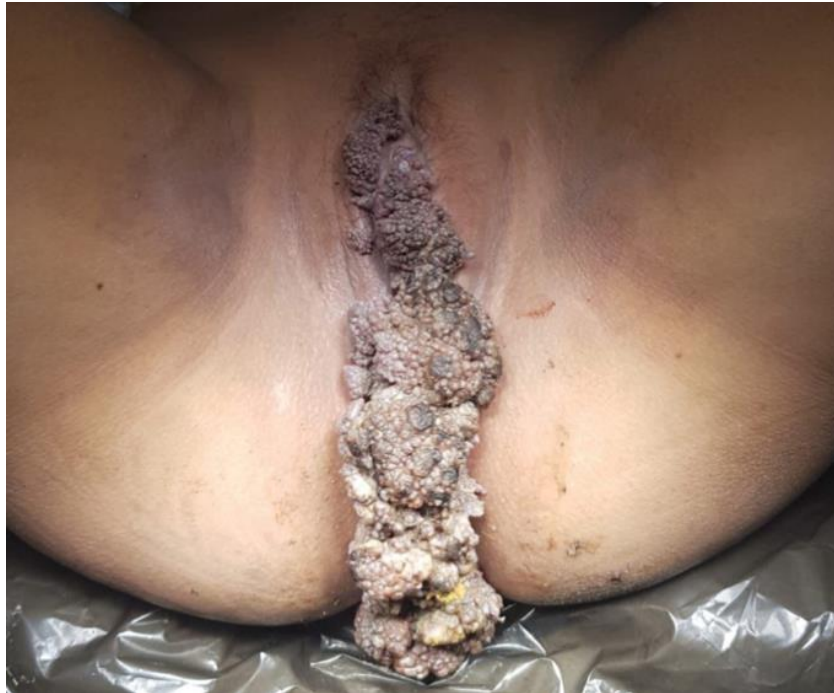

Figure 1: Giant condyloma of Bushke-Löwenstein (GCBL)

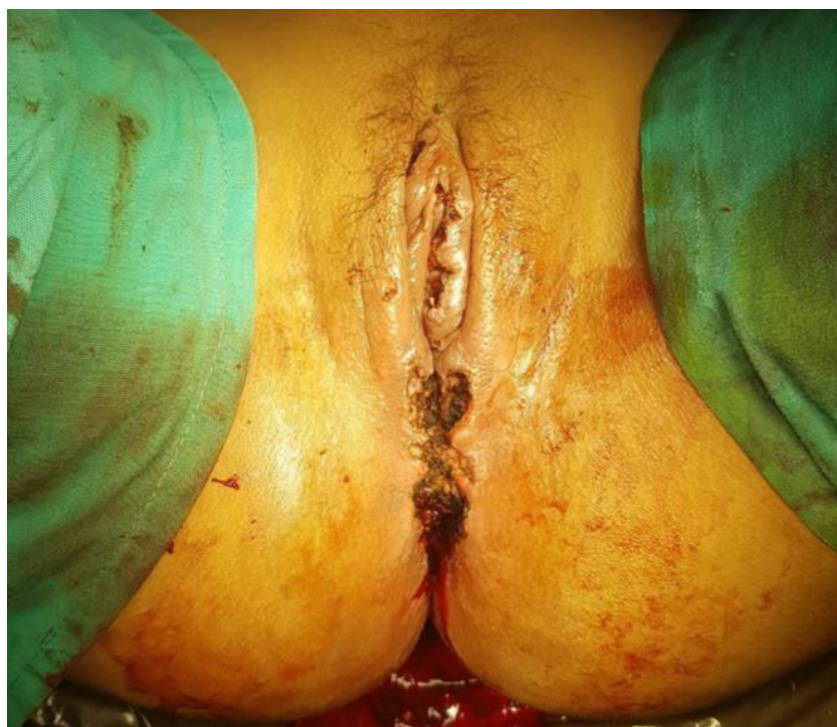

Figure 2: The surgical wound after “en bloc” surgical resection performed with electrofulguration.

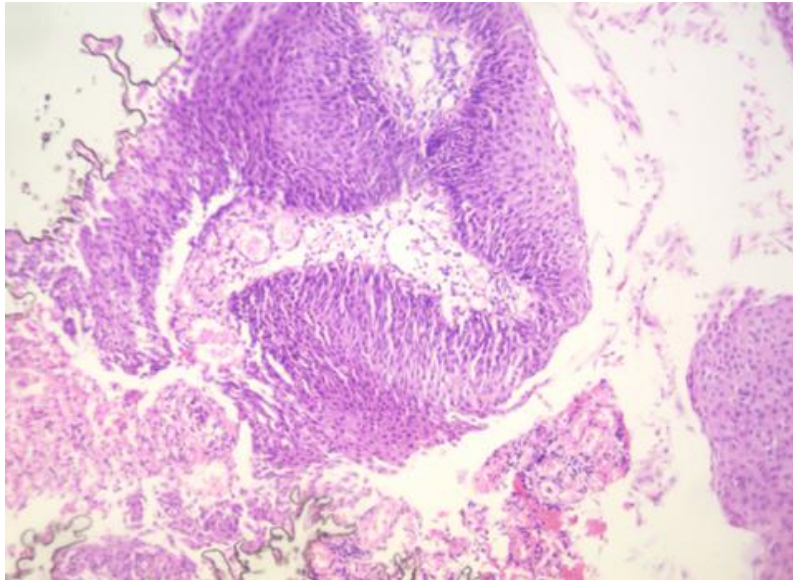


Figure 3: Lesion with papillomatous pattern, keratinocytes with marked acanthosis and areas of hypergranulosis. (hematoxylin and eosin staining, ×200)

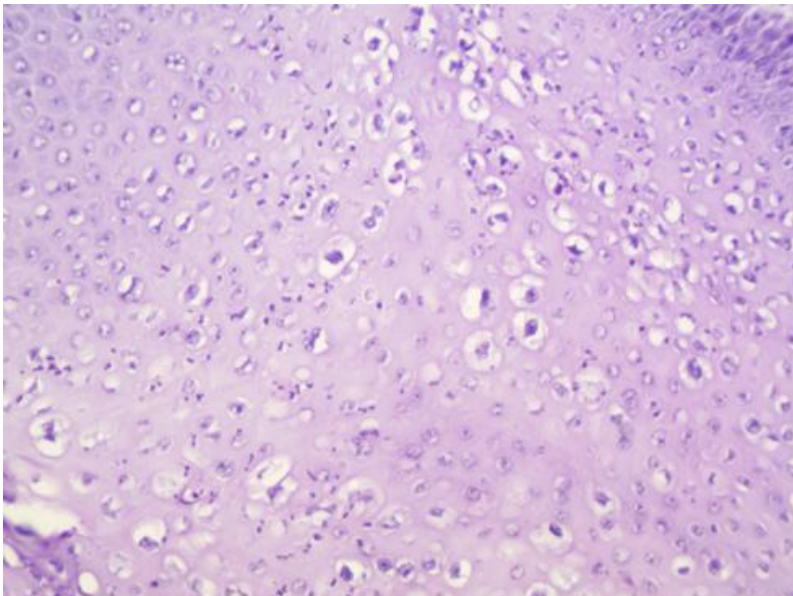


Figure 4: Cells with koilocytic changes, nuclear growth with loss of nuclear to cytoplasmic ratio. No areas of atypia or malignant transformation. (hematoxylin and eosin staining, ×200)

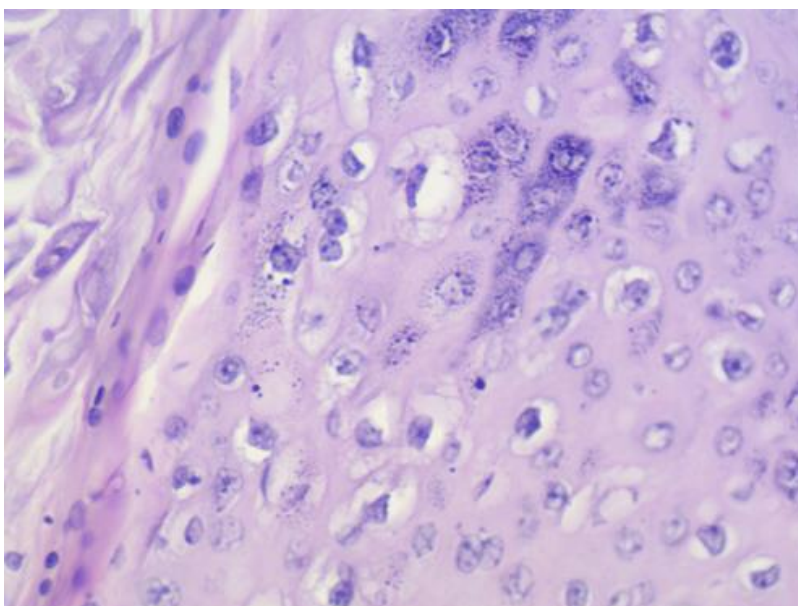


Figure 5: Squamous mucosa with dysplasia and viral cytopathic effect, consistent with koilocytosis of HPV infection (hematoxylin and eosin staining, ×400)

Discussion

Since the first description by Abraham Buschke and Ludwig Löwenstein back in 1925 [7-8], the giant condyloma acuminatum (GCA) and Buschke–Löwenstein tumor (BLT) have become synonymous [9]. It is considered part of a spectrum between a classic condyloma acuminata and a squamous cell carcinoma, where it is always preceded by a classic carcinoma acuminata and presenting a potential risk of transformation to a squamous cell carcinoma, sharing both properties, which make their differentiation difficult [10].

It is a sexually transmitted disease that presents an incidence of 0.1% among sexually active people, predominating in males in a ratio of 2.7:1, with a mean age of presentation of 45 years [11-12]. The most common location is in the external genital area, the glans penis in men and the vulva in women, representing 90% of the cases [4,12]. Infection with human papillomavirus, especially the low-risk serotypes (6 and 11), corresponds to 90% of cases, with reports of association with serotypes 16, 18, and 52 considered high risk [1,13,14]. Risk factors that may predispose to the transformation of classic condyloma acuminata into Buschke-Löwenstein tumor include congenital or acquired immunosuppression (human immunodeficiency virus infection, diabetes, drugs), smoking, alcoholism, multiple sexual partners, previous genital infections, poor body hygiene, or low socioeconomic status [4,6].

It manifests as an exophytic papillomatous lesion with the appearance of cauliflower, with the presence of a perineal tumor being the main finding, frequently associated with dysuria, hemorrhoids, vulvar pruritus, stench, leucorrhoea, bleeding, and development of fistulas [2]. Microscopically, the presence of a densely keratinized and well-differentiated epithelium without atypia is described, with papillary deterioration of fibrovascular centers, prominent koilocytosis, and characteristically an endophytic pattern towards the underlying tissue [10]. It differs from squamous cell carcinoma by not presenting cytonuclear abnormalities, respecting the basal membrane, and not presenting lymphatic dissemination, which is why it is considered benign [8].

It presents slowly progressive growth, from months to years, managing to reach tens of centimeters in length if its progression is allowed [12]. Its aggressive behavior at the local level has been described, despite not presenting evidence of histological malignancy, being able to generate compression or even destruction of other adjacent tissues such as the rectum or urethra [4,1,5]. Paradoxically, the presence of metastases to distance is exceptional and is usually associated with a malignant neoplastic transformation, which occurs in up to 56%, with squamous cell carcinoma being the most frequent transformation reported [4]. The presence of bleeding, basal infiltration, or the presence of lymphadenopathy regions should lead to suspicion of malignant transformation [12].

The patient in the case, in addition to the atypical age of presentation, was on the second trimester of pregnancy. Very few cases of Buschke-Löwenstein tumor during pregnancy have been reported, in which the accelerated growth rate is relevant compared to the non-pregnant population [6,16], presenting in this case a growth in five weeks from the date of detection of classic condyloma acuminata by the patient. This accelerated growth has also been reported in patients with human immunodeficiency virus infection [9,17]. Due to the lack of studies, it has not been possible to determine the association between Buschke-Löwenstein tumor of accelerated growth and an increase in the risk of neoplastic transformation, but the rate is expected to be higher in these cases.

Factors such as location, size of the lesion, immunological status, and the availability of therapeutic resources must be

considered when choosing a treatment [18]. Although it remains a controversial issue due to the low incidence and the lack of available information, surgical resection is considered the best treatment option to date [6]. A radical resection with wide borders that are reported to be negative and with skin reconstruction should always be performed to minimize the risk of recurrence, which is reported in up to 67% of cases. However, given the invasive behavior of the tumor, it is very common that the total resectability of the tumor is not always accessible [4].

Alternatives to surgical treatment include CO2 laser, electrocoagulation, cryotherapy with topical chemotherapy, radiation, intralesional injection of 5-fluorouracil or interferon, and topical imiquimod. However, the superiority of some over other options has not been demonstrated [6]. Multiple therapeutic combinations have been described with the intention of reducing the high rate of recurrence; however, a significant effect on recurrence has not been demonstrated, in addition to the lack of a consensus to decide when to choose them [1]. Destructive (CO2 laser) or topical (imiquimod) non-surgical techniques are not recommended in the first instance due to the resulting tissue destruction, making an adequate histopathological study and detection of neoplastic transformation impossible [10]. Intralesional injection of the HPV vaccine is an emerging therapy, which seems to be a good therapeutic option, achieving lesion regression in weeks, especially in small lesions [19].

The approach to Buschke-Löwenstein tumor during pregnancy is more complex since the maternal-fetal implications are assessed. Vertical human papillomavirus infection at the time of vaginal delivery is high, which is why in patients with the presence of multiple vaginal lesions, cesarean delivery is the recommended route of delivery [5]. Despite the few references on the treatment of Buschke-Löwenstein tumor in pregnancy, the existing ones support deferring surgical treatment until the puerperium, since performing “en bloc” resection during pregnancy has been associated with high rates of abortion, hemorrhage during pregnancy, preterm delivery, and low birth weight, in addition to the anesthetic indications required for the procedure, which has been associated with neurodevelopmental delay [6,12].

The decision to perform surgical resection during pregnancy on this patient was due to the accelerated growth in a preterm pregnancy, the associated symptoms of dysuria and difficulty defecating that the patient presented, and the high degree of morbidity that these would represent later in the pregnancy and the remaining time for the resolution of the pregnancy that represented a potential risk to allow growth and increase maternal-fetal complications. There were no complications during the surgical procedure, but a high risk of bleeding during the procedure has been described [6]. The best therapeutic option should always be selected after carrying out an individualized approach to each patient, considering the risks and benefits [2]. The outcome of the pregnancy and the related complications in the patient are unknown for reasons already mentioned.

Recurrence occurs on average ten months after the primary resection, but it can appear up to decades later, which is why information to the patient about the risk of recurrence and long-term follow-up is highly recommended to be able to make detections early, less invasive treatments, and decrease the morbidity associated with the Buschke-Löwenstein tumor [6]. It is also recommended to inform the sexual partners of the patients to promote the adequate use of condoms that reduce the transmission of the human papillomavirus and promote self-detection of papillomatous lesions for timely diagnosis and treatment. So far, there is no direct association between the tetravalent and pentavalent vaccines against

human papillomavirus and the decrease in the incidence of Buschke-Löwenstein tumor. It is expected that in the future, the global reduction in the prevalence of HPV will lead to a decrease in the incidence and risk of developing Buschke-Löwenstein tumor ^[20].

Conclusions

This case presents a challenging and complex situation involving a 15-year-old woman from the Tarahumara ethnic group with a giant genital lesion during a 20-week pregnancy. Giant condyloma of Buschke-Löwenstein (GCBL) is a rare and challenging condition that shares features with both classic condyloma acuminata and squamous cell carcinoma, making its differentiation difficult. It predominantly affects sexually active individuals, with a higher incidence in males. Surgical resection is the current treatment of choice, although other modalities have been explored. The decision to perform "en bloc" surgical resection under anesthesia was justified considering the lesion's size and the associated distressing symptoms. The surgical approach allowed for the safe removal of the tumor without compromising fetal well-being.

Managing GCBL during pregnancy requires careful consideration, and long-term follow-up is crucial to detect recurrences. However, the patient's failure to attend the follow-up appointment and the inability to locate her in the remote area where she lives pose significant challenges for post-surgical monitoring and potential maternal-fetal complications. It also limits the knowledge of the perinatal outcome and recurrence status.

This case highlights the importance of comprehensive sexual education, access to reproductive healthcare, and follow-up care, especially in underserved and remote communities. It underscores the need for culturally sensitive approaches and healthcare services tailored to specific ethnic groups, addressing language barriers, and providing information about the importance of post-surgical monitoring to ensure the well-being of both the patient and the fetus. Increased awareness, prevention, and early detection strategies, along with HPV vaccination, may help reduce the incidence and risk of GCBL in the future.

Ethics approval and consent to participate

This work was performed according to the principles expressed in the Declaration of Helsinki. Written informed consent was obtained from the patient.

Conflicts of Interest

The authors declare that there is no conflict of interest regarding the publication of this paper.

Authors' contributions

All authors made substantial contributions to the conception or design of the work and reached agreement to be accountable for all aspects of the work in ensuring that questions related to the accuracy or integrity of any part of the work are appropriately investigated and resolved. Priscila Delgado-Macias: acquisition, analysis, and interpretation of data for the work; Drafting the work and revising it critically for important intellectual content; Final approval of the version to be published. Omar Varela-Barraza: analysis and interpretation of data for the work; Revising it critically for important intellectual content; Final approval of the version to be published. Martha Elena Gutiérrez-Brambila: analysis of data for the work; Revising it critically for important intellectual content; Final approval of the version to be published. Alfonso Iván Sánchez-Terán: acquisition, analysis, and interpretation of data for the work;

Drafting the work and revising it critically for important intellectual content; Final approval of the version to be published. Fernando Germes-Piña: acquisition, analysis, and interpretation of data for the work; Drafting the work and revising it critically for important intellectual content; Final approval of the version to be published. Michelle Alejandra Macías-Grageda: acquisition, analysis, and interpretation of data for the work; Drafting the work and revising it critically for important intellectual content; Final approval of the version to be published. Arturo Luévano-González: analysis and interpretation of the surgical specimen; Final approval of the version to be published.

References

- [1] [Nieves-Condoy JF, Acuña-Pinzón CL, Chavarría-Chavira JL, et al. "Giant Condyloma Acuminata (Buschke-Lowenstein Tumor): Review of an Unusual Disease and Difficult to Manage." *Infect Dis Obstet Gynecol.* 2021 Jun 30;2021:9919446. doi: 10.1155/2021/9919446
- [2] Chu QD, Vezeridis MP, Libbey NP, et al. "Giant condyloma acuminatum (Buschke-Lowenstein tumor) of the anorectal and perianal regions." *Analysis of 42 cases. Dis Colon Rectum.* 1994 Sep;37(9):950-7. doi: 10.1007/BF02052606
- [3] Ryzewska-Rosolowska A, Kakareko K, Kowalik M, et al. "An unexpected giant problem - Giant condyloma (Buschke-Lowenstein tumor)." *Int J Infect Dis.* 2021 Feb;103:280-281. doi: 10.1016/j.ijid.2020.11.200
- [4] Ben Kridis W, Werda I, Charfi S, et al. "Buschke — Lowenstein anal tumor: an ambiguous entity." *Exp Oncol.* 2019 Jun;41(2):182-4. doi: 10.32471/exp-oncology.2312-8852.vol-41-no-2.13119
- [5] Park H, Lee SW, Lee IH, et al. "Rate of vertical transmission of human papillomavirus from mothers to infants: relationship between infection rate and mode of delivery." *Virol J.* 2012 Apr 12;9:80. doi: 10.1186/1743-422X-9-80
- [6] Cui T, Huang J, Lv B, et al. "Giant condyloma acuminatum in pregnancy: A case report." *Dermatol Ther.* 2019 Jul;32(4):e12972. doi: 10.1111/dth.12972
- [7] Buschke, A., Loewenstein, L. "Über Carcinomähnliche Condylomata Acuminata des Penis." *Klin Wochenschr.* 1925 Sep;1726-1728. doi: 10.1007/BF01728480
- [8] Steffen C. "The men behind the eponym--Abraham Buschke and Ludwig Lowenstein: giant condyloma (Buschke-Loewenstein)." *Am J Dermatopathol.* 2006 Dec;28(6):526-36. doi: 10.1097/01.dad.0000211528.87928.a8
- [9] Trombetta LJ, Place RJ. "Giant condyloma acuminatum of the anorectum: trends in epidemiology and management: report of a case and review of the literature." *Dis Colon Rectum.* 2001 Dec;44(12):1878-86. doi: 10.1007/BF02234473
- [10] El Bessi M, Dougaz W, Jones M, et al. "A Giant Anorectal Condyloma Is Not Synonym of Malignancy." *J Gastrointest Cancer.* 2019 Dec;50(4):1026-1028. doi: 10.1007/s12029-018-00189-3
- [11] Nambudiri VE, Mutyambizi K, Walls AC, et al. "Successful treatment of perianal giant condyloma acuminatum in an immunocompromised host with systemic interleukin 2 and topical cidofovir." *JAMA Dermatol.* 2013 Sep;149(9):1068-70. doi: 10.1001/jamadermatol.2013.5160

- [12] Riethmuller D, Buisson A, Thong Vanh C, et al. "La tumeur de Buschke Lowenstein chez la femme enceinte." *Gynécologie Obstétrique Fertil Sénologie*. 2022 Feb;50(2):201-4. doi: 10.1016/j.gofs.2021.08.001
- [13] Diani M, Boneschi V, Ramoni S, et al. "Rapidly Invasive Buschke-Löwenstein Tumor Associated With Human Papillomavirus Types 6 and 52." *Sex Transm Dis*. 2015 Oct;42(10):547-8. doi: 10.1097/OLQ.0000000000000346
- [14] Rimtebaye K, Mahamat MA, Kimassoum FR, et al. "Clinical Anatomopathological and Therapeutic Aspects of Buschke-Lowenstein Tumor." *Open J Urol*. 2021 Nov;11(11):420-6. doi: 10.4236/oju.2021.1111041
- [15] Jorgaqi E, Jafferany M. "Giant condyloma acuminatum (Buschke-Lowenstein tumor): Combined treatment with surgery and chemotherapy." *Dermatol Ther*. 2020 Jan;33(1):e13193. doi: 10.1111/dth.13193
- [16] Crespo R, Puig F, Lanzon A, et al. "Buschke-Lowenstein tumor and pregnancy: a case report." *Eur J Gynaecol Oncol*. 2007 Jan;28(4):328-9.
- [17] Bastola S, Halalau A, Kc O, et al. "A Gigantic Anal Mass: Buschke-Löwenstein Tumor in a Patient with Controlled HIV Infection with Fatal Outcome." *Case Rep Infect Dis*. 2018 Apr;2018: e7267213. doi: 10.1155/2018/7267213
- [18] Fathi R, Tsoukas MM. "Genital warts and other HPV infections: established and novel therapies." *Clin Dermatol*. 2014 Mar;32(2):299-306. doi: 10.1016/j.clindermatol.2013.08.014
- [19] Thomas R, Smith-Matthews S, Ho J. "Giant condyloma of Buschke-Lowenstein in a patient with pemphigus vegetans treated with intralesional and systemic human papillomavirus vaccine." *JAAD Case Rep*. 2022 Feb;20:54-7. doi: 10.1016/j.jdc.2021.12.024
- [20] Skerlev M, ele-Starčević L, Ljubojević S. "The Enigma of Buschke-Löwenstein in the HPV Vaccine Era." *Sex Transm Infect*. 2013 Jul;89(Suppl 1): A122.2-A122. doi: 10.1136/sextrans-2013-051184.0376



Open Access This article is licensed under a Creative Commons Attribution 4.0 International License, which permits use, sharing, adaptation, distribution and reproduction in any medium or format, as long as you give appropriate credit to the original author(s) and the source, provide a link to the Creative Commons license, and indicate if changes were made. The images or other third-party material in this article are included in the article's Creative Commons license, unless indicated otherwise in a credit line to the material. If material is not included in the article's Creative Commons license and your intended use is not permitted by statutory regulation or exceeds the permitted use, you will need to obtain permission directly from the copyright holder. To view a copy of this license, visit <https://creativecommons.org/licenses/by/4.0/>.

© The Author(s) 2023