



# Sub-Hepatic Appendicitis: Case Report

Mashal Alhoseni <sup>\*2</sup>, Yousef Alhusaini <sup>1</sup>, Jarah Alenezi <sup>3</sup>, Nora Almutairi <sup>2</sup>

<sup>1</sup>Kuwait Institute Medical Specialization, Kuwait.

<sup>2</sup>Surgery Department, Al-Jahra Hospital, Kuwait.

<sup>3</sup>University of Jordan, Amman, Jordan.

\*Corresponding author: Mashal Alhoseni; [dr.mishalhu@gmail.com](mailto:dr.mishalhu@gmail.com)

Received 09 October 2023;

Accepted 29 October 2023;

Published 02 November 2023

## Abstract

**Introduction and importance:** Subhepatic appendicitis, a rare variant of acute appendicitis, presents unique challenges in diagnosis and management. This discussion will delve into its incidence, diagnostic approach, and prognosis. **Case presentation:** A 58-year-old female patient with multiple co-morbidities presented with 2 days of right-sided abdominal pain fever and vomiting. CT scan was done showing features of subhepatic appendicitis. A Laparoscopic appendectomy was done. **Clinical discussion:** Subhepatic appendicitis is considered an uncommon manifestation of acute appendicitis. Due to its unusual anatomical location, it can pose difficulties in recognizing and diagnosing, mimicking other conditions. The prognosis of subhepatic appendicitis depends on early detection and intervention. Delayed diagnosis could lead to complications. **Conclusion:** Subhepatic appendicitis, a rare condition, poses distinct clinical challenges. The report analyzes its prevalence, symptoms, diagnosis, and treatment, aiming to enhance comprehension of its impact on medical and surgical approaches.

**Keywords:** Appendicitis, subhepatic appendicitis, laparoscopy, acute abdomen, case report.

## Introduction

Appendicitis is a common surgical emergency characterized by inflammation of the vermiform appendix, typically located in the right lower quadrant of the abdomen. However, anatomical variations of the appendix's position have been reported, leading to atypical clinical presentations and diagnostic challenges. One such anatomical variation is the subhepatic appendix, where the appendix is situated above the liver, rather than its usual location.

Subhepatic appendicitis is a rare variant of acute appendicitis that demands a heightened level of clinical suspicion due to its atypical presentation. The prevalence of subhepatic appendicitis has been documented. This anatomical anomaly can complicate the clinical diagnosis of appendicitis and potentially lead to delayed treatment. Given its rarity and the potential impact on patient care, it is crucial to explore cases of subhepatic appendicitis in detail. In this case report, we present the clinical and radiological findings of a 58-year-old female patient diagnosed with a subhepatic appendix, highlighting the challenges encountered, the management strategies employed, and the significance of understanding such anatomical variations.

## Case presentation

A 58-year-old female patient super obese known case of diabetes hypertension and ischemic heart disease presented to the emergency department (ED) of our district general hospital with a two-days history of right-sided abdominal pain, fever, nausea, anorexia, and vomiting. On examination, she was febrile with a core body temperature of 37.8°C, but her remaining vital signs were within normal range. Abdominal examination revealed right-sided abdominal tenderness, which was more over the right upper quadrant with muscle guarding and positive rebound tenderness. Her laboratory blood work showed an elevated leukocyte count of  $15.5 \times 10^9/L$ , with neutrophils being 66.7%. Renal and liver function tests were normal. Radiographs of the chest and abdomen were unremarkable, but the abdominal CT scan showed evidence of appendicitis, with the liver of average size with homogenous CT texture, No intra-hepatic or extra-hepatic biliary radicles dilatation. The Radiologist reported that appendix is seen relatively dilated reaching 9 mm in calibre, with fluid-filled lumen and enhancing wall associated with surrounding fat stranding, and small regional lymphadenopathies in the sub-hepatic region with no related mass, abscess, and no collection.

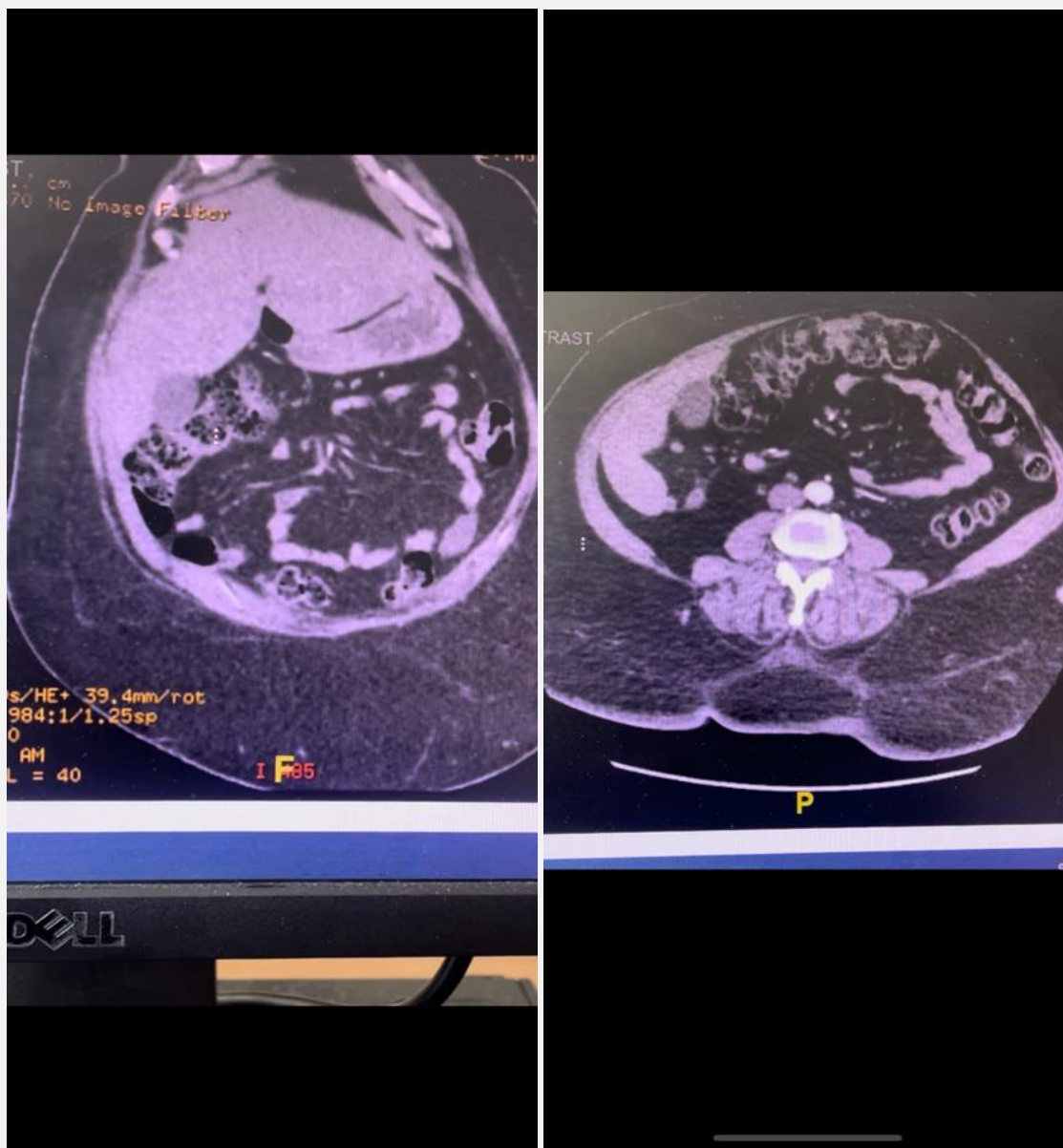

Figure 1: CT scan showing sub-hepatic appendix

The patient was taken to the operating room (OR) for Diagnostic Laparoscopy after antibiotic and thromboembolism prophylaxis, Insufflation was done with Verus Needle at Palmer point, the abdomen was entered 3 Ports in order to have good access to the

subhepatic region, 10 mm supraumbilical port and 10 mm Left Lumber 5 mm Right iliac region. Upon exploration, we found the inflamed appendix and cecum in the subhepatic position.

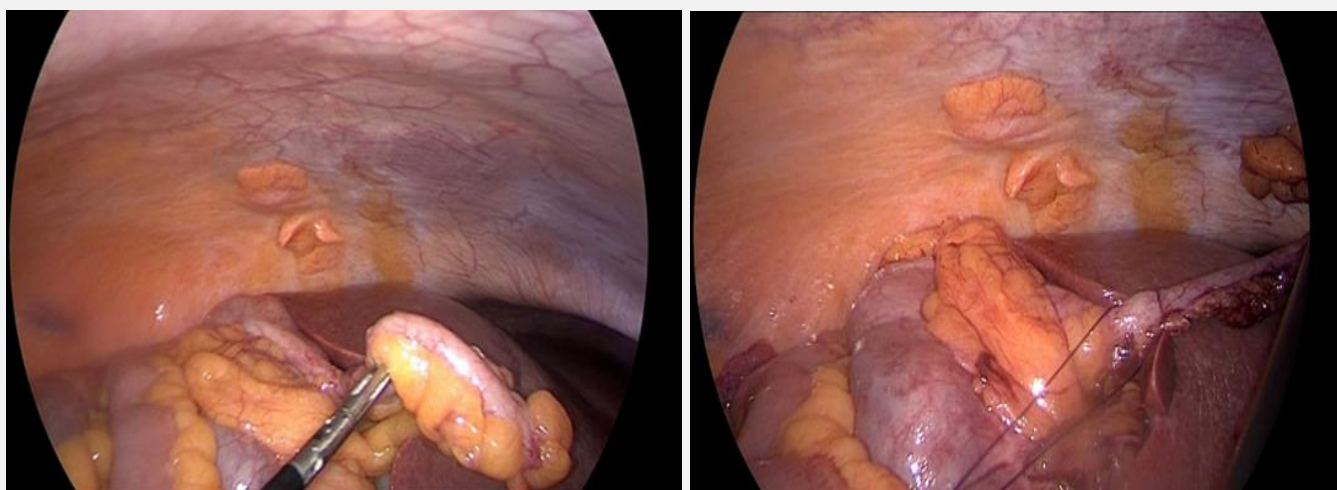


Figure 2: Intraoperative sub-hepatic appendix

The appendectomy was carried out smoothly since there was no perforation or mass formation. The patient had an uneventful recovery and was discharged home in good condition after two days.

## Discussion

The first case of subhepatic appendicitis was reported in 1955 by King [1]. Subhepatic appendix is due to failure of the cecum to rotate. Intestinal malrotation occurs in approximately 0.2% of all births [2]. Resulting in subhepatic Cecum and appendix.

The prevalence of anatomical variations in the position of the appendix, such as subhepatic appendices, has garnered attention in the medical literature. While the vermiform appendix is conventionally located in the right lower quadrant of the abdomen, anatomical anomalies can lead to its atypical positioning. Studies suggest that the prevalence of subhepatic appendices is approximately 0.08% in the general population [3].

These figures indicate the rarity of this phenomenon and underscore the significance of investigating and reporting cases of subhepatic appendicitis to expand our understanding of such anatomical variations.

Subhepatic appendicitis poses diagnostic challenges due to its deviation from the expected clinical presentation. Clinical manifestations can be deceptive, mimicking other conditions such as cholecystitis, Gastritis or upper gastrointestinal disorders. Consequently, the diagnosis of subhepatic appendicitis may encounter delays or misinterpretations.

Radiological imaging is pivotal in the accurate diagnosis of subhepatic appendicitis. Contrast-enhanced computed tomography (CT) scans are extensively employed to visualize anatomical anomalies and detect inflammatory changes. Notably, Computed tomography (CT) scans are more accurate than ultrasonography, with a 93 to 98% accuracy rate [4]. Ultrasound is the initial choice for imaging due to its non-invasive nature. However, sensitivity might be compromised due to the location of the appendix beneath the liver. CT Scan is Often considered the gold standard for diagnosis. It provides detailed visualization of the anatomical location and inflammatory changes. A CT scan can help distinguish subhepatic appendicitis from other conditions presenting similar symptoms.

The unfamiliar symptom profile led to an initial misdiagnosis of gastritis. This instance underscores the importance of considering anatomical variations like the subhepatic appendix when evaluating patients with abdominal pain, particularly when symptoms deviate from the conventional appendicitis presentation.

In this report's case, a contrast-enhanced CT scan played a pivotal role in confirming the subhepatic position of the appendix and revealing indicators of inflammation. The reliability of radiological imaging in detecting anatomical variations and pathology underscores its importance in guiding clinical decision-making and surgical planning for subhepatic appendicitis.

The management of subhepatic appendicitis aligns with the standard treatment approach for appendicitis. Surgical intervention, typically through appendectomy, remains the primary course of action. The emergence of laparoscopic appendectomy as the preferred surgical method has led to improved patient outcomes, with reported success rates exceeding 96.97% [5]. The laparoscopic approach's advantages, including reduced postoperative pain and quicker recovery. The case presented in this report also underwent a laparoscopic appendectomy, resulting in a successful outcome. The choice of surgical approach should be tailored to the patient's condition and the surgeon's expertise. Sharing experiences of successful management, such as utilizing laparoscopic techniques, can contribute to the body of knowledge surrounding optimal strategies for treating subhepatic appendicitis.

The prognosis of subhepatic appendicitis depends on early detection and prompt intervention. Delayed diagnosis could lead to complications such as abscess formation, peritonitis, and even organ damage due to the proximity of the inflamed appendix to the liver.

Recognizing and understanding anatomical variations like the subhepatic appendix holds substantial clinical implications. Surgeons, radiologists, and clinicians should be aware of these anomalies to ensure accurate diagnosis and effective treatment.

Timely recognition of subhepatic appendicitis can prevent unnecessary diagnostic delays and guide appropriate management decisions. Insights gained from managing such cases contribute to refining medical practices and improving patient outcomes.

## Conclusion

In summary, subhepatic appendicitis, while rare, presents a distinctive challenge in clinical practice. Analyzing the case of a 58-year-old female with a subhepatic appendix underscores the rarity of this anatomical variation and the ensuing diagnostic and management complexities. By reviewing prevalence rates, clinical presentations, diagnostic approaches, and treatment strategies, this report contributes to a broader understanding of subhepatic appendicitis and its implications for surgical and medical practice.

## Consent

Written informed consent was obtained from the patient for publication of this case report and accompanying images. A copy of written consent is available for review by the Editor-in-Chief of this journal in request.

## Ethical approval

Ethical approval is exempt at our institution.

## Funding

This work did not receive any grant from funding agencies in the public, commercial, or not-for-profit stories.

## Declaration of competing interest

There is no conflict of interest including any financial or personal relationships with other people or organizations or any work influencers.

## Reference

- [1] Subhepatic appendicitis. King A. *AMA Arch Surg*. 1955; 71:265–267. [PubMed] [Google Scholar]
- [2] Diagnosis and surgical management of congenital intestinal malrotation presenting with midgut volvulus in an adult: high index of suspicion (case report). Gezahan Negusse Ayane and khutsafalo kadimo <https://www.ncbi.nlm.nih.gov/pmc/articles/PMC6057601/> #:~:text=Intestinal%20malrotation%20occurs%20in%20approximately,within%20a%20year%20after%20birth.
- [3] Laparoscopic appendectomy for appendicitis in uncommon situations: the advantages of a tailored approach. Palanivelu C, Rangarajan M, John SJ, Senthilkumar R, Madhankumar MV. <http://www.smj.org.sg/sites/default/files/4808/4808a5.pdf>. *Singapore Med J*. 2007; 48:737–740. [PubMed] [Google Scholar]
- [4] The diagnostic value of the computed tomography scan and ultrasonography in acute appendicitis Mahshid Bahrami, Hannaneh Mirgaloyebayat, Zahra Mohajeri, Hossein Mohammadi, Samira Amin Afshari, Pooya Fazeli, Dorna Masaeli, and Sayed Mohammad Amin Nourian <https://www.ncbi.nlm.nih.gov/pmc/articles/PMC10009470/>

- [5] Endoscopic retrograde appendicitis therapy versus laparoscopic appendectomy versus open appendectomy for acute appendicitis: a pilot study: Zhemin Shen, Peilong Sun, Miao Jiang, Zili Zhen, Jingtian Liu, Mu Ye & Weida Huang <https://bmegastroenterol.biomedcentral.com/articles/10.1186/s12876-022-02139-7>

reproduction in any medium or format, as long as you give appropriate credit to the original author(s) and the source, provide a link to the Creative Commons license, and indicate if changes were made. The images or other third-party material in this article are included in the article's Creative Commons license, unless indicated otherwise in a credit line to the material. If material is not included in the article's Creative Commons license and your intended use is not permitted by statutory regulation or exceeds the permitted use, you will need to obtain permission directly from the copyright holder. To view a copy of this license, visit <https://creativecommons.org/licenses/by/4.0/>.

© The Author(s) 2023



**Open Access** This article is licensed under a Creative Commons Attribution 4.0 International License, which permits use, sharing, adaptation, distribution and