

# Tzanck Smears and Its Diagnostic Utility - An Institutional Experience

Dr. Athulya Krishna Kumar K.T<sup>1</sup>, Dr. Kalathingal Kamarunisha Aboobacker<sup>2</sup>, Dr. Kiran H.S<sup>3</sup>,  
Dr. Vishal Agarwal<sup>4</sup>

<sup>1</sup>Postgraduate, Department of Pathology, Yenepoya Medical College, Mangalore

<sup>2</sup>Postgraduate, Department of Pathology, Yenepoya Medical College, Mangalore

<sup>3</sup>Assistant Professor, Department of Pathology, Yenepoya Medical College, Mangalore

<sup>4</sup>Postgraduate, Department of Dermatology, Yenepoya Medical College, Mangalore

Email Id - [athulyanambiar156@gmail.com](mailto:athulyanambiar156@gmail.com)



## **Abstract:**

**Aim:** Tzanck smear is a simple test that gives reliable information in many varieties of skin lesions and can be used for quick, preliminary diagnosis of a number of cutaneous dermatoses. The aim of this study was to analyse the usefulness of tzanck smears in the diagnosis of cutaneous dermatoses and correlate the findings, clinically as well as histopathologically. **Materials and Methods:** Retrospective analysis of all tzanck smears received during the time period of 2 years (January 2016- January 2018), was carried out. The smears were assessed with regard to its correlation to the clinical diagnosis. Corroboration of the tzanck smear findings were also evaluated with respect to the histopathological diagnosis, in cases where skin biopsy was done. **Results:** A total of 70 tzanck smears were performed during our study period. Out of 29 cases of pemphigus, the tzanck smears corroborated with 22 cases. Non-specific findings were obtained in clinically suspected cases of pemphigoid. Out of 25 suspected herpetic infections, the characteristic tzanck smear findings were observed in 11 of them. Tzanck smear findings correlated with 13 out of the 19 cases of histopathologically confirmed pemphigus lesions. **Conclusion:** Tzanck smear test is a rapid, inexpensive and useful tool to aid in the diagnosis of clinically suspected vesico bullous, pustular and erosive skin lesions. It also serves as a useful adjunct to histopathological evaluation of skin biopsies, especially immuno-bullous skin disorders.

**Keywords:** Tzanck smear, pemphigus vulgaris, herpes infection.

## **Introduction**

Diagnostic cytology is the study of the characteristics of an individual cell, and tzanck smears form an important aspect of this. The mechanism of acantholysis forms the basis of Tzanck smears, where there is breakdown of the intercellular bridges between the epidermal cells. This results in the intact cells which tend to become rounded, and are known as acantholytic cells.<sup>[1]</sup>

Tzanck smears were first introduced in 1947 by Arnault Tzanck, for diagnosing vesico-bullous lesions of the skin, such as herpes simplex. However, it is now being widely used for other dermatoses as well such as immunobullous disorders and cutaneous infections.<sup>[2,3,4]</sup>

The advantages of the test are that it is fast, simple and inexpensive. It causes minimal patient discomfort and gives a rapid confirmation of herpetic lesions of the skin. Pemphigus group of diseases can be confirmed by the presence of acantholytic cells. The smear is taken from a lesion by gently scraping it and transferring the obtained material onto a clean microscope slide. It is then air dried and routinely stained with a Romanowsky stain such as

May-Grunwald-Giemsa stain. If PAP stain is used, the slide should be immediately fixed in alcohol.<sup>[2,5]</sup>

Being the largest organ, the skin can be easily subjected to exfoliative cytology. However it is less routinely done as compared to other fields such as gynaecology, urology and endocrinology.<sup>[3,5]</sup> Studies regarding the utility of tzanck smears are limited in Indian literature.

The aim of this study was to highlight the use of tzanck smear as a diagnostic tool in the diagnosis of cutaneous lesions, in our tertiary care institution.

## **Materials and Methods**

A retrospective analysis of all tzanck smears over a period of 2 years was carried out (January 2016- January 2018). The slides were collected from the archives of the Department of Pathology, in our institution.

Patients visiting the outpatient department, in the Department of Dermatology and suspected of having cutaneous infections such as herpes simplex, herpes zoster, varicella, pemphigus groups of disorders etc. were included in the study. The detailed clinical histories and provisional

diagnosis of all the patients were taken. The ages of the patients ranged from 4 years to 75 years.

Tzanck smears were prepared by gently scraping from the base of a recent lesion such as blister or vesicle. Samples were taken from a fresh vesicle, in cases of suspected viral infection. In case of the other lesions, the roof of the blister was opened, and the floor of the lesion was scraped with using a scalpel. The obtained material was smeared onto a single clean microscopic slide. The smear was then air dried and stained using Leishmans stain.

Following staining, the slides were examined under light microscope by a cytopathologist. The smears were especially scrutinized for identification of acantholytic cells, inflammatory cells as well as any viral cytopathic effect.

## Results

A total of 70 Tzanck smears were performed, during the study period of two years. The patients, mostly presented with vesico bullous lesions. Clinically, majority of the cases were diagnosed as pemphigus vulgaris (41.4%), with herpes being the second most common diagnosis (35.7%). (Table 1)

The tzanck smears corroborated with the clinical diagnosis in 22 out of the 29 cases of pemphigus group of diseases. (Table 2). The smears displayed clusters of characteristic acantholytic cells, also known as Tzanck cells; which are large, round keratinocytes having a hyperchromatic nucleus, hazy or absent nucleolus, perinuclear halo, and moderate to abundant basophilic cytoplasm. (Figures 1a, 1b & 1c)

**Table 1**

Clinical diagnosis	Number of cases	Percentage
Pemphigus vulgaris	25	35.7%
Pemphigus foliaceus	04	5.7%
Bullous Pemphigoid	07	10%
Herpes Simplex	06	8.6%
Herpes Zoster	13	18.6%
Varicella	06	8.6%
Non- specific lesions	09	12.8%

**Table 2**

Tzanck Smear Findings	Number of cases	Percentage
Pemphigus vulgaris/ Pemphigus foliaceus	22	31.4 %
Herpes Simplex/ Zoster/Varicella	11	15.8 %
Non-Specific Conditions	37	52.8 %

The pemphigoid group of disorders, did not display any acantholytic cells, and showed non-specific findings such as mixed inflammatory infiltrate along with degenerating cells on tzanck smear.

There were 25 clinically suspected cases of herpetic infections (simplex/zoster/varicella).

These included 3 cases of herpes gingivostomatitis, one case of herpes labialis and one case of herpes ophthalmicus. The characteristic tzanck smear findings were observed in 11 of them. (Table 2). These cases demonstrated syncytial, multinucleated giant cells and few acantholytic cells. (Figures 2a & 2b). However distinction between herpes zoster, herpes simplex and varicella could not be made on cytology.

Histopathological analysis was done for 19 cases out of the 70, which were clinically suspected to be pemphigus vulgaris/ foliaceus. The tzanck findings correlated with 13 of these cases. Out of the remaining 6 cases, one case was diagnosed as infective dermatosis, whereas the other 5 cases, did not show any evidence of pemphigus histopathologically. One case of clinically suspected herpes simplex, was given a suggestive diagnosis of the same on tzanck smear, and positively correlated with increased serum Anti-HSV titres. This however, was not followed up with a skin biopsy, for the purpose of a confirmative diagnosis.

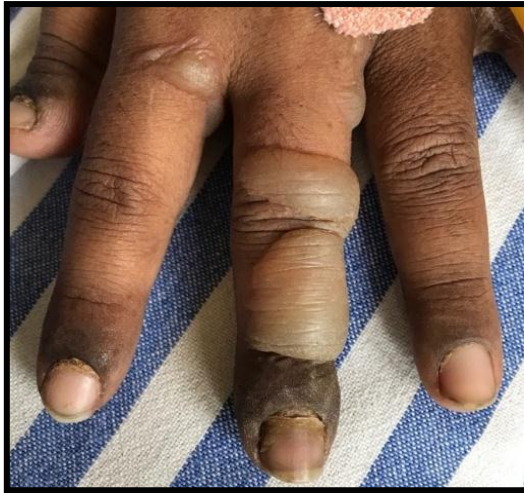

Figure 1.a

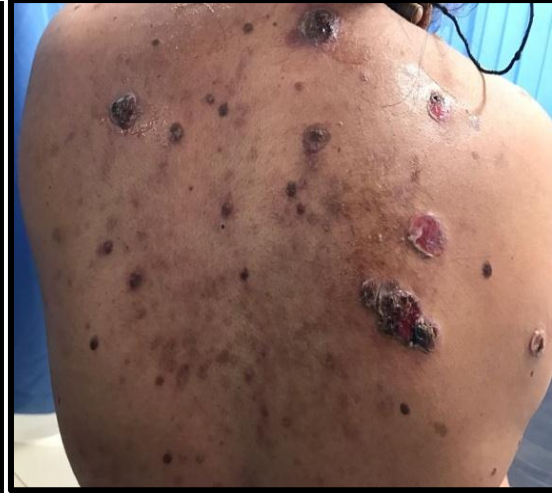

Figure 1.b

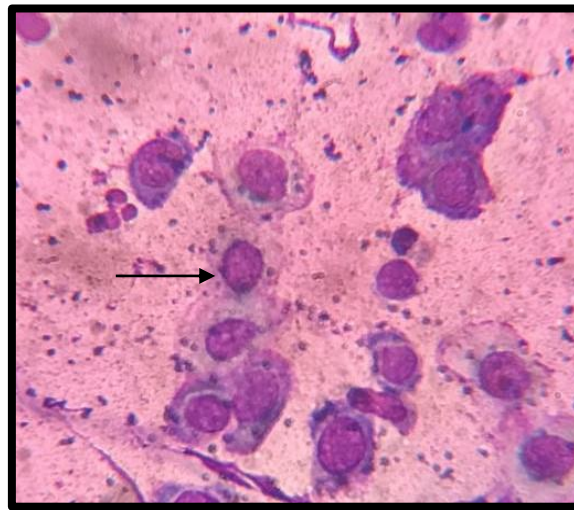


Figure 1.c

Fig 1.a, Fig 1. b: Cases of clinically suspected Pemphigus, Fig 1.c: Tzanck smears displaying typical acantholytic cells ( black arrow; 40x)

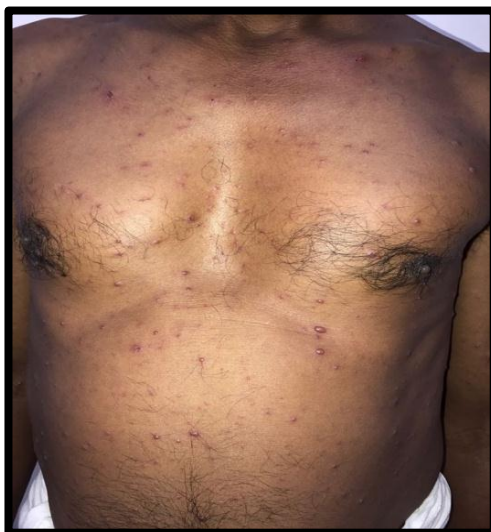

Figure 2.a

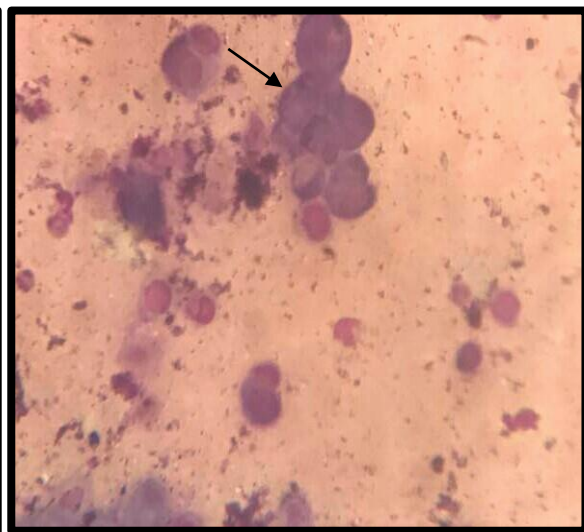


Figure 2.b

Fig 2.a: Case of clinically suspected varicella; Fig 2.b: Tzanck smears displaying multinucleated giant cells (black arrow) and acantholytic cells ( 40x).



## Discussion

Tzanck smear has a widespread use in substantiating the diagnosis of especially the pemphigus groups of disorders as well as herpetic infections. It is however, important to interpret tzanck smear findings, along with adequate clinical details, in order to maximally utilize this technique.

Vesico-bullous lesions of skin are a heterogeneous group of disorders, where most cases are due to a primary disorder such as pemphigus. However it can also occur secondarily due to a number of unrelated conditions, which require histopathological examination for confirmation.<sup>[6]</sup> Pemphigus group of lesions display typical acantholytic cells. In addition to this, presence of Sertoli rosette cells and streptocytes have also been described in literature.<sup>[7]</sup> Other bullous lesions such as pemphigoid, show an absence of acantholytic cells with a predominance of inflammatory infiltrate.<sup>[3]</sup> Similar findings were obtained in our study.

The findings in bullous pemphigoid are non-specific and the tzanck smear can be used to differentiate the same with pemphigus group of disorders.<sup>[8]</sup>

The use of direct immunofluorescence has been advocated to increase the specificity of this test.<sup>[3]</sup> Typical IgG deposits around the acantholytic cells in pemphigus was a finding reported in one study.<sup>[7]</sup> Shaheen et al reported IgG immunoreactant in 10% of pemphigus patients, followed by C3 and IgM.<sup>[9]</sup> In another study the positivity rate regarding the diagnosis of pemphigus group of lesions was 71.4%, 78.6%, and 71.4% using Tzanck test, histopathological examination, and direct immunofluorescence respectively.<sup>[1]</sup> Also in the same study, Tzanck smear gave a 100% specificity in the diagnosis of bullous pemphigoid.

Although viral infections are usually diagnosed based on clinical grounds, tzanck smears can significantly aid in its diagnosis.<sup>[3]</sup> Typical herpetic changes include multinucleation and crowding of the nuclei, nuclear moulding, peripheral margination of the nuclear chromatin, and ground glass appearance of the nuclei. Intranuclear inclusions with a prominent halo, ballooning degeneration and inflammatory cells can also be seen.<sup>[1,10]</sup>

In our study, the findings of multinucleation and acantholytic cells were seen in cases of clinically suspected herpetic infections.

The sensitivity and specificity of Tzanck smears has been compared with other techniques like polymerase chain reaction (PCR). Ozcan et al. reported a Tzanck smear sensitivity and specificity of 76.9% and 100%, in herpetic infections when compared with PCR in their study.<sup>[10]</sup>

The other uses of tzanck smears are to aid in the diagnosis of cutaneous infections like molluscum contagiosum and leishmaniasis, granulomatous dermatitis, genodermatoses

such as Hailey-Hailey disease, autoimmune disorders and tumours (basal and squamous cells carcinomas).<sup>[11,5,12]</sup> Even certain fungal infections such as *Candida* and *Aspergillus* can be identified based on the morphological appearance of their hyphae.<sup>[12]</sup>

The limitations of Tzanck smear are that representative material may not be obtained if slides are improperly prepared from a crusted vesicle. This can also result if the base of the lesion is not adequately scraped. Poorly preserved cells can sometimes resemble neoplastic cells, leading to a wrong impression.<sup>[13]</sup>

The main advantage is that Tzanck smear is an inexpensive, simple, and rapid test and does not require any specialized laboratory equipment. It is especially helpful in cases where biopsy is difficult to perform.<sup>[9]</sup>

In our study, the findings of the Tzanck smear correlated with the histological diagnosis in majority of the cases (13/19), and also corroborated well with the clinical verdict, proving it to be a valuable adjunct in a variety of dermatoses, especially vesico-bullous and herpetic lesions.

## Conclusion

Tzanck smears are helpful in giving a presumptive diagnosis of pemphigus, as well as differentiating pemphigoid from pemphigus disorders, which can facilitate early treatment for patients. Routine use of the test in addition to adequate clinical history can help sharpen the diagnosis of diverse skin lesions.

## References

- [1] A Yaeen, Ahmad Q M, Farhana A, Shah P, Hassan I; Diagnostic value of Tzanck smear in various erosive, vesicular, and bullous skin lesions; Indian Dermatol Online J. 2015 ; 6: 381–86.
- [2] Gupta LK, Singhi M K. Tzanck smear: A useful diagnostic tool. Indian J Dermatol Venereol Leprol 2005;71:295-9
- [3] Panwar H, Joshi D, Goel G, Asati D, Majumdar K, Kapoor N. Diagnostic utility and pitfalls of Tzanck smear cytology in diagnosis of various cutaneous lesions. J Cytol 2017;34:179-82.
- [4] Dey VK, Thawani M, Dubey N. Accuracy and reliability of Tzanck test compared to histopathology for diagnosis of basal cell carcinoma. Indian J Dermatopathol Diagn Dermatol 2015;2:8-13
- [5] Ruocco E, Brunetti G, Vecchio M D, Ruocco V. The practical use of cytology for diagnosis in dermatology. JEADV 2011;25: 125–29
- [6] Gupta V. Clinicoepidemiological study of vesiculobullous disorders in pediatric age group. Indian J Paediatr Dermatol 2015;16:9-16

- [7] Durdu M, Baba M, Seckin D. The value of Tzanck smear test in diagnosis of erosive, vesicular, bullous and pustular skin lesions. *J Am Acad Dermatol* 2008; 59:958-64.
- [8] Heera KP, Anoop TV, Ajaya Kumar S, Robins K, Rajiv S. The Significance of Tzanck Smear in Evaluation of Vesiculo Bullous Skin Lesions in Correlation with Clinical Diagnosis - A Cross Sectional Study. *International Journal of Contemporary Medical Research* 2017; 4:337-39
- [9] Shaheen J.A, Haroon T .S , Mahmood T , Hussain I. Evaluation of sensitivity of Tzanck smear in pemphigus. *Journal of Pakistan Association of Dermatologists* 2003; 13: 175-78.
- [10] Folkers E, Oranje A P, Duivenvoorden J N, Van Der Veen J P W, Rijlaarsdam J U, Emsbroekii J A. Tzanck smear in diagnosing genital herpes. *Genitourin Med* 1988;64:249-54
- [11] Brito MMC, Tarquínio DC, Arruda D, Costa RS, Roselino AM. Tzanck smears: an old but useful diagnostic tool. *An Bras Dermatol*. 2009;84(4):431-3.
- [12] Durdu, M, Baba M, Seckin D. More experiences with the Tzanck smear test: Cytologic findings in cutaneous granulomatous disorders. *J Am Acad Dermatol* 2009; 61: 441-50
- [13] Prabhala. S, Deshpande A K, Reddy M, Tanikella R. Study of Tzanck Smears over a Period of Six Months. *Journal of Evidence based Medicine and Healthcare* 2015; 2: 1365-71