

Study of Brachial Plexus and Its Variations Including Roots, Trunks and Cords in Formalin Preserved Cadaveric Human Brachial Plexuses

Swati Yadav^{*1}, Rajni², Manu Gupta³, Renu Mishra⁴

¹Post Graduate student, Saraswathi Institute of Medical Sciences,

²Assistant professor, Saraswathi Institute of Medical Sciences,

³Demonstrator, Saraswathi Institute of Medical Sciences,

⁴Professor, Saraswathi Institute of Medical Sciences



Abstract:

Brachial plexus is a principal somatic nerve supplying upper limb. Variations involving brachial plexus are not uncommon and knowledge of same is important for anatomists, surgeons and radiologists.

Keywords: - Brachial plexus, Root, Trunk, Cord.

Background

Brachial plexus is a principle somatic nerve plexus supplying the upper limb situated in the posterior triangle of the cervical region and in the axillary region. The plexus is a result of union of anterior rami of inferior four cervical nerves (C5, C6, C7 and C8) and the anterior ramus of the first thoracic nerve (T1), with variable contribution from C4 and T2.

In normal anatomy, the brachial plexus is described to have roots, trunks, divisions, cords and terminal nerves [Bannister et al]¹.

Variations involving the brachial plexus are not uncommon and have been linked with factors influencing the mechanism of limb muscles and peripheral nerves development during embryonic life [Anjali et al]².

Knowledge of variations in anatomy is important to anatomists, radiologists, anesthesiologists and surgeons, and has gained more importance due to the wide use of computer imaging in diagnostic medicine.

Material & Methods

The study was conducted in the Department of Anatomy, SARASWATHI INSTITUTE OF MEDICAL SCIENCES ANWARPUR, HAPUR.

Case sample

Thirty-fourty human brachial plexuses (15-20 formalin preserved adult cadavers)

Instruments and chemicals used:

1. Scalpel
2. Blunt forceps
3. Fine forceps
4. Scissors
5. Bone cutter
6. Calipers
7. Scale
8. Gloves
9. Facemask
10. Acetone
11. Colored Paints (Yellow, Black & Red)
12. Painting Brush

Method

The brachial plexus was dissected on both sides in approx. 15-20 formalin preserved adult cadavers. Lateral side of the neck, axilla and arm was dissected to expose the entire extent of brachial plexus. The various components of brachial plexus were delineated by careful fine dissection. Adequate care was taken to preserve its relations to important surrounding structures. The brachial plexus was studied systematically, noting its manner of formation, branching pattern. Inter communications between nerves of the plexus were also noted and following parameters were recorded. **a)** Contribution of roots **b)** Manner of formation of trunks and cords and their variations.

Observations

The observations recorded in the present study pertained to the dissection of various components of human brachial

plexus. It focused on variations of brachial plexus in terms of manner of formation and branching pattern

Roots contributing: - In 46.7% cases, the brachial plexus was formed by the roots (C5, C6, C7, C8, and T1) followed by roots (C4, C5, C6, C7, C8 and T1) (40%).

Table 1 Roots contributing to brachial plexus

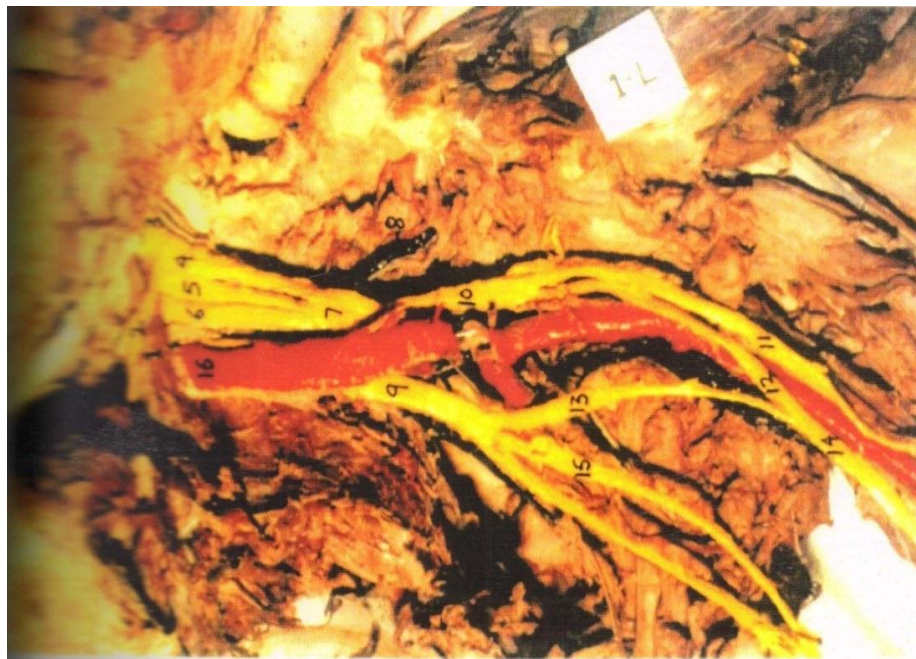
S.No.	Roots	Right	Left	Total
1.	C5, C6, C7, C8 and T1	53.3%	40%	46.7%
2.	C4, C5, C6, C7, C8 and T1	26.7%	53.3%	40.0%
3.	C4, C5, C6, C7, C8, T1, and T2	6.7%	6.7%	6.7%
4.	C3, C4, C5, C6, C7, C8 and T1	6.7%	-	3.3%
5.	C5, C6, C7, C8, T1 and T2	6.7%	-	3.3%

Formation of trunks:- The most commonly observed arrangement with regard to formation of trunks (in 70% cases) was that C5 and C6 roots unite to form the upper trunk; C7 root continues as middle trunk whereas C8 and T1

roots join to form the lower trunk. In the next pattern (16.7%), the upper trunk united with middle trunk to form a common trunk. Further, in 10% cases C5, C6, and C7 roots were found to unite forming a common trunk.

Table 2 Formation of trunks

S. No.	Manner	Right	Left	Total
1.	C5 and C6 roots join to form upper trunk. C7 root continues as middle trunk. C8 and T1 roots join to form lower trunk	80.0%	60.0%	70.0%
2.	C5, C6, C7 roots join to form common trunk. C8 and T1 roots join to form lower trunk	6.7%	13.3%	10%
3.	Upper trunk unites with middle trunk to form common trunk. C8 and T1 roots join to form lower trunk	13.3%	20.0%	16.7%
4.	Upper, middle and lower trunks unite to form a single cord	-	6.7%	3.3%



- 1-scalenus anterior muscle
- 2-phrenic nerve
- 3-C4 contribution
- 4-C5,5-C6,6-C7
- 7-common trunk
- 8-suprascapular nerve
- 9-medial cord

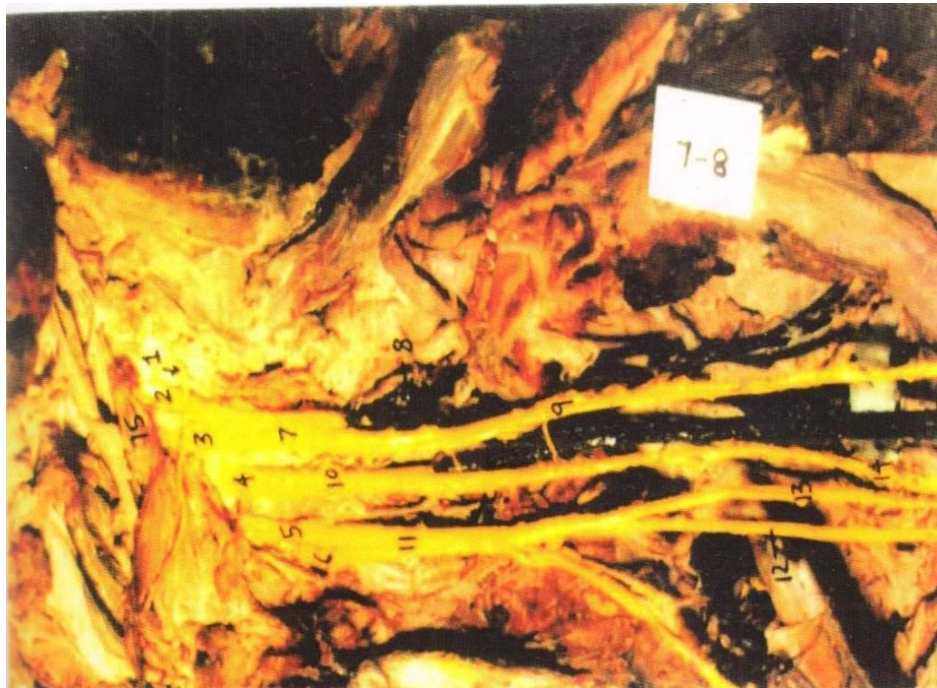
- 10-anterior division of CT
- 11-musculocutaneous nerve
- 12-lateral root of median nerve
- 13-medial root of median nerve
- 14-median nerve
- 15-ulnar nerve
- 16-subclavian nerve

Lateral Cord:-The anterior divisions of upper trunk and of middle trunk united to form the lateral cord in majority of cases (63.3%). However, in 26.7% cases the lateral cord

was formed by anterior division of common trunk. Further, in 6.7% cases, double lateral cords were observed.

Table 3 Formation of lateral cord

S. No.	Manner	Right	Left	Total
1.	Formed by the union of anterior division of UT and MT	80.0%	46.7%	63.3%
2.	Formed by the anterior division of common trunk	20%	33.3%	26.7%
3.	Double lateral cords; one formed by the anterior division of UT and the other by the anterior division of MT	-	13.3%	6.7%
4.	Anterior division of single cord representing fused medial and lateral cords	-	6.7%	3.3%



- 1-C4 contribution
- 2-C5, 3-C6, 4-C7, 5-C8
- 6-T1, 7-Upper trunk, 8-suprascapular nerve,
- 9-musculocutaneous nerve, 10-middle trunk, 11-lower trunk
- 12-ulnar nerve, 13-medial root of median nerve, 14-lateral root of median nerve
- 15-scalenus anterior muscle

Medial Cord:-The anterior division of lower trunk constituted the medial cord in majority of cases (90%).

Table 4 Formation of Medial Cord

S. No.	Manner	Right	Left	Total
1.	Formed by the anterior division of LT	93.3%	86.7%	90%
2.	Formed by the continuation of LT	6.7%	6.7%	6.7%
3.	Anterior division of single cord representing fused medial and lateral cords	-	6.7%	3.3%

Posterior Cord:-In majority of cases (63.3%), the posterior cord was formed by the union of posterior division of all the three trunks i.e. upper, middle and lower. However, in 26.7% cases, the posterior division of common trunk was

found to unite with posterior division of lower trunk. Further in 3.3% cases the posterior cord did not receive any contribution from the lower trunk.

Table 5 Formation of Posterior Cord

S. No.	Manner	Right	Left	Total
1.	Posterior divisions of all the three trunks (UT, MT and LT) unite	73.3%	53.3%	63.3%
2.	Posterior division of common trunk (CT) unites with posterior division of LT	20.0%	33.3%	26.7%
3.	Posterior division of UT joins with the posterior division of MT	-	6.7%	3.3%
4.	Posterior divisions of UT and MT unite with a small contribution from C8 root	6.7%	-	3.3%
5.	Formed by posterior division of single cord	-	6.7%	3.3%



1-C5,2-C6,3-C7,4-C8,5-T1(first thoracic root),6-upper trunk,7-middle trunk,8-lower trunk,9-Ulnar nerve,10-median nerve,11-musculocutaneous nerve ,12-coracobrachialis muscle ,13-subclavian artery,14-axillary artery

Discussion

The present study was aimed at investigating the anatomy of brachial plexus in terms of variation.

In the present study the brachial plexus composed of roots (C5, C6, C7, C8, and T1) was observed in 46.7% cases,

while contribution by roots (C4, C5, C6, C7, C8, and T1) was found in 40% cases. These findings are at variance with earlier reports [Lee HY et al] [Urbanowicz Z et al]^{3,4}. The contribution from the fourth cervical root was found in 50% cases in the present series. These observations are well in accordance with earlier reports [Kerr AT et al] [Senecail B et al]^{5,6}.

Table 6 Roots contributing to brachial plexus (comparison of different reports)

S. No.	Reference Number	Plexus composed of roots (C5, C6, C7,C8 and T1)	Plexus composed of roots (C4, C5, C6, C7, C8 and T1)	Plexus composed of roots (C5, C6, C7, C8, T1 and T2)
1.	3	77.0%	21.7%	-
2.	4	73.2%	26.1%	0.7%
3.	Present Study	46.7%	40.0%	3.3%

The contribution from the second thoracic root was observed in 10% cases. The frequency of this finding is at variance with the earlier reports [Eckhard C et al] [Paterson AM et al] [Weddell G et al]^{7,8,9}.

Considering the formation of trunks, the upper trunk was formed by the union of fifth and sixth cervical nerves in 70% cases in the present series. Its frequency was reported to be 89.71% earlier [Kerr AT et al]⁵. The middle trunk

formed by C7 root and the lower trunk formed by the C8 and T1 roots are the observations consistent with earlier reports. [Kerr AT et al] [Williams PL et al]^{5,10}.

In the present study, in 16.7% cases the upper trunk was found to unite with middle trunk and constituted a common trunk, a finding reported in 2.54% cases in an earlier document. [Kerr AT et al]⁵.

Lateral cord was constituted by the union of anterior divisions of upper and middle trunks in 63.3% cases. Further in 26.7% cases the upper and middle trunks united to form a common trunk and its anterior division formed an equivalent of lateral cord. Thus, the lateral cord received contribution from upper and middle trunks in 90% cases. This observation is in quite agreement with an earlier report. [Kerr AT et al]⁵.

In the present study, the medial cord was formed by the anterior division of lower trunk in 90% cases. The frequency of this pattern of formation was reported as 94.85% in an earlier study. [Kerr AT et al]⁵.

Considering the formation of posterior cord, the posterior divisions of upper, middle and lower trunks contributed to its constitution in 63.3% cases of the present series, a frequency quite similar to an earlier document [Kerr AT et al]⁵. Further in 26.7% cases the upper and middle trunks united to form a combined trunk, whose posterior division joined with posterior division of lower trunk to form the posterior cord. Thus in the present series, the posterior cord received contribution from all the three trunks in 90% cases.

Knowledge of Variations in relationship of nerves of brachial plexus is of paramount importance while performing radical neck dissections and surgical operations in axilla and arm.

Conclusions

Most frequently the plexus is contributed by roots (cervical fifth, sixth seventh, eight and thoracic first). The contribution from the fourth cervical root is found in 50% cases, whereas the plexus received the second thoracic root in 10% cases only. The variation in the manner of formation of trunks could be categorized into four groups. The most common pattern exhibited the formation of three trunks in the classical manner. The contribution from the sixth and seventh cervical roots is seen most frequently. The upper trunk forms the source of nerve of subclavius and suprascapular nerve in majority of cases.

Conflicts of interest: - None

References

- [1] Bannister LH, Berry MM, Couins P, Dyson M Gray's Anatomy: - The anatomical basis of medicine and surgery 38th ed Edinburgh London: Churchill Living Stone 2000 P. 1267.
- [2] Anjali Aggarwal K, Harjeet K, Sahni Daisy, Aditya Agrawal. Bilateral multiple complex variations in the formation and branching pattern of brachial plexus surgradiolanat 2009; 31; 723-31.

- [3] Lee HY, Chung IH, Sir Ws, Kang HS, Lee MS, Park SS. Variations of the ventral rami of the brachial plexus J Korean Med. Sci 1992;7 (1):19-24.
- [4] Urbanowicz Z. Brachial plexus roots in man. Ann Univ Mariae Curie Sklodowska Med 1994; 49: 47 - 55.
- [5] Kerr AT. Brachial plexus of nerves in man, the variations in its formation and branches Am J Anat 1918; 23:285-395.
- [6] Senecail B, Delmas A, Quereux P. Donnesmorphologiques et biometriquessurla constitution du plexus brachial de l'homme Bull Assoc Anat 1979; 63: 513-25.
- [7] Eckhard C. Lehrbuch der Anatomie Des Menschen 1862; 3.
- [8] Paterson Am. Adiscussion of some point of the distribution of the spinal nerves. J Anat and Physio. 1875; 30: 530-8
- [9] Weddell G. The anatomy of the thoracic outlet in relation to "Irritation" and compression of nerve trunks. Proc R Soc Med 1945; 38: 601.
- [10] Williams PL, Warwick R, Dyson M, editors Gray's anatomy, 23th edh London : Churchill Livingstone; 1999:1130-2
- [11] Alexander JH, Hamonnet O, Lacert P, Moulin AM, Arch Anat path 1968; 16.
- [12] Tsikaras PD, Agiabasis As, Hytirogloo PM. A variation in the formation of the brachial plexus characterized by the absence of C8 and T1 fibers in the trunk of median nerve. Bull Assoc Anat Nancy 1983 .Dec; 67 (199):501-5.

Corresponding Author-

Dr. Swati Yadav

Designation P.G. STUDENT, Saraswathi Institute of Medical Sciences, Ghaziabad, Uttar Pradesh

Email:-drswatiyadav2011@gmail.com