

Evaluation of Efficacy and Safety of Botox in the Management of Facial Wrinkles

Dr. Aditi Yadav

MDS (Oral and Maxillofacial Surgery)

Senior resident, Dental department, Government Medical College, Azamgarh

Dr. Manoj Goyal

MDS, MSc. (Maxillofacial Surgery)

FDSRCS (England), MBA (Hosp. Admin), Dean (Faculty), Professor & Head

Dr. Adarsh Tripathi

MDS (Oral and maxillofacial surgery)

Sarayu Clinic, New Delhi

Dr. Ajay Verma

MDS (Oral and maxillofacial surgery)

Dr. Gayatri Kumari

MD Anaesthesia

Assistant Professor, Department of Anaesthesiology, Government Medical College, Azamgarh

Dr. Abhijeet Nigam

MDS (Oral and maxillofacial surgery)

Dental tree clinic, Ghaziabad

Dr. Nidhi Bhatia

MDS (Periodontology and Implantology)

Sarayu Dental Clinic, New Delhi

Introduction

Throughout the evolution of aging, fine lines, facial wrinkles and texture have been persistent concerns for women. Some research reveals that this concern is legitimate and related to self-image and age related discrimination. There are a number of different causes of these fine lines and facial wrinkle lines, such as aging, sun exposure gravity and chronic pulling of mimetic muscles and hyperactive muscles on the face. Among these, pulling by mimetic muscles on the skin not only involves facial expression but also has a great role in forming facial wrinkle lines as a result of repetitive action, such as dynamic or hyperkinetic wrinkle lines. Hyperkinetic/ dynamic/long term facial wrinkles seem to contribute to the cause of many undesired facial rhytides and furrow and to the development of soft tissue ptosis in many facial regions. This can occur naturally over time and is identified by certain biochemical, histological and physiological changes that are enhanced by environmental exposure.^[1]

The main factors accelerating the process of aging include hereditary factors, smoking and ultraviolet radiation. These

dynamic process cause skin changes include skin sagging, fine wrinkling and deepening animation. Facial muscle pulls direct on the skin resulting in animation lines. In the upper face the skin muscle attachment accentuates the wrinkling process.^[2]

The pattern of facial wrinkles are predetermined during late childhood and carried out subconsciously through adulthood. Thus, repetitive muscle actions lead to hyperfunctional facial wrinkle lines. There are basically 4 patterns of facial wrinkles of upper face: 1) Horizontal frontal forehead wrinkling occurs during Brow lifting by the action of the frontalis muscle. 2) Deep vertical glabellar lines, by the action of corrugator supercilli muscles and the medial portion of orbicularis oculi when a person is frowning. 3) Horizontal lines at the frontal nasal groove are formed during frowning by the action of procerus muscle. 4) Lateral canthal lines (crow's feet) formed by the action of orbicularis oculi during squeezing.^[2]

The treatment for this change over time can be multiple, from skin care products, to energy based therapies (lasers,

light sources, and radiofrequency devices) to Botulinum toxins, dermal filler, fat graft etc.

Numerous procedures designed to treat hyper functional facial lines namely, rhytidectomy, liposuction, brow lift, dermabrasion, chemical peel, collagen injections do not address the underlying problems and are associated with various complications. Botulinum toxin A has been safely and effectively used for the treatment of various disorders, including cosmetic facial surgery for more than a decade in a safe and effective manner. Over a year there has been an increasing array of use of botulinum toxin in cosmetic facial surgery. Glabellar furrow lines, forehead furrows, crow's feet and other muscle groups, which are a result of pull on skin by underlying facial mimetic musculature; have been treated with the toxin.^[1]

Botulinum toxin acts at the neuromuscular junction by irreversibly inhibiting the release of acetylcholine. Cosmetic denervation of the hyper functional musculature using Botulinum toxin has gained growing popularity over the years. Since 1987, botulinum toxin A (BTX-A) has been used to denervate certain muscles of facial expression that are in part responsible for static facial rhytids. It has been applied to rhytids in the glabella, forehead, lateral canthal skin, and neck. Additional uses in Oral and Maxillofacial surgery include the denervation of hypertrophic or hyperactive masticatory muscles for cosmetic and functional purposes.^[3]

Clostridium botulinum was implicated over 100 years ago as the cause of muscle paralysis secondary to food poisoning. This gram positive anaerobic bacterium produces the most potent neurotoxin known to mankind. Seven distinct antigenic botulinum toxin (A, B, C, D, E, F and G) produced by different strains of *Clostridium Botulinum* have been described. Human disease is caused by five of these serotype (A, B, E, F and G). Type A is the strongest, followed by type E and F which are potentially of value in patients who developed antibodies to type A.^[4]

Clostridium botulinum has been in therapeutic use since the 1970's. Scott is largely responsible for the initial clinical use of botulinum toxin in the treatment of strabismus where botulinum toxin injected into extraocular muscles results in the selective muscle paralysis and improves ocular alignment. Since that time, numerous other conditions including dystonias i.e. (blepharospasm and torticollis), involuntary muscle hyperactivity i.e (hemifacial spasm, tremors and tics) and spasticity (as in multiple sclerosis and cerebral palsy) have been treated successfully with botulinum toxin.^[4]

Facial rejuvenation has been revolutionized by the use of botulinum toxin over the past 15 years with safe use by

clinicians using botulinum toxin type A producing excellent cosmetic results.^[4] Considering the past 50 years of cosmetic facial surgery, there has been no other treatment that parallels the efficacy, ease, expense, and patient satisfaction as has botulinum toxin.^[5] This study was done to evaluate the effect of Botulinum toxin type A in the management of facial wrinkles.

Aims and Objectives

Aims

To evaluate efficacy and safety of Botox in the treatment of the facial wrinkles.

Objective

1. Evaluation of safety and efficacy of Botox in the management of facial wrinkles.
2. To evaluate patient satisfaction and longevity of effect of Botox.

Review of Literature

Blitzer A et al (1993)⁷ They evaluated 26 patients in the study, 24 patients had dystonic movement of the face as either a primary or secondary component, and two patients were treated for purely hyper functional lines. Botulinum toxin type A was injected via monopolar hollow-bone Teflon coated electromyography needle into the facial muscle associated with the hyper functional lines. Doses were divided into 1.25 to 10 U aliquots. The ages were 32 to 84 years with average age of 59 years. All the patients had an effect of toxin within the first 24 to 72 hours. The authors concluded based on this pilot study, botulinum toxin may be an important new option for the treatment of patients with hyper functional facial lines.^[4]

Edmund A, Pribitkin et al (1997)⁸ They did a study in which they included 23 patients, which were injected with up to 10.0 mouse unit (MU) of Botox into each corrugator muscle, for the EMG (electromyogram) guided study, 57 patients were injected under EMG guidance with an initial dose of 10.0 MU of Botox into each corrugator muscle. 11 patients who had persistent corrugator activity were reinjected with 10.0 MU of Botox injection of 10.0 MU of Botox into each corrugator muscle produced a satisfactory result in 12 patients, for the EMG guided study, 43 patients were satisfied with improvement after full abolition of corrugator or accessory lateral brow muscle activity.

David A. F, Ellis et al (1997)² According to the study, in a 15 month period, 23 patients with seven anatomical sites were injected. 23 patients had the lateral aspect and the inferior aspect of their squint lines injected and 26 patients had their glabellar frown lines injected. Significant improvement occurred to the average depth and length of

the glabellar frown lines. The subjective improvement by the patients was also significant. Regarding the crows' feet, the lateral canthal lines showed more improvement than the inferior lateral canthal lines because the latter had a greater components of zygomaticus and minor muscle, which contributed to the inferior lateral squint line. This study proved that botox is a safe, easy to perform and effective treatment modality for the elimination of hyperfunctional upper facial muscle action, which is responsible for wrinkling.

Matarasso S L (1998)³⁴ Clostridium botulinum type A exotoxin is one of the recent advances for treatment of the aging face. Due to the sudden and exponential surge in popularity, there is little precise consensus regarding its safety and efficacy.

Many of the reported complications associated with its aesthetic use are few and anecdotal. As we gain more experience and long-term follow-up with this procedure, complications and their treatment can be better documented. As most of the salutary effects of Botulinum toxin are temporary, fortunately, so too are the complications associated with this form of therapy.

Ahn K Y, et al (2000)⁹ This study included 38 patients and 59 injection session from January of 1996 to 1997. They used Botox containing 100 U. Toxin was diluted with 4 ml of sterile normal saline and yielded 2.5 U for each 0.1 cc. A dose of 5 to 10 U was used for each muscle. Age range from 26 to 56 years. There were 33 women and 5 men were included in this study. 32 of the patients were followed from 3 months to 12 months after injection. The number of injection session that was performed on each patient was as follows: one session, 23 patients two sessions, 10 patients, three sessions 4 patients four sessions, 1 patient. Nearly all patients showed effects from toxin within the first 72 hours. The most common duration of effective response was about 4 months, but the duration exceeded 5 months for 8 patients. After the response, it took about 1 or 2 months to recover completely. Response after injection was as follows: 2 patients felt unsatisfied, 5 patients felt improved and 25 patients retained only slight lines. None of the patients experienced a complete removal of wrinkle lines. No systemic side effects were noted.

Carruthers A J, Nicholas J et al (2001)¹³ This study was conducted to evaluate the efficacy and safety of BTX-A treatment of glabellar lines. Patient with moderate to severe glabellar lines at maximum frown received intramuscular injection of 20U BTX-A or placebo into 5 glabellar site. Patients were followed up for 120 days after injection. Outcome measures were physician rating of glabellar line severity at maximum frown and rest, patient assessment improvement, and vital sign and adverse event monitoring.

BTX-A injections were safe and effective in reducing the severity of glabellar lines.

Timothy C F, Carruthers A et al (2002)¹³ This study advocated the use of ultra-fine II short needle 0.3cc insulin syringe as an optimal method of delivering precise units of botulinum toxin to the underlying musculature for cosmetic treatment of the aging face. The syringe is design for use with insulin supplied as 100 units of insulin per cubic centimetre. When 1 ml of 0.9% saline is added to a 100 unit vial of Botox, the BOTOX is reconstituted to 100 ml. Therefore a specific dose of Botox can be delivered without excess volume. The use of smaller volume for injection ensures accurate placement and minimizes diffusion of toxin and side effects.

Jennifer C, Christian C J, Alan M (2002)⁴ This study focused on updates of botulinum toxin for facial aesthetics, there are three source of botulinum toxin commercially available. Type A botulinum toxin include botox (Allergan, Irvine ect) and Disport (Ipsen limited, U.K.) one type B botulinum toxin is currently available.

The FDA approved Botox for facial wrinkle in April 15; 2002. The botulinum toxin has revolutionized the treatment of facial lines with an incomparable safety record over the past 14 years.

Semchyshyn N, Sengelmann RD (2003)¹¹ Botulinum toxin A is well documented as a useful therapy for smoothing up dynamic facial rhytides of the upper face. Most controlled studies have focused on the treatment of glabellar frown lines, horizontal forehead lines, and crow's feet. Reports of botulinum toxin A use in the lower face are few and anecdotal. The authors presented their experience using botulinum toxin A in the lip as a treatment of vertical perioral rhytides, which resulted in the added cosmetic benefits of lip eversion and enhanced lip fullness. Eighteen patients were injected with botulinum toxin A into the vertical lip rhytides. The effect of treatment was evaluated at 2 to 3 weeks after procedure. Smoothing of hyper functional lines and upper lip fullness/eversion was observed in patients treated with perioral botulinum toxin A injections; 72% of patients continued treatment. In select patients, perioral botulinum toxin A results in amelioration of perioral rhytides and enhancement of lip fullness and lip eversion.

Carruthers J, Carruthers A (2003)¹³ Botulinum toxin type A (BOTOX formulation) is used extensively for smoothing up hyperkinetic lines in the upper face. The use of botulinum toxin for aesthetic indications in the mid and lower face and neck is now becoming increasingly popular. Procedures and outcomes are described for the primary and adjunctive use of botulinum toxin. Cosmetic treatment with

botulinum toxin successfully changes the contour of the palebral aperture; smoothes lines, including "bunny" lines, perioral rhytides, and horizontal neck lines; softens creases, including the mental crease and melomental folds; and alleviates facial asymmetry and nasal flare. The doses of botulinum toxin used in the mid and lower face are generally lower than those used in the upper face. Caution must be used in injecting botulinum toxin in the perioral area to avoid an incompetent mouth. Botulinum toxin treatment is valuable for aesthetic improvements in the mid and lower face and neck. In some areas, particularly the perioral region, the use of botulinum toxin in combination with other therapeutic modalities provides optimal results.

Boris Sommer et al (2003)¹⁰ In this pilot study, 30 patient who were treated with BTX-A within the last three months answered a standardized questionnaire. The item assessed were attitudes of beauty and body, satisfaction with treatment outcome, and general quality of life. The mean age was 45.0 +- 9.2 years in which 90% were women and 10% were men. More than 80% of the patients answered that the treatment had been beneficial to them. All patients would recommend treatment completely or mostly. Only a very small part of the patients was moderately stressed by the treatment. Injection with BTX-A was a satisfying and well tolerated treatment of dynamic facial lines for all patients in this study.

Conner M S, Vasiliki K et al (2003)¹¹ Aging in the upper third of the face manifests as rhytides and ptosis of the frontal, glabellar, and brow region. Frown lines may occur even in younger individuals as a result of habitual or dynamic forehead muscle hyperactivity. Multiple treatment options have been advocated to address forehead rhytides and brow ptosis. This article review 3 of the more commonly used treatment options: collagen, botulinum toxin, and surgical forehead lifting. Additionally, an algorithm was proposed as a guideline for selecting the most appropriate option for a given condition.

Alster T S, Lupton J R et al (2003)²³ Botulinum toxin type B (BTX-B; Myobloc) has recently been introduced for the treatment of dynamic rhytides. This serotype is structurally similar to botulinum toxin type A (BTX-A; Botox) and appears to produce equivalent muscular paralysis. Because of the fact that some patients may become resistant to the effects of BTX-A with its continued use or may require large doses of type A to exert adequate muscular paralysis, the use of BTX-B may prove beneficial in these cases. To determine the effect of BTX-B on glabellar rhytides refractory or showing decreased clinical effect to treatment with BTX-A. Twenty females (mean age, 43 years) with vertical glabellar rhytides showing decreased or negligible clinical effect to BTX-A were treated with intramuscular injections of BTX-B. Five standardized intramuscular sites

(procerus, inferomedial corrugator muscles, superior middle corrugator muscles) received a total dose of 2,500 U. Patients were evaluated at pre-treatment and 48 to 72 hours, 1 week, and 2 and 4 months after injection.

All glabellar rhytides improved after treatment with BTX-B injections. Peak clinical effect was noted 1 month after treatment, with 50% of peak effect evident at the 2-month follow-up. Near complete dissolution of effect was seen at 4 months after treatment. Side effects were transient and were limited to moderate injectional pain and rare bruising and frontal brow tightness.

BTX-B is an effective treatment modality for glabellar rhytides refractory or exhibiting decreased clinical effect to BTX-A. The duration of effect using the 2,500 U dosing schedule described herein was shorter than that typically achieved after equivalent BTX-A injection.

Niamtu J III (2004)³ According to this study, botox A has been used to denervate certain muscles of facial expression that are partially responsible for static facial rhytides. with a greater than ever cosmetic awareness, BTX A treatment is used to treat rhytids in the glabella, forehead, lateral canthal skin, and neck. This article reviews the biochemical and physiologic properties of BTX A and application to cosmetic facial surgery in term of treatment options, techniques, case reports and potential complications. Botulinum toxin A has been shown to be a reliable and reversible means of treating wrinkles and lines from hyperkinetic muscles of facial expression.

Carruthers A and Carruthers J (2004)³¹ This study says Botulinum A toxin has been used for cosmetic purposes for over a decade. During that period it has created a place for the management for facial lines, wrinkles and expressions by the use of a paralytic agent. In the future manipulation of the molecule or its mode of delivery may further improve on the treatment and its longevity, but at the present BTX-A is firmly established as an important part of the cosmetic physicians practice. It was administered in accurate doses exactly the required treatment site. Little is available to go into circulation to cause generalized effects. Certainly at the doses most commonly used cosmetically side effects are limited to local spread of the toxin to unwanted muscle, causing for example, ptosis, and effects of the injection such as bruising and pain.

Vartanian J, Steven H D (2004)³³ The excellent safety profile of Botox is illustrated by the paucity of irreversible medical complications that have been documented over the last 20 years. The reversible, short-term, and localized effects of Botox are reflected in the observed complications, which also tend to be localized. The aesthetic application of botulinum toxin type A is a safe treatment modality;

nevertheless, complications can occur as a result of patient- and physician related factors. Fortunately, adverse effects and undesirable sequel after Botox injections (pain, and bruising ect) are temporary and reversible. No reports of life-threatening allergic or urticarial reactions have been reported with facial Botox applications.

Maio D M (2004)¹⁸ Plastic surgery is a rapidly growing field, particularly the use of less invasive procedures such as biodegradable dermal fillers and botulinum toxin. Aging is a complex process involving two important factors: volume loss throughout the face, and repetitive muscle movements that cause wrinkles and folds. Dermal fillers work by providing support for facial structures, whereas botulinum toxin reduces the mimetic effects. In combination, these products can be used effectively to reshape and rejuvenate the face and neck. Dermal fillers can be used throughout the face to raise the eyebrows, fill the tear trough, reshape the nose, lift the nose tip, fill nasolabial folds and oral commissures, fill the cheeks, raise the cheekbones, reshape the jaw line, and rejuvenate the neck area. This "minimal approach" offers a faster, less painful, and less costly alternative or complement to surgical facelifts. A variety of biodegradable injectable products are currently available, the most common of which are collagen or hyaluronic acid-based. Using these products in combination takes advantage of their hydrophobic and hydrophilic properties and can provide better and longer-lasting results. The addition of botulinum toxin can further extend the duration of results by reducing the mimetic stress that can break down the polymers. With regular maintenance treatments, the minimal approach using dermal fillers and botulinum toxin can give patient a "whole new look" with a fast and relatively painless lunchtime procedure.

Cheng C M (2007)³⁶ Reported that Botulinum toxin type A injections are one of the most popular cosmetic procedures for diminishing the appearance of facial lines caused by habitual facial muscle contractions. Although the manufacturer's labeling recommends botulinum toxin only for the treatment of glabellar lines among adults younger than 65 years of age, there is widespread use of the toxin for other cosmetic purposes and for patients who may be older than 65. Evidence-based safety and efficacy data on botulinum toxin use in elderly patients is limited. However, given the age-related skin changes and multifactorial causes of wrinkles in the elderly, as well as the higher risk for potential side effects due to concomitant diseases and medications, a careful risk-benefit assessment should precede the decision to use botulinum toxin in the elderly patient.

Koenraad D B et al (2010)²² Botulinum toxin type A treatment is the foundation of minimally invasive aesthetic facial procedures. This article provides up-to-date

information on fundamental properties and mechanisms of action of the major approved formulations of botulinum toxin type A, summarizes recent changes in naming conventions (nonproprietary names) mandated by the United States Food and Drug Administration, and describes the reasons for these changes. The request for these changes provides recognition that formulations of botulinum toxins (eg, onabotulinumtoxin A and abobotulinumtoxin A) are not interchangeable and that dosing recommendations cannot be based on any one single conversion ratio. Several studies have reported safety profiles over repeated treatments or over the longer term in clinical practice. A retrospective single centre analysis provided data on 853 treatment sessions in 50 patients treated with onabotulinumtoxinA (median dose, 40 U). Patients were required to undergo a minimum of 10 treatments (range 10–30). The time period between the first and last treatments ranged from nearly 3 years to approximately 9 years. More than 50% of the sessions involved treatment of more than one upper facial area, although treatment of the glabellar area predominated. The median interval between treatments was 17 weeks. Of all the treatments, 99% did not result in any AEs. Altogether, 8 of the 50 subjects experienced 10 AEs. Of the 10 events, 5 were deemed treatment-related: bilateral eyebrow ptosis (1); right brow ptosis (2); right eyelid ptosis (3); and dysphagia. All were mild in severity and transient. The incidence of ptosis was approximately 0.47%/session.

Kang S M, Feneran A et al (2011)² Reported that there have been no long-term complications or life-threatening adverse effects related to botulinum toxin treatment for any cosmetic indications. Nevertheless, there are well-known, mild side effects of botulinum toxin treatment on the upper face, though most of them are self-limited with time. However, excluding brow ptosis, reports about site specific side effects are few and anecdotal. They experienced cases of exaggeration of wrinkles after botulinum toxin injection for forehead horizontal lines, and report them here. In their cases, new appearance of a noticeable glabellar protrusion following botulinum toxin injection on the forehead was observed in 2 patients. Also, a new deep wrinkle on one side of the forehead just above the eyebrow appeared in another 2 patients.

The exaggerated wrinkles nearly disappeared without treatment by week 4 in all subjects. These exaggerations of wrinkles may be caused by hyperactivity and overcompensation of untreated muscles. With the increasing availability of diverse botulinum toxin for cosmetic purposes, physicians and patients should be aware of this temporary change after therapeutic injections. They recommend explaining this possible effect prior to injection, for better understanding of treatment for cosmetic indications.

Stengel G, Bee E K (2011)²⁹ Botulinum toxin type A (BTX-A) preparations are widely used nonsurgical treatments for facial wrinkles. Higher doses of BTX-A are also used for therapeutic purposes in the treatment of conditions involving increased muscle tone, such as cervical dystonia. The phenomenon of antibody-induced treatment failure is well known in the therapeutic setting, but reports are also emerging following cosmetic use of BTX-A. This study described the case of a 41-year-old female nurse who developed secondary treatment failure during 6 years of BTX-A treatment for glabellar lines. After a good response to the first BTX-A injection, the intensity and duration of effect decreased after subsequent treatments. Antibody tests revealed a high titre of neutralizing anti-BTX-A antibodies. This case shows secondary treatment failure due to the production of neutralizing antibodies following administration of BTX-A formulations for cosmetic purposes and demonstrates that immunogenicity of BTX-A preparations is an important consideration, even in the cosmetic setting.

Chauhan D S, Cariappa K M et al (2012)¹ This study was sought to determine efficacy of botulinum toxin A (BTX-A) for the treatment of hyperkinetic lines of the face. Twenty three patients who were concerned for facial wrinkle and desiring correction were presented. This clinical study evaluated the post-operative results of 23 patients who underwent treatment for facial wrinkles with BTX. Among the patients included in the study, 20 were males and remaining 3 were females. The age of patient range from 27 to 46 (mean 34.69 years) and the treatment was done under 3 different session and divided into 3 treatment subgroup forehead, glabella and crows' feet. All the patients were followed up for a period of at least 6 months and graded for the response to treatment with BTX-A by the operator, observer and the patient independently using the facial wrinkle scale. The results showed that the treatment of facial hyperkinetic lines with BTA is associated with few adverse effects like pain on injection, transient headache, and mild change in facial appearance in subjects with high hair line which are not serious and thus safe. So the findings of this study support the use of BTA for the treatment of hyperkinetic lines of the face.

Flync T C et al (2012)¹² Botulinum neurotoxin type A preparations onabotulinumtoxinA (BOTOX®) (Cosmetic/Vistabel®), Allergan Inc.) and abobotulinumtoxinA (Dysport®)/Azzalure®/Reloxin® (Ipsen Pharma,) have been used for many years and are effective and well tolerated for facial esthetic procedures. However, advances are continually made in the esthetics field. New formulations that may exhibit reduced antigenicity are becoming available, such as incobotulinumtoxinA (Xeomin®/Xeomeen®) /Bocouture®; formerly known as NT 201, Merz Pharma),

which is a botulinum neurotoxin type A free from complexing proteins. In addition, lower facial procedures using botulinum toxin combined with fillers are becoming increasingly popular. Injection techniques and patterns are also evolving, with the aim of creating a more natural result and avoiding a "frozen" appearance. Moreover, the diversity of individuals requesting esthetic procedures is increasing, with growing interest from men and patients with a variety of skin types and colors. The uses of botulinum toxins for facial esthetics procedures continue to expand, with new techniques and formulations. The availability of products such as incobotulinumtoxinA may reduce the risk of neutralizing antibody development while maintaining the good efficacy and safety of existing formulations.

Kassir R, Kolluru R et al (2013)³⁰ A total of 85 patients with moderate to severe wrinkles in either the glabellar or Crow's feet area, or both, were given a single injection on day 0, with ABO (abobotulinumtoxinA) and ONA (OnbotulinumtoxinA) injected on opposite sides of the face. Follow-up assessments were done at 2 weeks, 1 month, 3 months, 4 months, and 5 months. The study end points were onset of action, change in degree of wrinkles, patient satisfaction, duration of effect, and adverse effects. Results of onset of improvement with ABO vs. ONA in the glabellar and crow's feet regions show higher percentage of patients with earlier onset improvement with ABO.

Tan M, Kim E et al (2013)²⁵ A pregnant patient received 62 units of botulinum toxin type A (BTX-A) for facial lines. Two weeks later, she found out that she was pregnant. Botulinum toxin is not expected to be present in systemic circulation following proper intramuscular or intradermal injection. Moreover, BTX-A, which has a high molecular weight, does not appear to cross the placenta. From the 38 pregnancies reported in the literature, including women who had botulism poisoning during pregnancy, exposure to BTX-A does not appear to increase the risk of adverse outcome in the fetus.

Prager W, Bee E K et al (2013)³⁵ They did a study to determine the efficacy, onset, and duration of action of incobotulinumtoxin A for the treatment of glabellar frown lines. In this single-arm, prospective, proof-of-concept study, 23 patients were treated with 25 U incobotulinumtoxinA, equally split between five injection sites in the glabella. Severity of glabellar frown lines was rated by an independent rater from standardized photographs using the validated Merz 5-point scale at several visits over 5 months following treatment. To assess patient satisfaction, patients completed a questionnaire before and 2 weeks after treatment. The percentage of responders at maximum frown 2-4 days after treatment was 95.2% and 85.0% when responders were defined as patients with ≥ 1 -point and ≥ 2 -point improvement on the 5-point

scale compared with baseline, respectively. At this time point, 84% of the maximum effect had occurred. The responder rate at maximum frown, according to both definitions, was 100% for at least the next two visits (days 8 ± 1 and 14 ± 2). At all visits, the change from baseline in the mean glabellar frown-line score at maximum frown was statistically significant, with on average an almost 1-point improvement from baseline 5 months after treatment. Incobotulinumtoxin A is an effective and well-tolerated treatment for glabellar frown lines, with a rapid onset of action and a long duration of effect lasting for more than 5 months.

Chauhan D S, Cariappa K M (2013)²⁷ This study sought to determine the efficacy of Botulinum toxin A (BTA) for the treatment of hyperkinetic lines of the face. Twenty three patients who were concerned for facial wrinkles and desiring correction were presented.

This clinical study evaluated the postoperative results of 23 patients who underwent treatment for facial wrinkles with BTA. Among the patients included in the study, 20 were males and remaining 3 were females. The age of the patients ranged from 27 to 46 years (mean 34.69 years) and the treatment was done in three different sessions and divided into 3 treatment subgroups of forehead, crow's feet, and glabellar wrinkles.

All the patients were followed up for a period of at least 6 months and graded for the response to treatment with BTA by the operator, observer and the patient independently using the facial wrinkle scale. The patient's satisfaction to the treatment was also noted on all the follow-up visits on the satisfaction scale and the results were subjected to statistical analysis using Kappa analysis, Chi-square test and T test. The results showed that the treatment of facial hyperkinetic lines with BTA is associated with few adverse events like pain on injection, transient headache, and mild change in facial appearance in subjects with high hair line which are not serious and thus safe. The findings of this study support the use of BTA for the treatment of hyperkinetic lines of the face although further studies with more sample size are required.

Kassir R, Kolluru A, Kassir M (2013)³² OnabotulinumtoxinA (ONA; Botox, Allergan, Irvine, CA) was discovered for cosmetic use in the mid-1980s for which it was FDA approved in April 2002. AbobotulinumtoxinA (ABO; Dysport, Valeant Pharmaceuticals International, Inc, Montreal, Quebec) was FDA approved in April 2009 for therapeutic and aesthetic uses. The most recent studies make a comparison between the two formulations; however, information is still lacking in comparison studies. In this study, we compare efficacy and safety of a single treatment of two preparations of botulinum toxin A in patients with

moderate to severe rhytides in the glabellar and crow's feet areas. A total of 85 patients with moderate to severe wrinkles in either the glabellar or crow's feet area, or both, were given a single injection on day 0, with ABO and ONA injected on opposite sides of the face. Follow-up assessments were done at 2 weeks, 1 month, 3 months, 4 months, and 5 months. The study end points were onset of action, change in degree of wrinkles, patient satisfaction, duration of effect, and adverse effects. Improvement with ABO vs. ONA in the glabellar and crow's feet regions showed higher percentage of patients with earlier onset improvement with ABO. Evaluator assessment showed ABO lasted longer after 3 months in a significant number of patients in both areas, 83% with ABO vs. 48% with ONA at 4 months in the glabellar area, and 65% with ABO vs. 47% with ONA at 4 months in the crow's feet area. Time to improvement showed earlier onset and longer duration of improvement in a higher percentage of individuals with ABO when compared with ONA. ABO provides a safe and effective alternative in a dose ratio of 2.5:1 and 3:1 in the glabellar and crow's feet area, respectively.

Materials and Methods

SOURCE OF DATA:

The study was conducted on 15 patients with wrinkles of the face. The cases were selected irrespective of their gender, caste and creed, from the department of Oral and Maxillofacial surgery, Santosh Dental College and hospital, Ghaziabad, NCR Delhi.

All these cases were evaluated clinically and informed consent was taken.

CRITERIA FOR THE SELECTION OF CASE:

A) INCLUSION CRITERIA

- Age criteria between 21 to 65 years were taken for research.
- Patients presenting with wrinkles of the upper face (glabella, forehead, or crows' feet etc.)
- Desiring treatment of the wrinkles and agreed to comply with the requirements of the study.
- Patients who were very much concerned for their fine lines and age related changes but they were not ready for any surgical treatment.

B) EXCLUSION CRITERIA

- Neuromuscular disorder e.g.: Myasthenia gravis etc.
- Reported allergy to components of drug.
- On medications like aminoglycosides, quinine, penicillamine and calcium channel blockers that would interfere with the neuromuscular function.
- Pregnancy, lactation, during the study period.

- Patients with systemic disorders like hypertension, diabetes mellitus, heart diseases etc.
- Any other condition or situation existed that would put the patient at significant risk.
- Psychologically unstable patients or who had unrealistic goal and reasons.

ARMAMENTARIUM

Armamentarium and material:-

- Sterile surgeon’s and patient’s gown
- Sterile masks and head caps.
- Sterile gloves.
- EMLA cream
- Marker
- Insulin syringes
- Normal saline or distilled water
- Botulinum toxin Type A
- Digital reflex camera

1) EMLA cream:-

Preoperatively we used EMLA cream on every patient at injection site for painless injection.

EMLA act as a local anesthetics

EMLA is a combination of 2.5% lidocaine and 2.5% priloca



Fig.1: EMLA

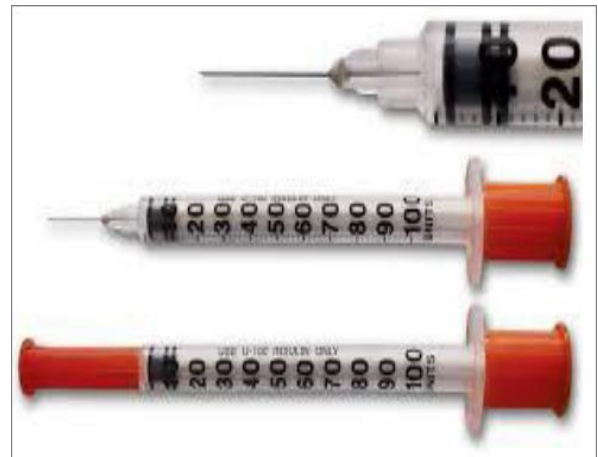2) We used ordinary eye pencil for marking on the target area before the treatment



Fig.2: Eye Pencil

3) Insulin syringe

- We used ultra-fine short needle 0.3-cc insulin syringe to inject BTX-A for facial wrinkles
- This syringe is designed for use with insulin supplied as 100U of insulin per cubic centimeter.
- The main advantage of this syringe was that it ensures accurate delivery of a specific number of units of botulinum toxin
- This syringe has four components: Cap, Needle, Barrel and Plunger



Figr.3a: Insulin Syringe



Figr.3b: Insulin Syringe

4) We used normal saline for mixing botox

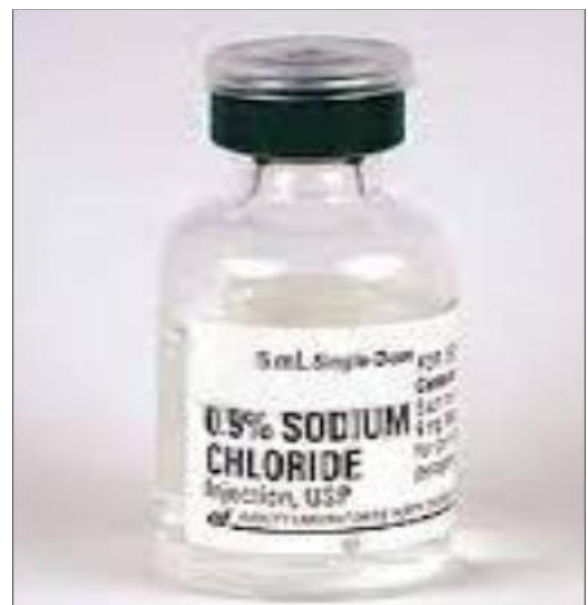

Fig. 4a: Normal Saline

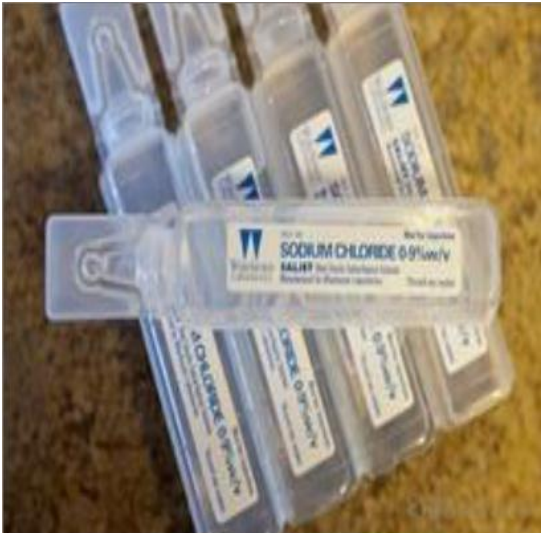

Fig.4b: Normal Saline

5) We used BTX A in this study

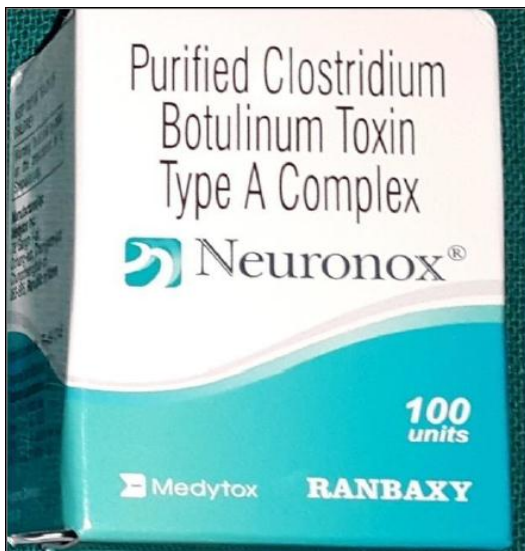

Fig.5:

6) In this study, we used digital reflex camera for every case.

Camera setting list:

- Camera - digital single lense reflex camera 10-15 megapixels
- Lenses - 28-80-mm zoom lens, lowest aperture 5.6
100mm macro lens, lowest aperture 5.6
- ISO - No higher than 800
- Focal length - 35-50mm
- Image format - JPEG; Fine
- Compression - medium compression
- White balance - set manually, adjust to the light used
- Exposure time - 1/60 to 1/250
- Aperture - 5.6 to 11
- Picture style - skin tone



DIGITAL SINGLE LENS REFLEX CAMERA

PRE-TREATMENT INSTRUCTIONS:-

- On the day of treatment, patient was advised not to put on any make-up.

Table 1: RECONSTITUTION AND HANDLING OF BOTOX1

PARAMETER	RECOMMENDATIONS
Diluents	preserver 0.9% saline (preferred)
Diluents	non-preserver 0.9% saline
Dilution method	2.5 ml of diluents for 100U vial. This implies 4U/ 0.1 ml or any convenient concentration to deliver required units per injection site
After reconstitution storage	-40-90 C for 3-10 days

MIXING TECHNIQUE OF BOTOX

When reconstituting the BTX-A, the saline should not be pushed into the vial with pressure but rather allowed to be drawn in carefully in the vial by the vacuum so as to avoid bubbling and frothing that can inactivate the toxin. The saline should not to be shaken; instead, the vial is gently rolled in between the palm.

METHODS

METHOD OF INJECTING BOTOX

- An analgesic cream was applied half an hour before giving injection
- 1ml insulin syringe with 30- 32 gauge fine needles were used for injecting Botox.
- The syringe was held between the index finger, the thumb was placed loosely on the plunger and the injection hand was supported with the little finger.
- Prior to the treatment the site of injection was scrub with alcohol or alcohol less antiseptic followed by chilling the site with ice.

- Knocking technique or rhythmical slapping on the patient's forehead before the injection was used to reduce the pain during injection.
- The number of injection sites was decided based on the severity of the wrinkles.
- Due to anatomic variance, each patient presents a unique combination of dynamic rhytides on animation, thus the injections were tailored to that specific anatomy.
- The site of injection was marked with an ordinary eye pencil.
- The needle was inserted gently and in a diagonal direction to the skin surface.
- Two finger of non-injecting hand were used to create a maximal distance between the muscular target parts and the orbital margin, allowing safe injecting.
- Direct injection technique was used in this study to inject Botox, in this technique the needle was inserted perpendicular to the skin. The botulinum toxin was injected into the belly of the target muscle, located beforehand by palpation.
- To ensure more accurate placement of the drug, the muscle can also be held in place between the thumb and index finger of the free hand and compressed lightly.
- Two units of the drug were injected per prick and the syringe was changed after three to four injections to prevent pain of injection due to blunting of the needle tip.
- In the forehead, the drug was injected at least 1cm above the eyebrow sparing the lower most wrinkle to prevent the chance of untoward diffusion into the upper eyelid causing ptosis and preserve the movement of the eyebrows.
- Laterally, the drug was injected not beyond the imaginary mid pupillary line to prevent lateral brow ptosis. The drug was distributed over the forehead by maintaining a distance of 1.5 – 2 cm between each injection site to allow for the diffusion of the drug.
- The injections in the lateral orbital region for the crow's feet was given at least 1 cm away from the

lateral canthus or at least 1.5 cm lateral to the bony lateral orbital rim.

- In the glabellar region the drug was injected at 5 sites. Each muscle received a minimum effective dose of 2U accounting to total of 10 U.
- Various doses have been employed to treat the glabellar lines ranging from 2 U to 7.5 U per muscle group based on the severity of the wrinkles.
- Minor superficial blood vessels may occasionally be punctured, causing small haematoma and areas can be cooled with ice.
- The patient satisfaction was evaluated at all the follow up visits based on the patient satisfaction scale for a period of 6 months.

POST- TREATMENT INSTRUCTION

- Patients were advised to apply ice over the treated area to reduce swelling and pain.
- Patients were recalled after 24 hours for follow up to evaluate the effect of injection.

CRITERIA FOR EVALUATION

Results were evaluated for clinical and photographic changes after treatment, till 6 months post treatment.

Evaluation of aesthetic outcome was done by following methods comprising of:

1. To accurately assess the patient's perception of the treatment result, rather than relying only on the clinician's perception of the postoperative outcome, using post treatment patient satisfaction questionnaire (PSPSQ)1;
2. To assess the patient based on MERZ6 scale.

I. 'Post-Surgical Patient Satisfaction Questionnaire' (PSPSQ);

- A set of 5 questions related to patient's perception were asked from each patient, one week post-operatively, to accurately assess the patient satisfaction.

Name of the patient:

Age/sex:

Date:

1) If you had to make the decision again, how likely would you be to undergo this same procedure?

1	2	3	4	5	6	7
Not Likely	Least Likely		Likely		Very Likely	Definitely

2) How likely would you be to recommend this same procedure to others?

1	2	3	4	5	6	7
Not Likely	Least Likely		Likely		Very Likely	Definitely

3) Considering everything, how satisfied are you now with the results of procedure?

1	2	3	4	5	6	7
very poor	average		good		excellent	

4) Overall, how accepting are you with any change in neuro-motor function of the associated structure of the injection site? (eyelid movement, facial expressions - which ever applicable)

1	2	3	4	5	6	7
very poor	average		good		excellent	

5) Overall, how accepting are you with any change in neuro-sensory function of the associated structure of the injection site? (eyelid movement, facial expressions - which ever applicable) .

1	2	3	4	5	6	7
very poor	average		good		excellent	

6) Overall, how accepting are you with overall appearance /aesthetic changes?

1	2	3	4	5	6	7
very poor	average		good		excellent	

7) Overall how much, has the procedure improved your self-confidence and personality?

1	2	3	4	5	6	7
very poor		average		good		excellent

8) Overall, how natural (or artificial) the corrected site appears to you?

1	2	3	4	5	6	7
very poor		average		good		excellent

9) How accepting are you with your current facial contour/symmetry?

1	2	3	4	5	6	7
very poor		average		good		excellent

10) Overall, how accepting are you with pain during injection?

1	2	3	4	5	6	7
very poor		average		good		excellent

Name of the patient-


Sign-.....

MERZ AESTHETIC SCALE


In this scale, we scored 0-4 on the basis of severity according to:

- A. Brow positioning
- B. Forehead lines- at rest
- C. At dynamic
- D. Glabellar lines – at rest
- E. At dynamic
- F. Lateral canthal lines- at rest
- G. At dynamic
- H. Lip wrinkles- at rest
- I. At dynamic
- J. Marionette lines
- K. Neck

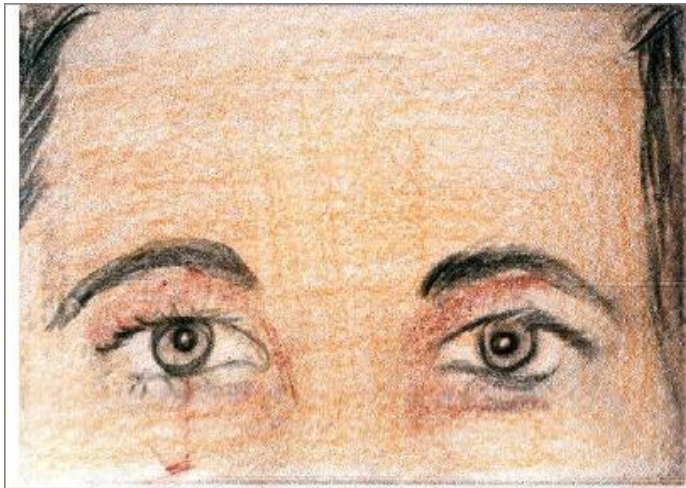
A) BROW POSITIONING




a. 0 High arch of the eyebrow



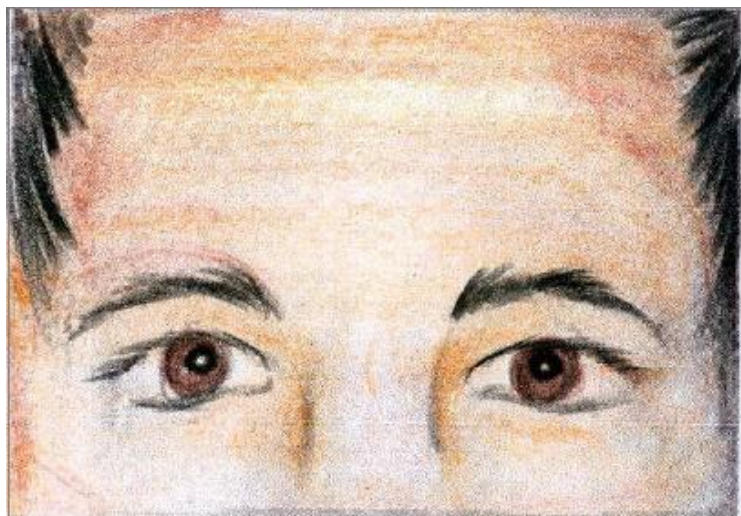
b. 1 Medium arch of the eyebrow



c. 2 Slight arch of the eyebrow

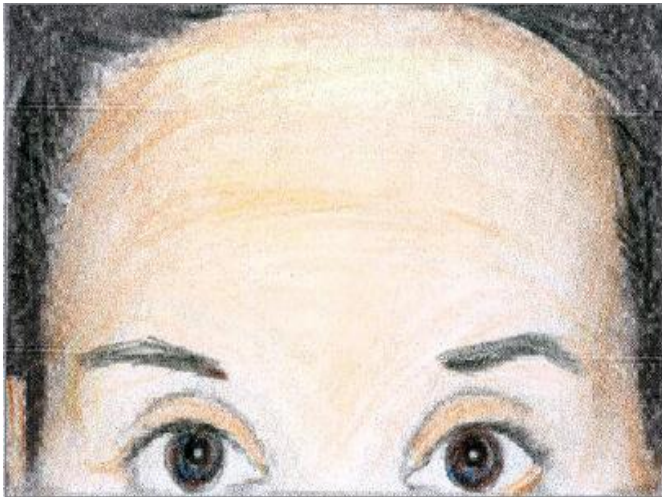


**d. 3 Flat arch of the eyebrow;
visibility of Folds; tired appearance.**

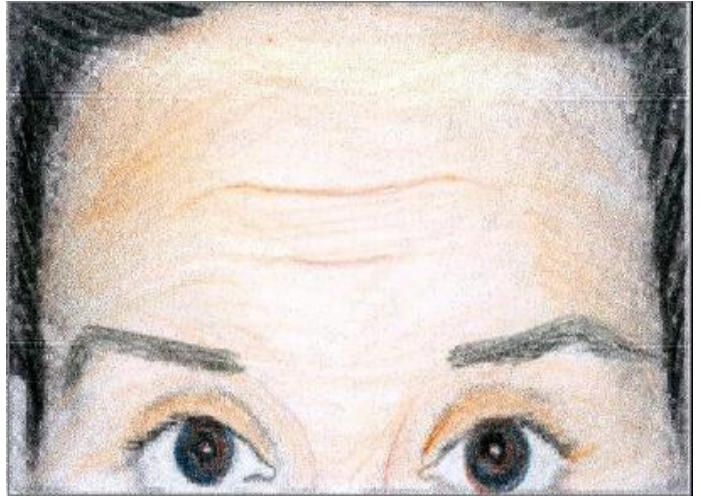


**e. 4 Flat eyebrow with barely any arch; marked visibility of folds; very tired appearance. Brow positioning
(Figure: 6 a, b, c, d, e)**

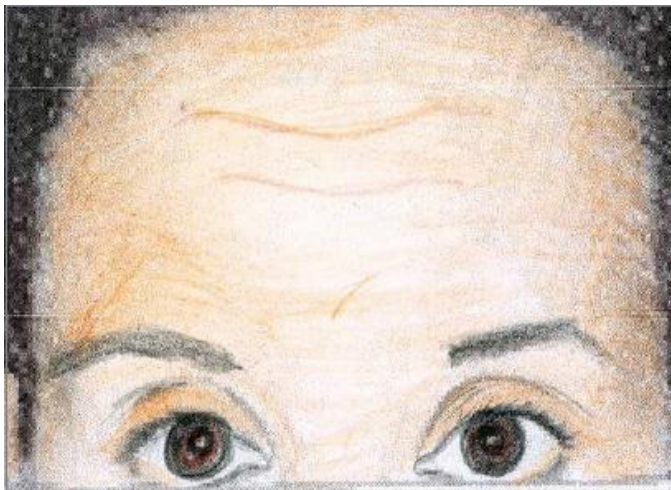
B) Forehead lines – at rest.



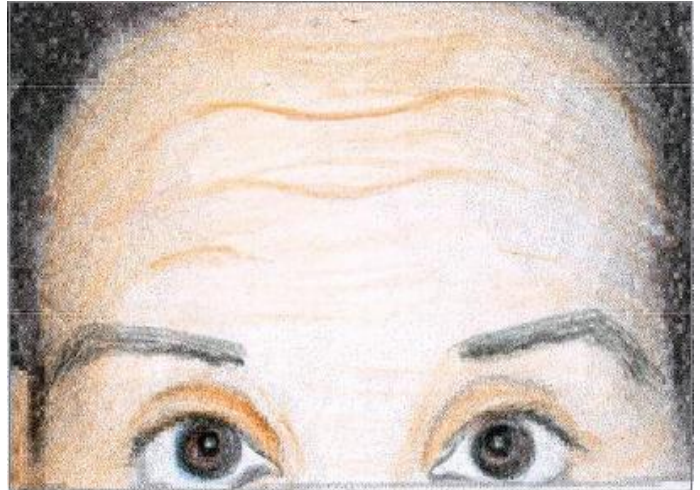a. 0 No lines




b. 1 Mild lines



c. 2 Moderate lines

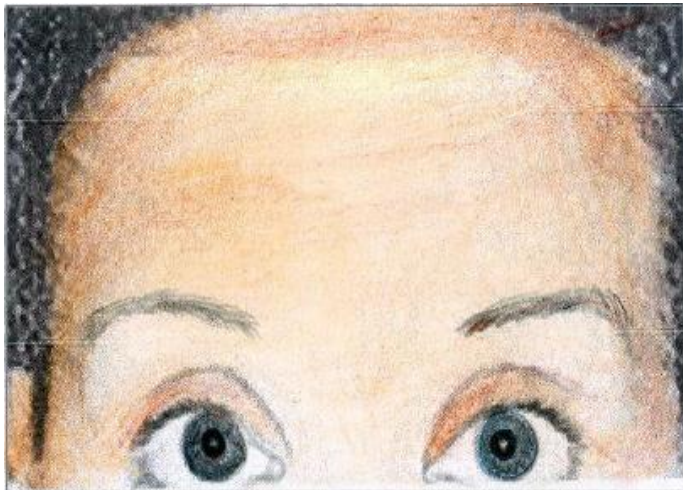

d. 3 Severe lines

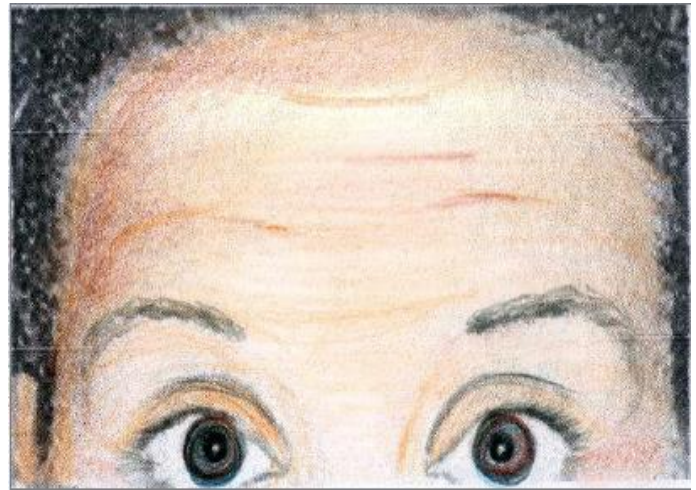


e. 4 Very severe line
(Figure: 7 a, b, c, d, e)

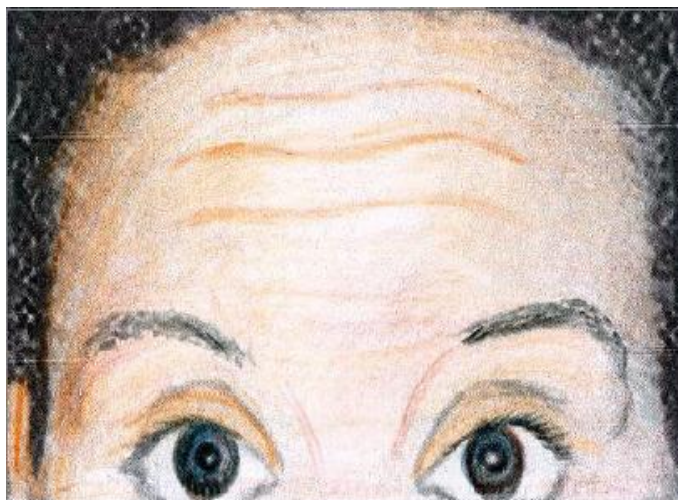
C- Forehead lines - dynamic.



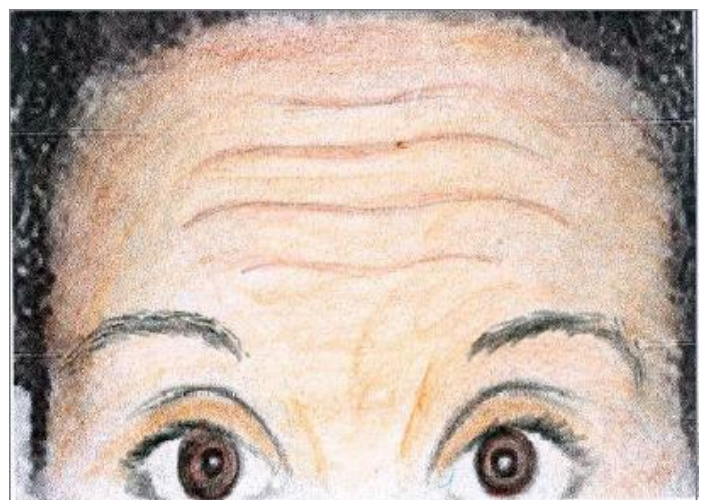
a. 0 No lines



b. 1 Mild lines



c. 2 Moderate line



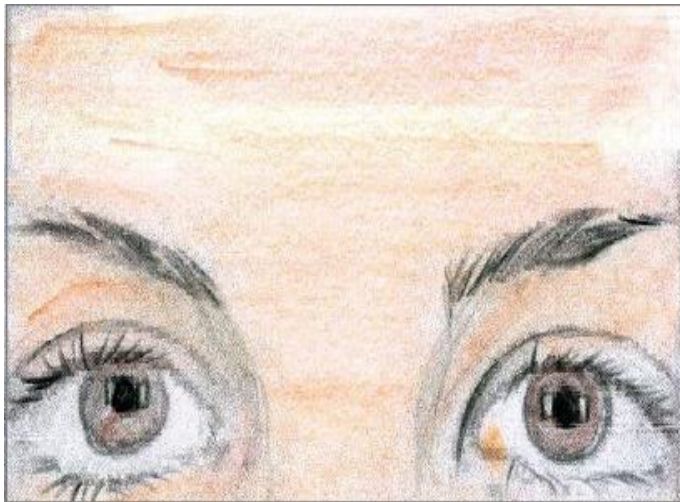
d. 3 Severe lines




e. 4 Very severe lines

(Figure: 8 a, b, c, d, e)

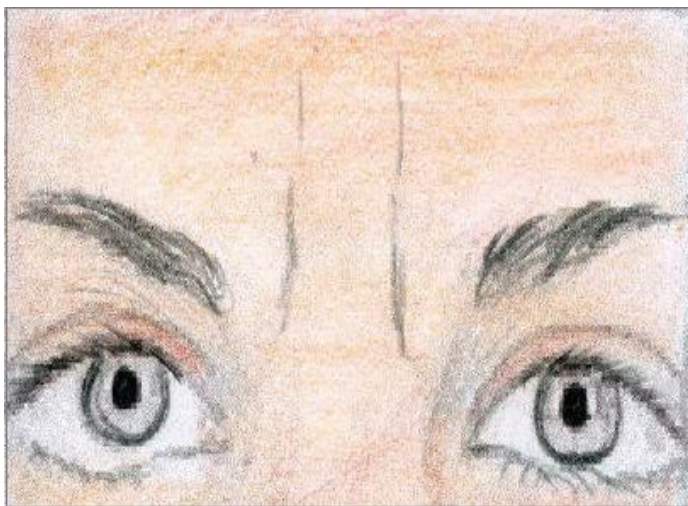
D- Glabellar line - at rest.



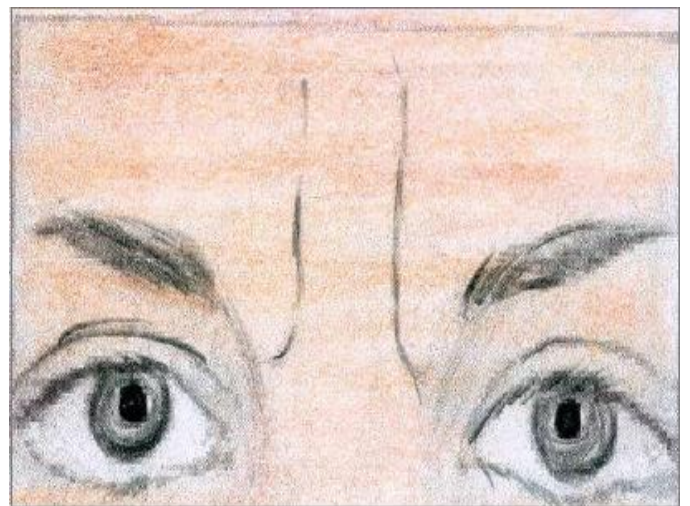
a. 0 No glabellar lines



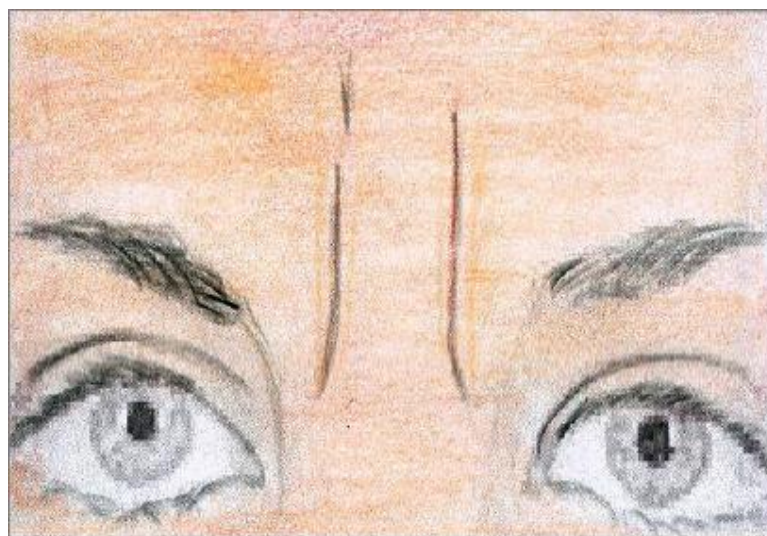b. 1 Mild glabellar lines



c. 2 Moderate glabellar lines



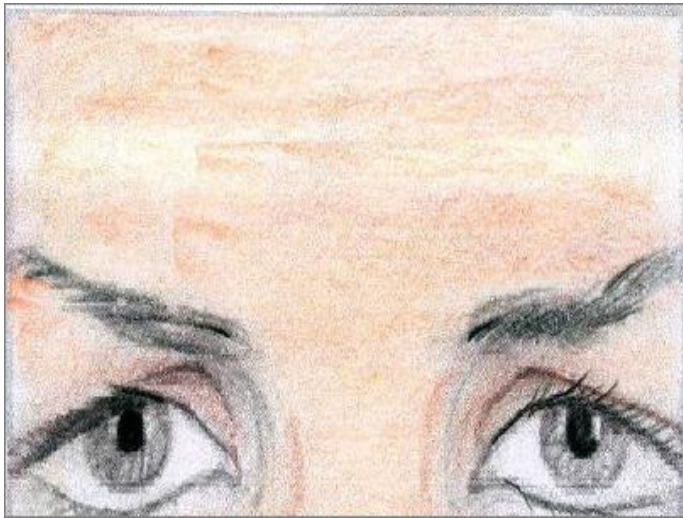
d. 3 Severe glabellar lines



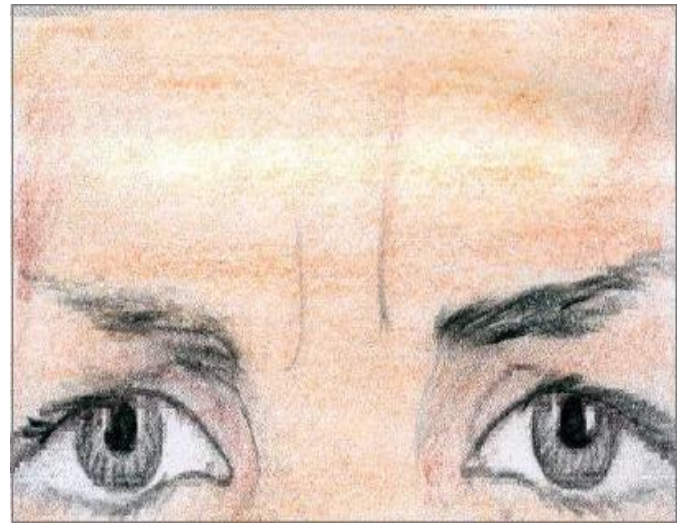
e. 4 Very severe glabellar lines

(Figure: 9 a, b, c, d, e)

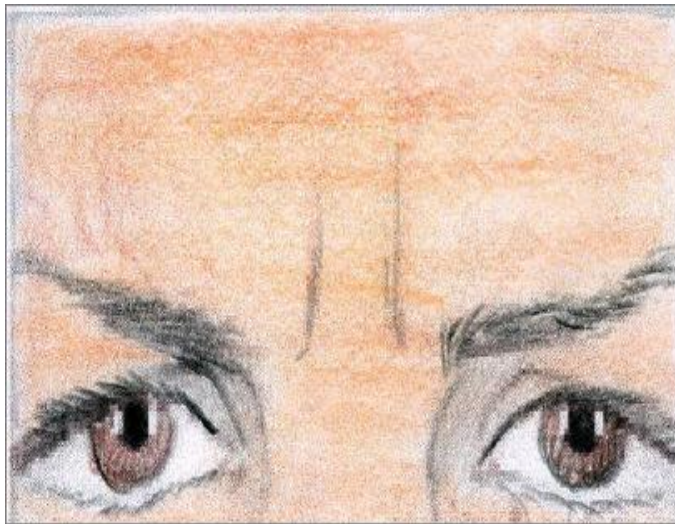
E- Glabellar line - dynamic



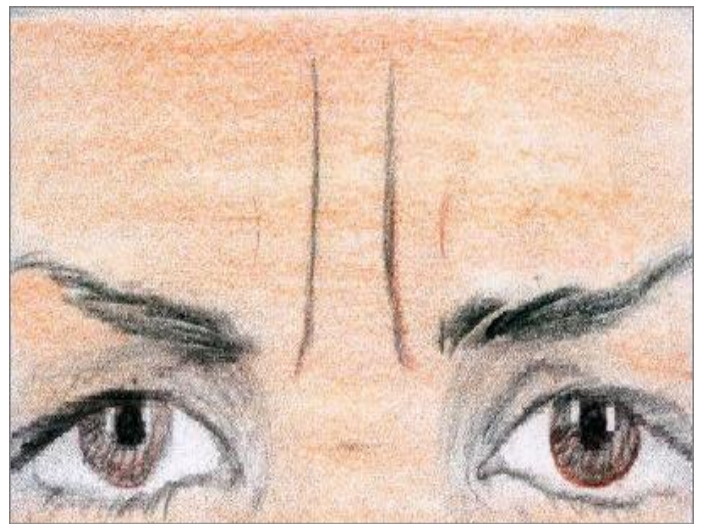
a. 0 No lines




b. 1 Mild glabellar line



c. 2 Moderate glabellar lines




d. 3 Severe glabellar lines



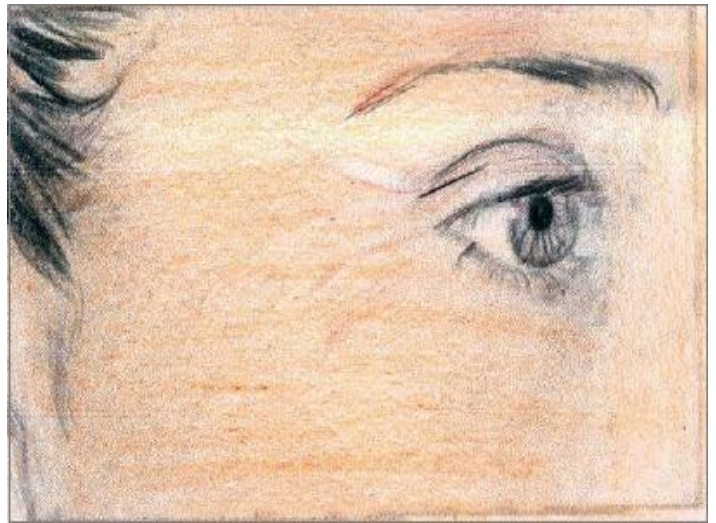
e. 4 Very severe glabellar lines

(Figure: 10 a, b, c, d, e)

F- Lateral canthal lines - at rest



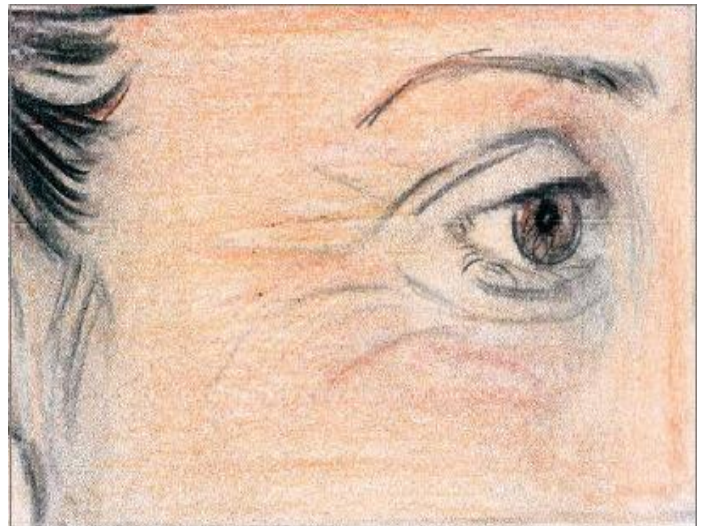
a. 0 No lines




b. 1 Mild lines



c. 2 Moderate lines




d. 3 Severe lines



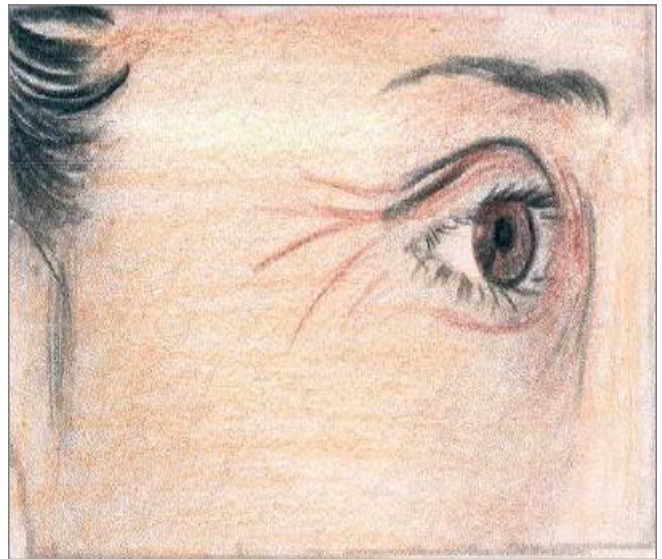e. 4 Very severe lines

(Figure: 11 a, b, c, d, e)

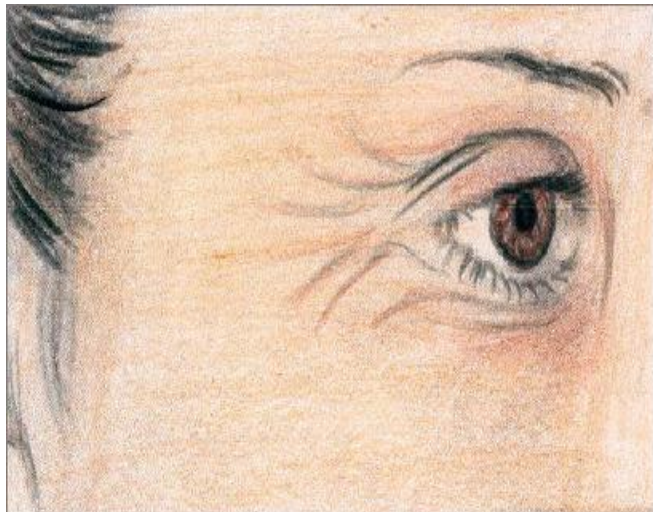
G- Lateral canthal line – dynamic.




a. 0 No lines




b. 1 Mild lines



c. 2 Moderate lines



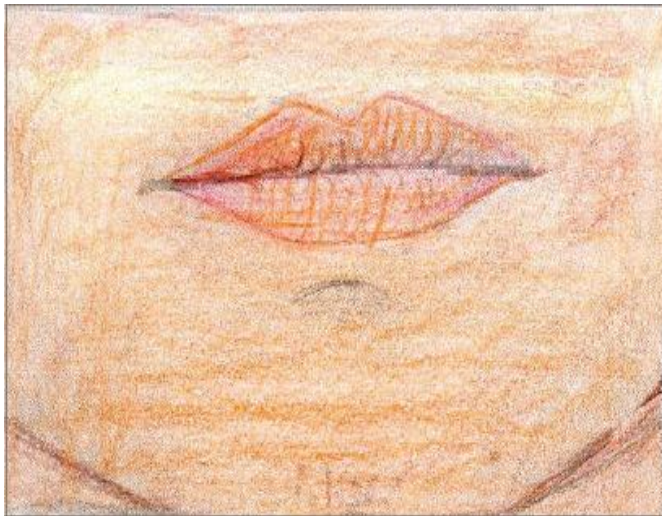
d. 3 Severe lines



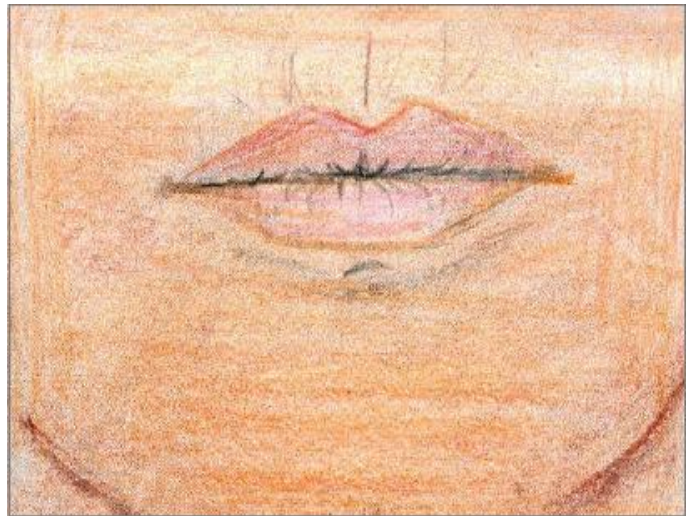
e. 4 Very severe lines

(Figure: 12 a, b, c, d, e)


H- Lip wrinkles – at rest.



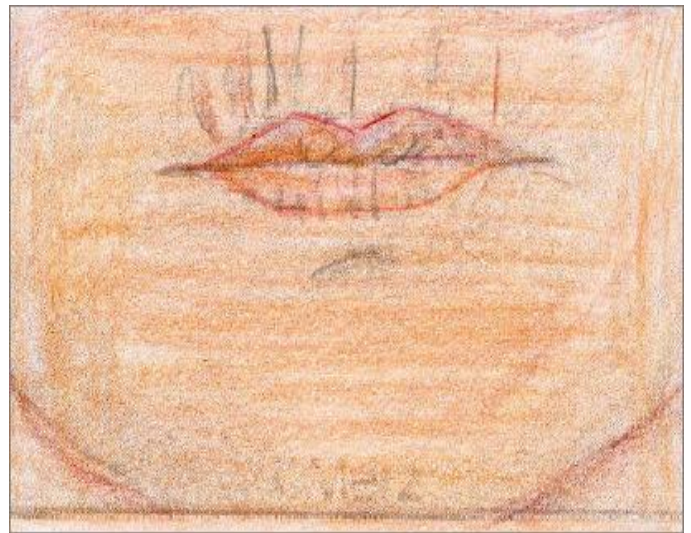
a. 0 No wrinkles



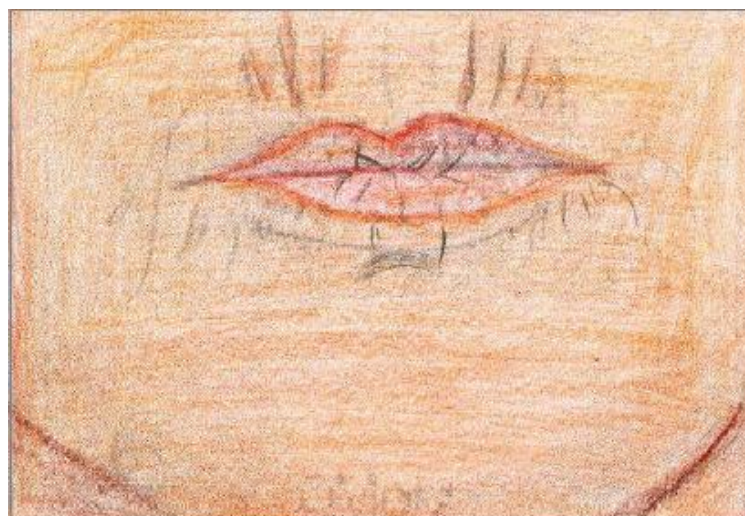b. 1 Mild wrinkles



c. 2 Moderate wrinkles



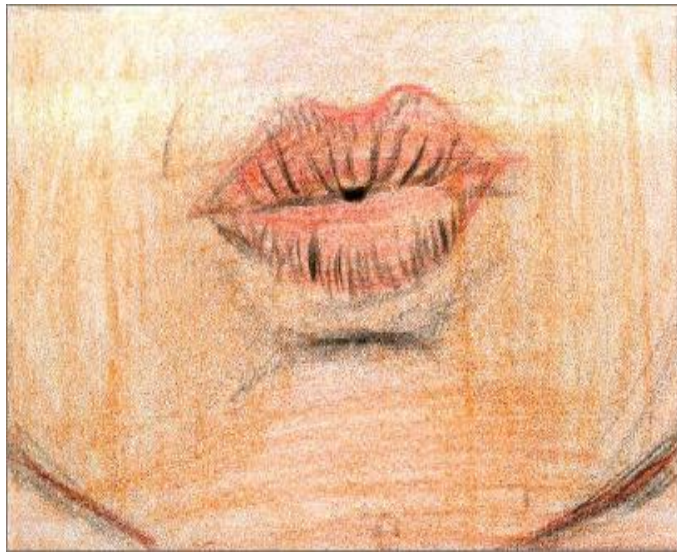
d. 3 Severe wrinkles



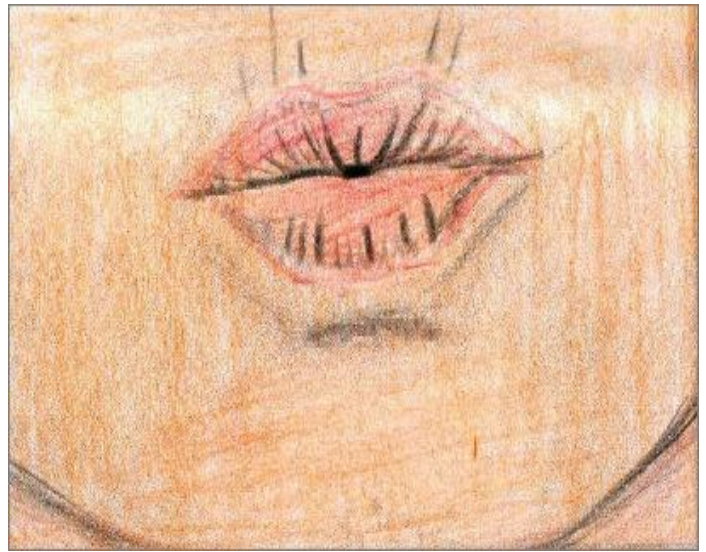
e. 4 Very severe wrinkles

(Figure: 13 a, b, c, d, e)

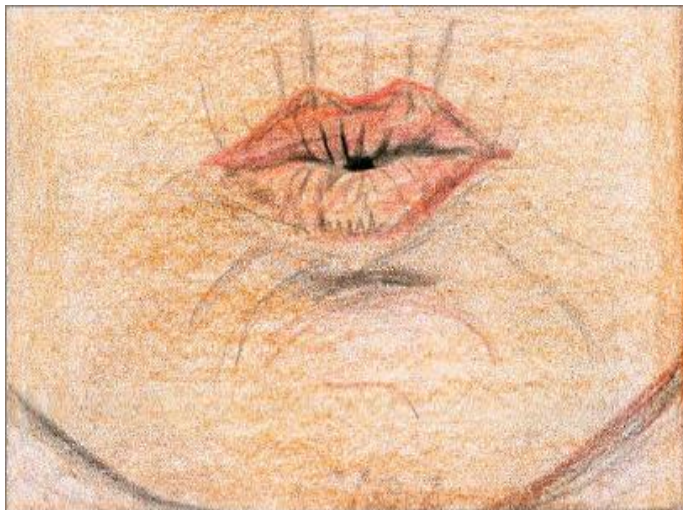
I- Lip wrinkles – dynamic



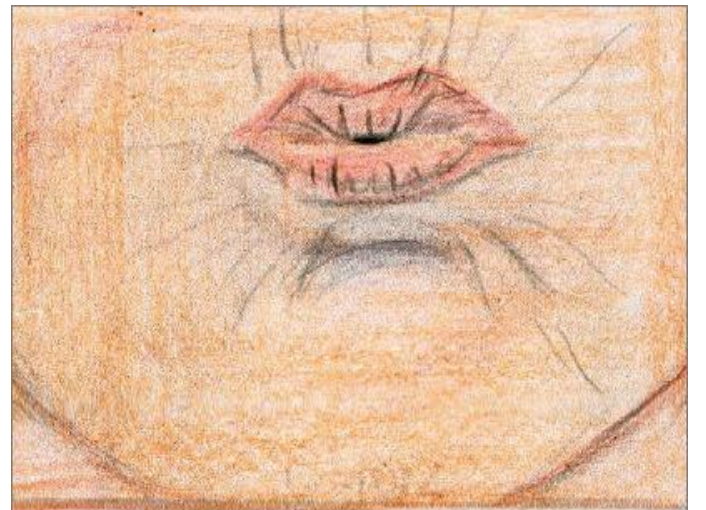a. 0 No wrinkles



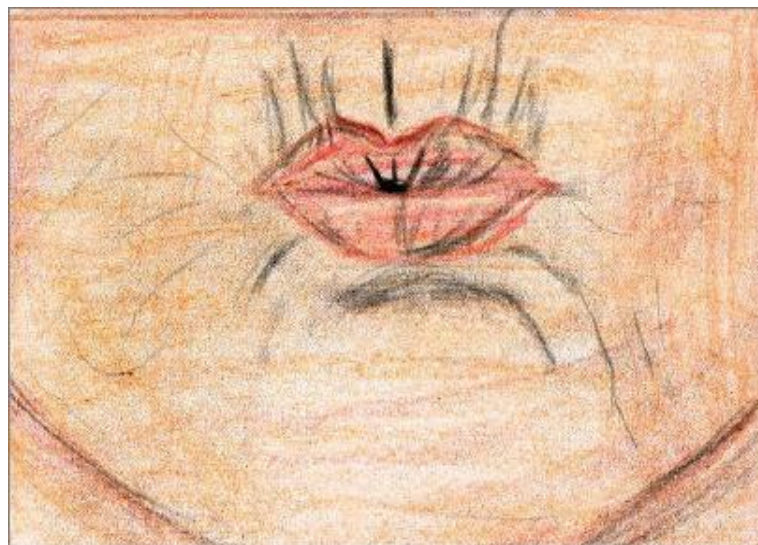b. 1 Mild wrinkles



c. 2 Moderate wrinkles

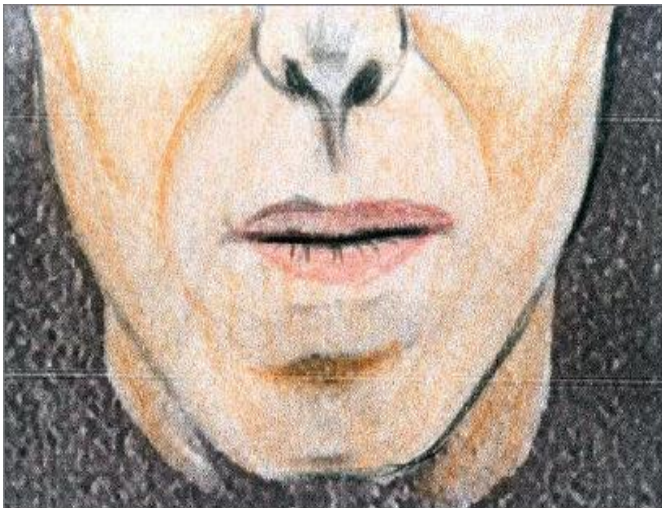


d. 3 Severe wrinkles

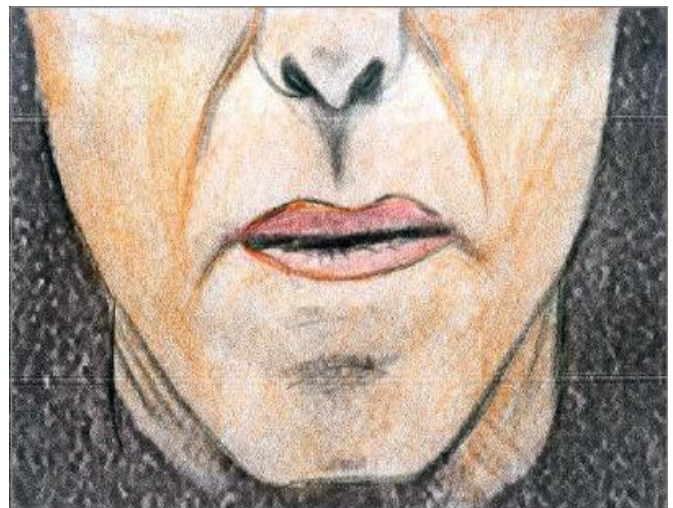


e. 4 Very severe wrinkles
(Figure: 14 a, b, c, d, e)

J- Marionette lines



a. 0 No lines



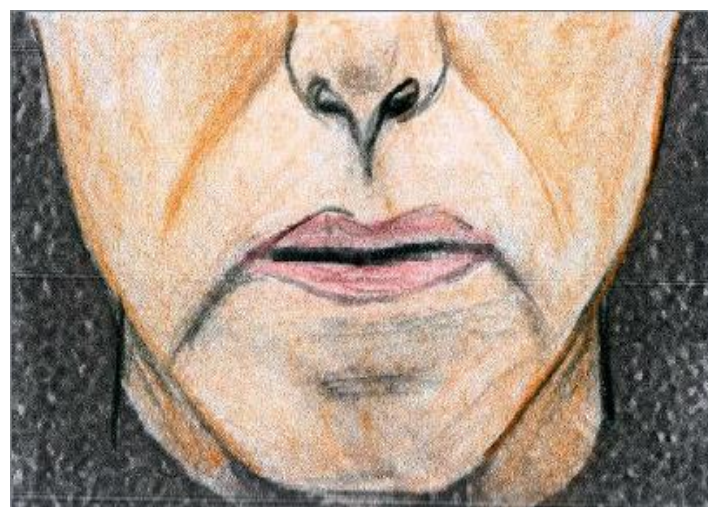
b. 1 Mild lines



c. 2 Moderate lines, clearly at rest, But not when skin is stretched

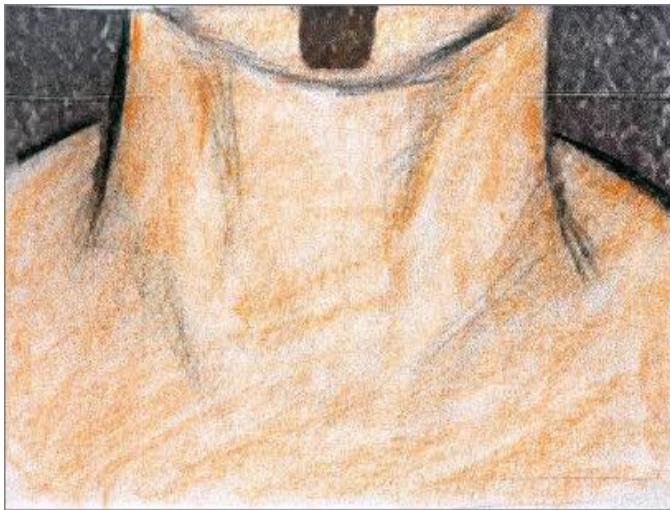

d. 3 Severe lines, conspicuous facial feature

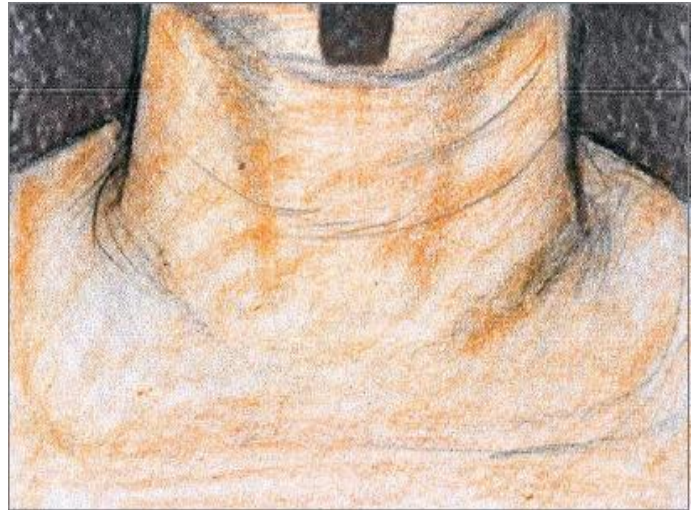


**e. 4 Very severe lines, appearance is adversely affected
(Figure: 15 a, b, c, d, e)**

K- Neck



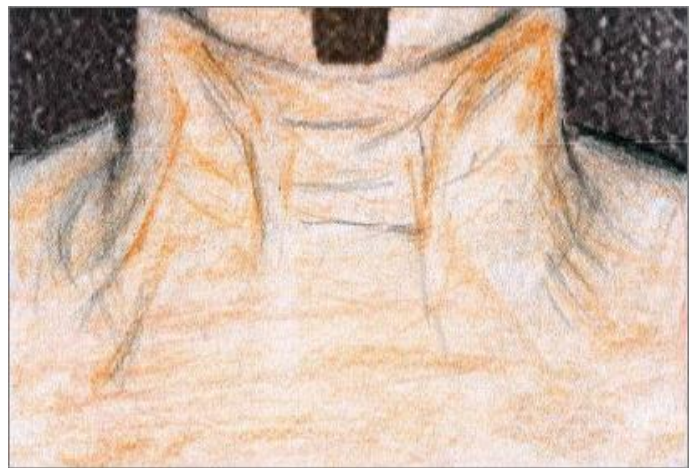a. 0 No visible horizontal lines or folds



b. 1 Mild visible horizontal lines and folds



**c. 2 Moderate horizontal line and folds;
skin laxity and platysmal band Prominence**



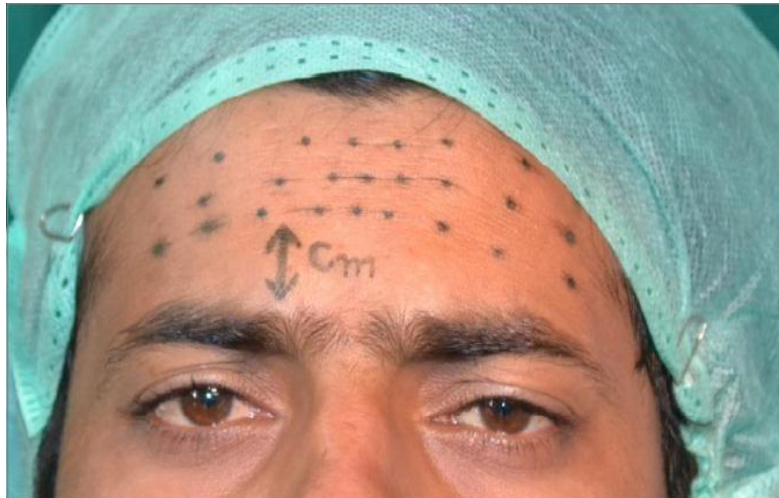
**d. 3 Severe horizontal lines and folds; Mild
moderate skin laxity and platysmal band prominence**



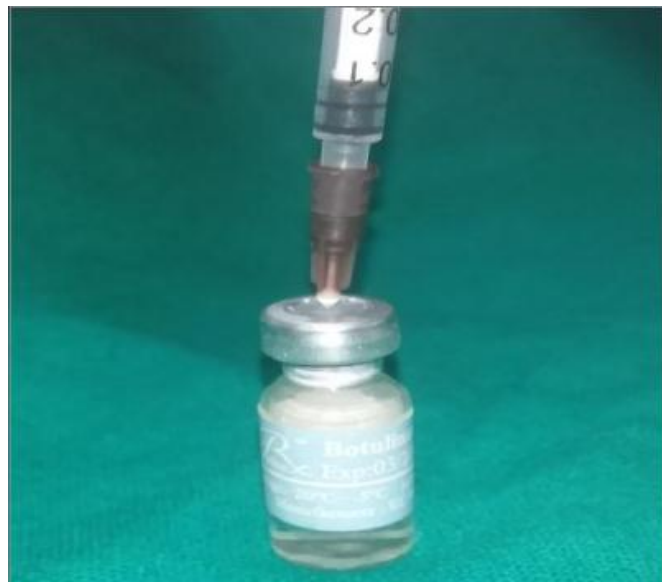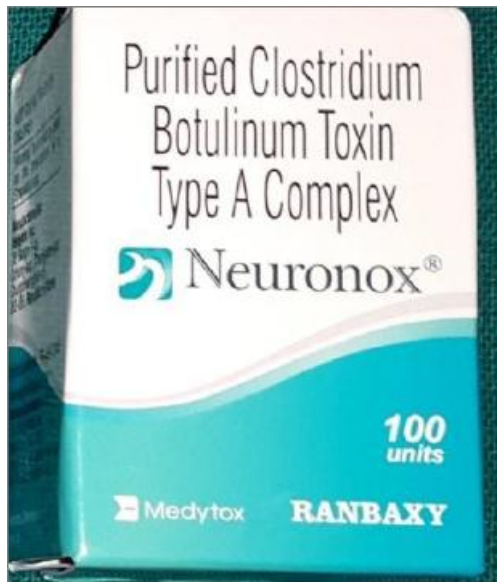**e. 4. Very severe, deep horizontal lines and folds; severe skin laxity and platysmal band prominence
(Figure: 16 a, b, c, d, e)**

CASES

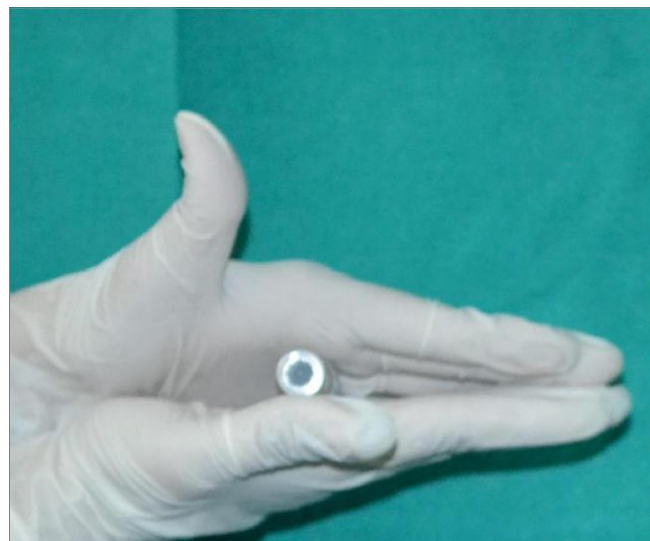
Case 1: Case of 28 Yrs. Male Patient with Horizontal Forehead Wrinkles



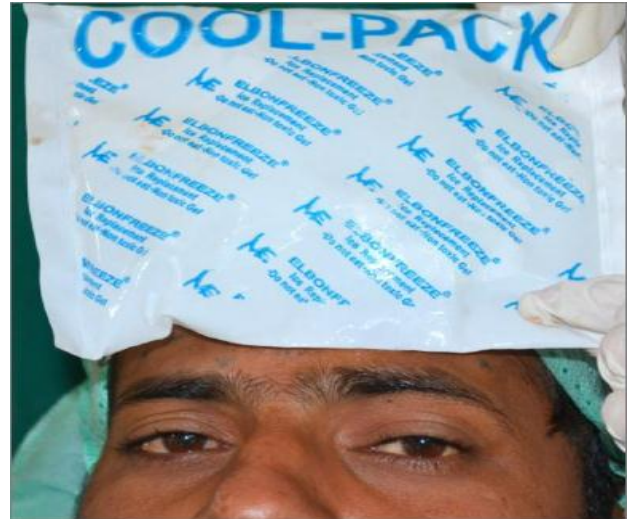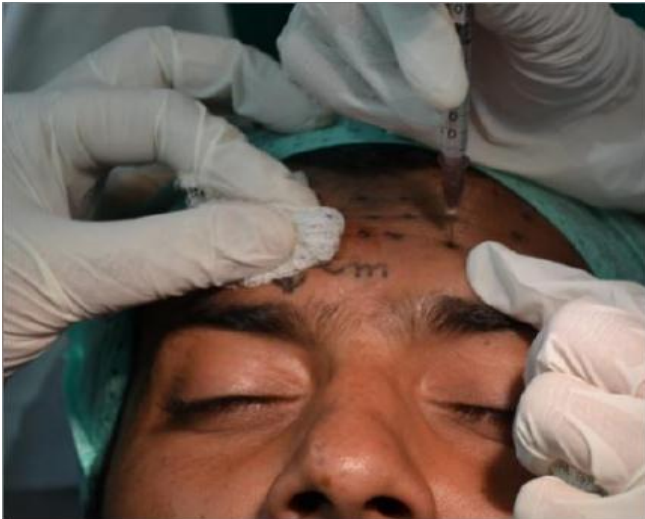Marking technique



Reconstitution of BOTOX



Mixing technique



Injection technique and Cold pack application after BOTOX injection

Before Injection

(MERZ scale score at rest 1)



At rest

(MERZ scale score 3 at dynamic)



At dynamic

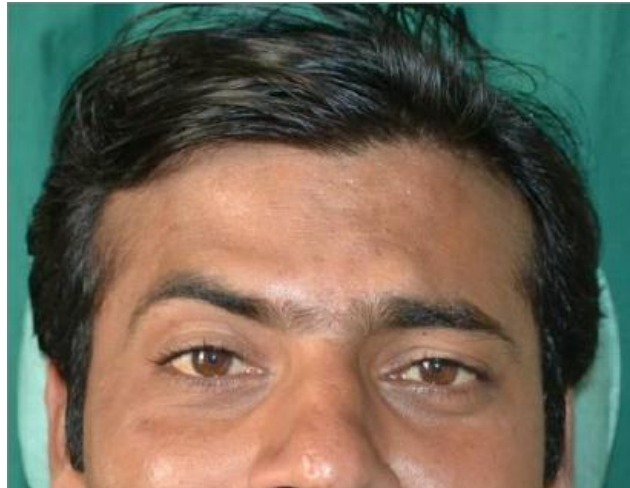After One week

(MERZ scale score 0)



At rest

(MERZ scale score 1)



At dynamic

After One month



At rest



At dynamic

After Two months



At rest



At dynamic

After three months

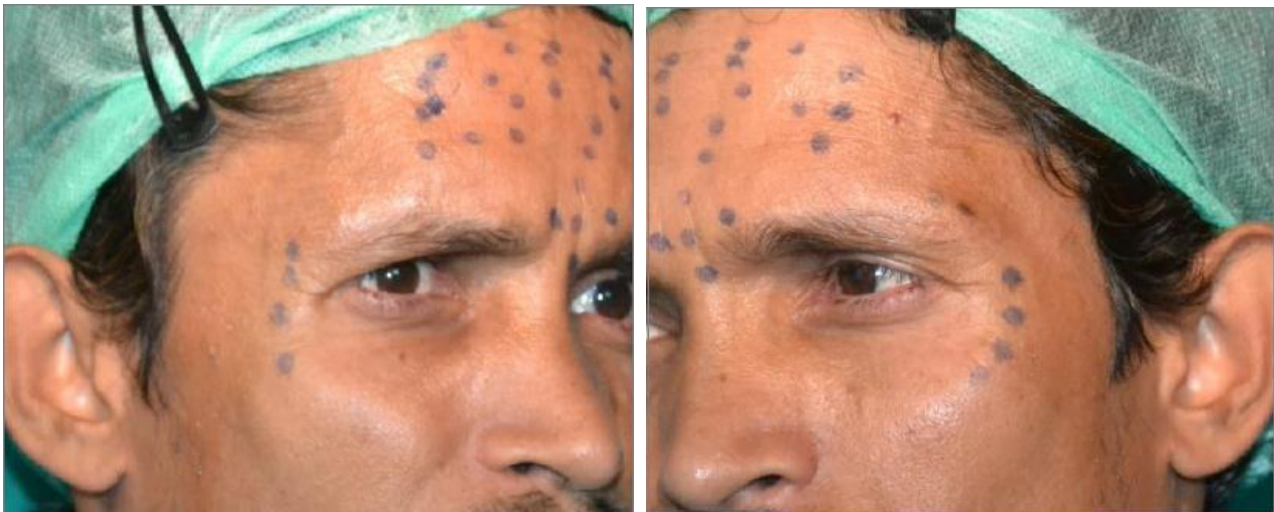

At rest

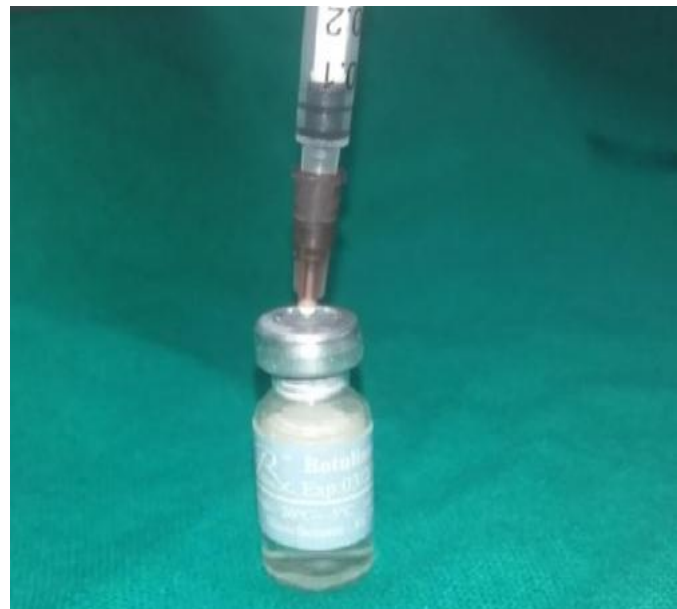
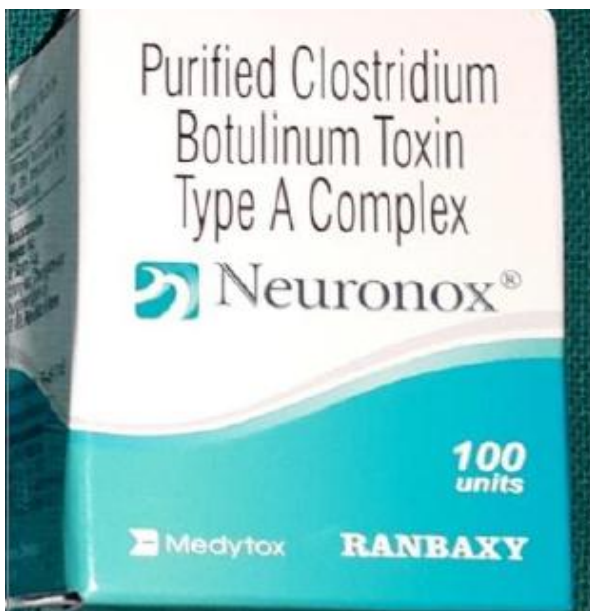
At dynamic

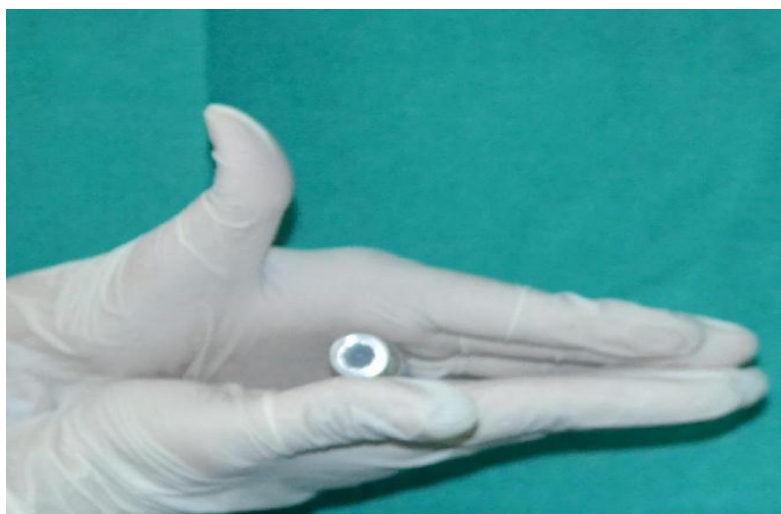
Case 2: Case Of 32 Yrs. Male Patient with Crow's Feet Wrinkles



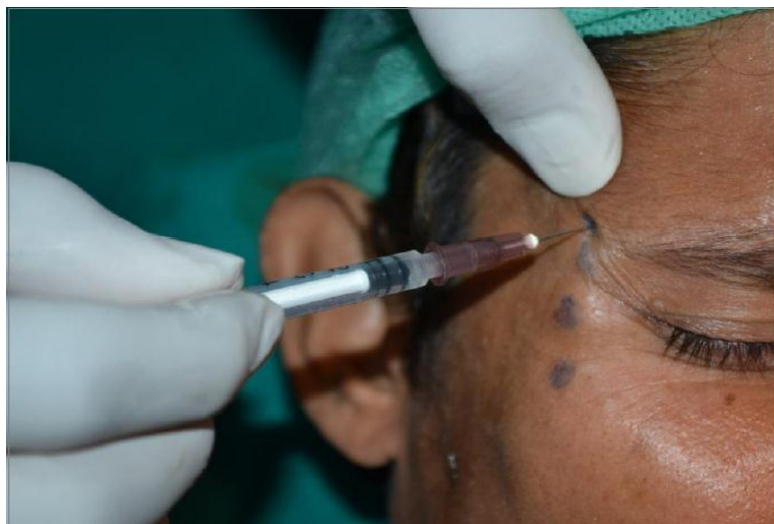Marking technique on crow's feet lines



Reconstitution of BOTOX



Mixing Technique



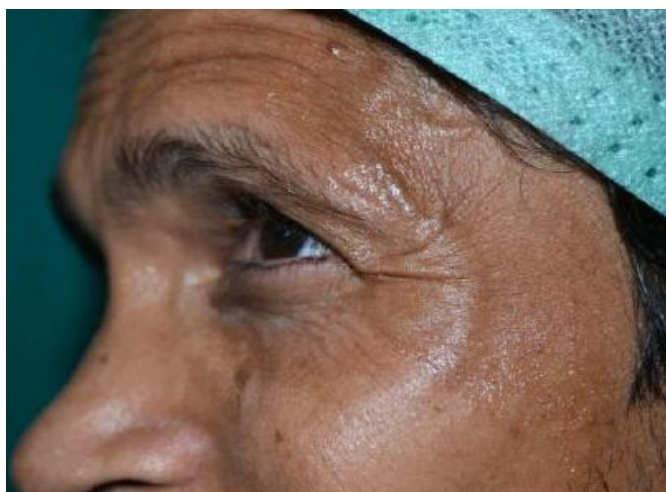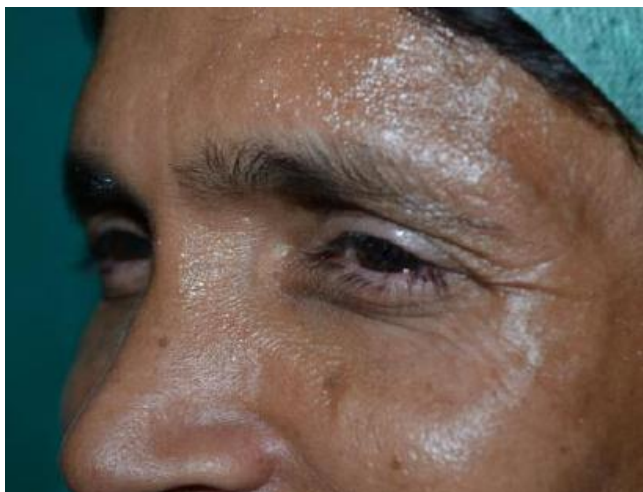Injection Technique

BEFORE INJECTION

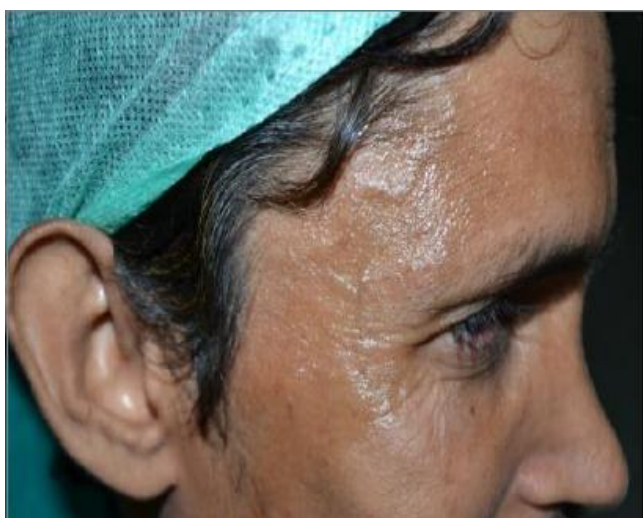(MERZ scale score 2 at rest)

(MERZ scale score 3 at dynamic)

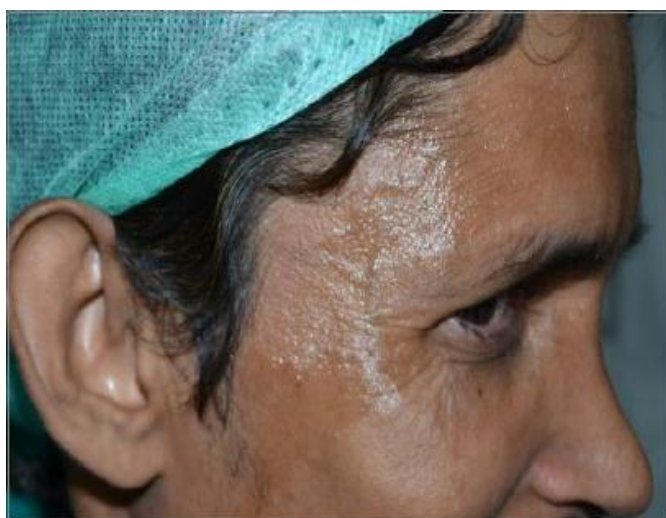LEFT



RIGHT



At rest



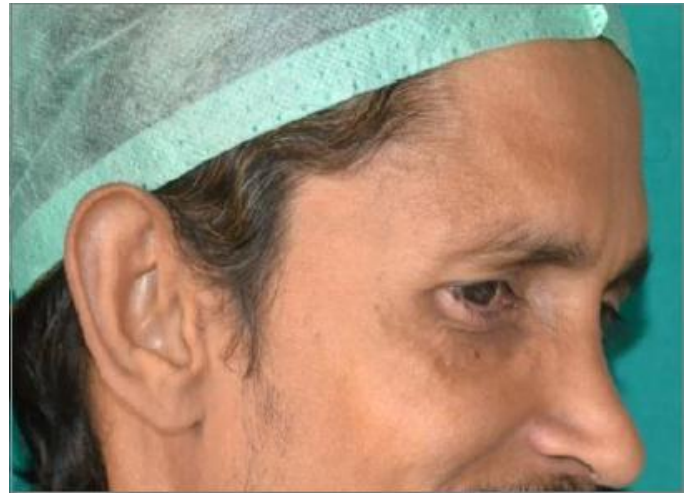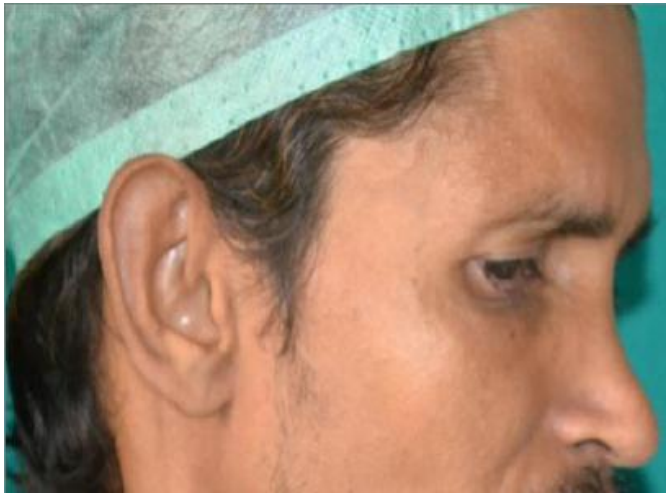At dynamic

After One week

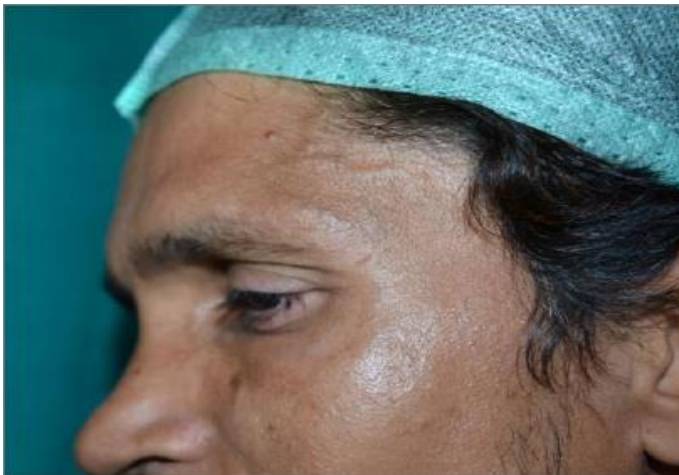(MERZ scale score at rest 0)

(MERZ scale score at dynamic 1)

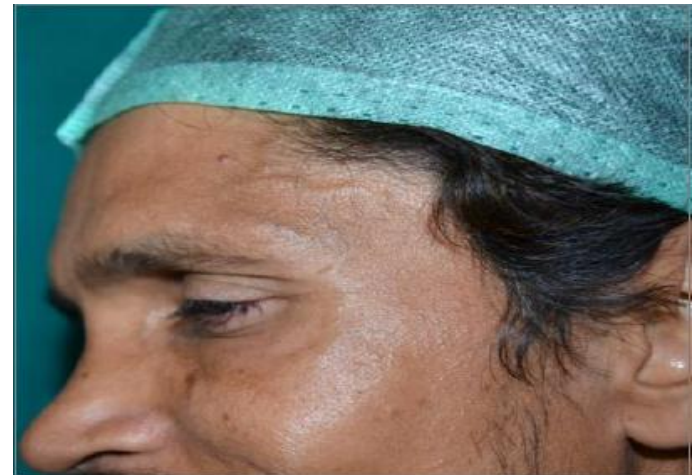LEFT



RIGHT



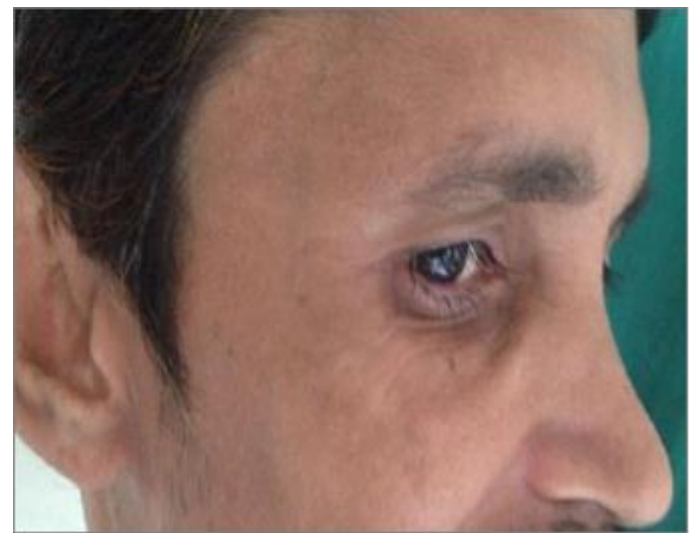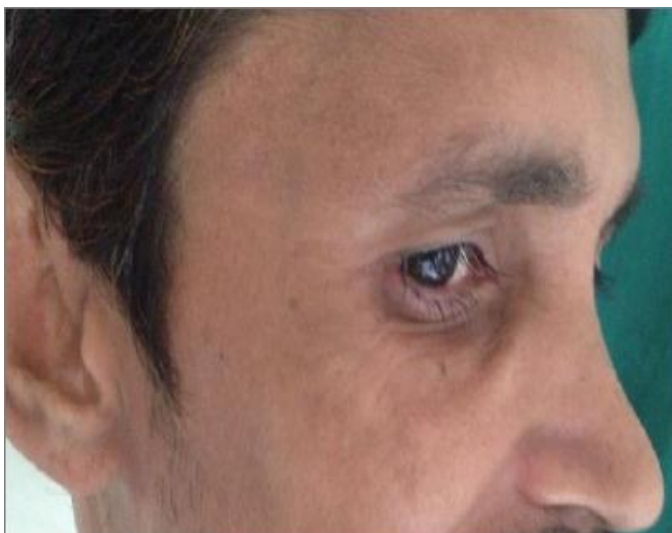At rest



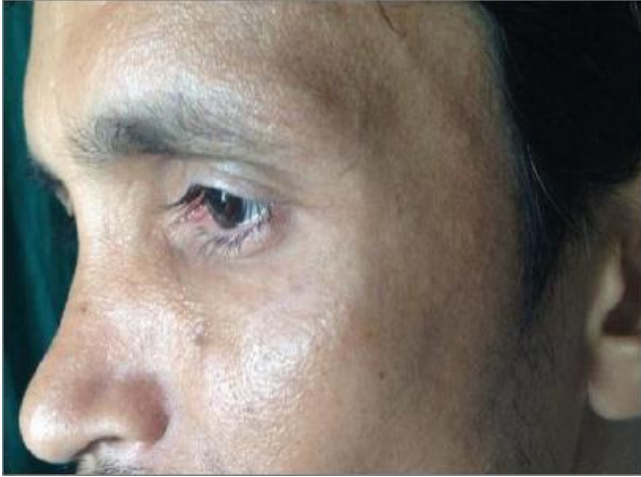At dynamic

After One month

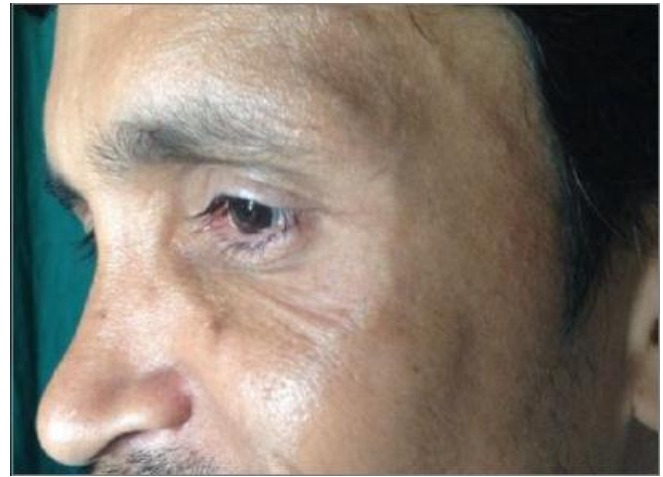LEFT



RIGHT



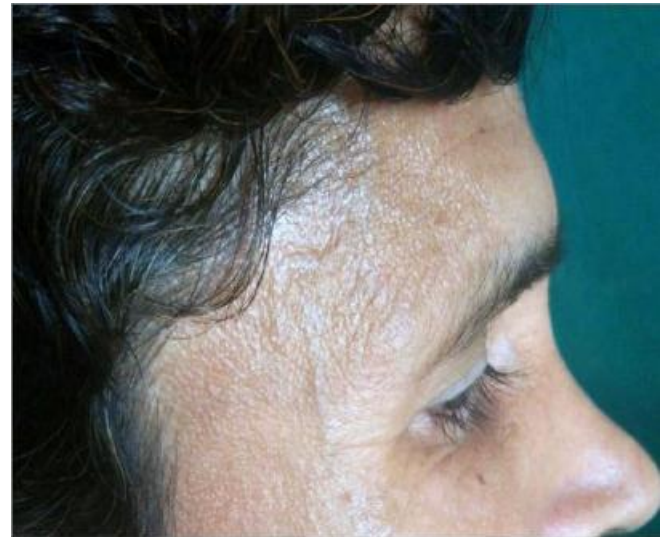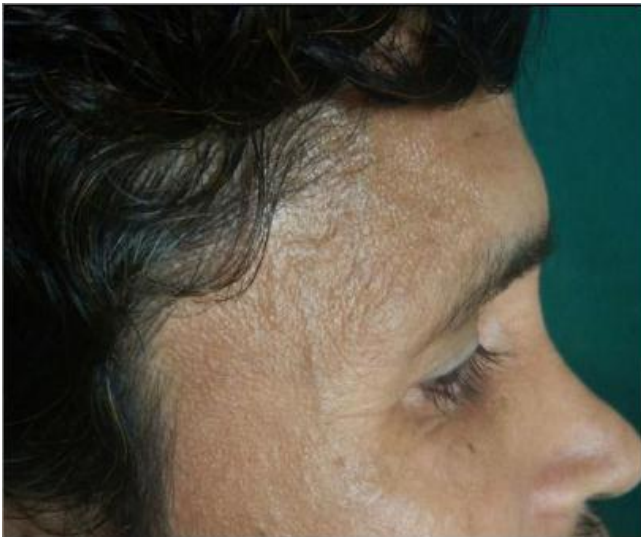At rest



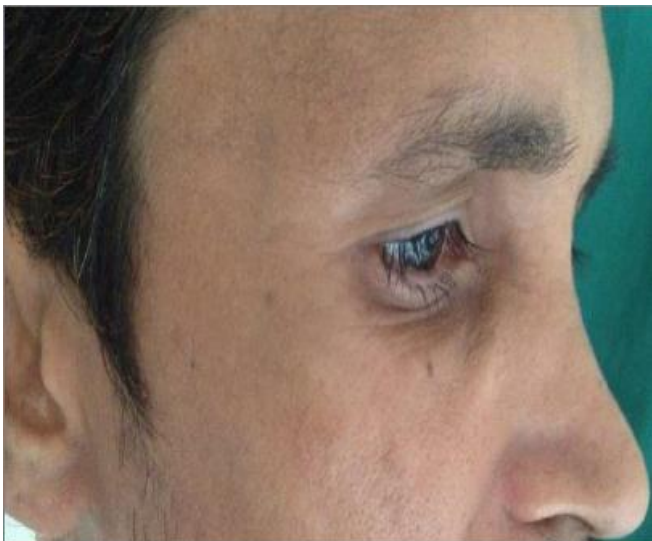At dynamic

After two months

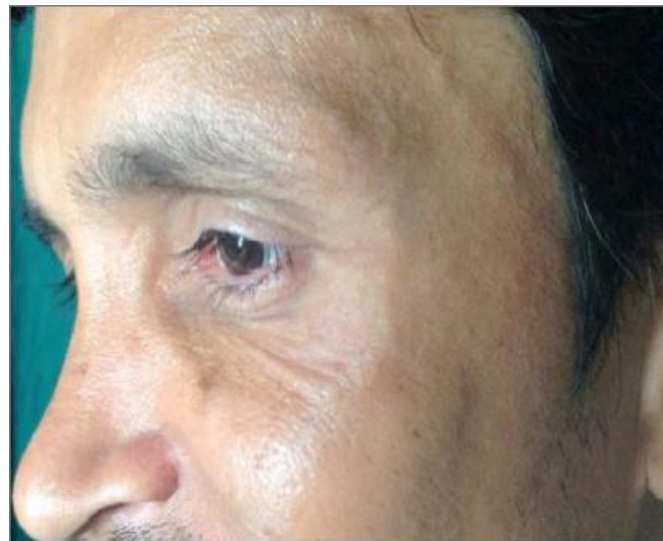LEFT



RIGHT



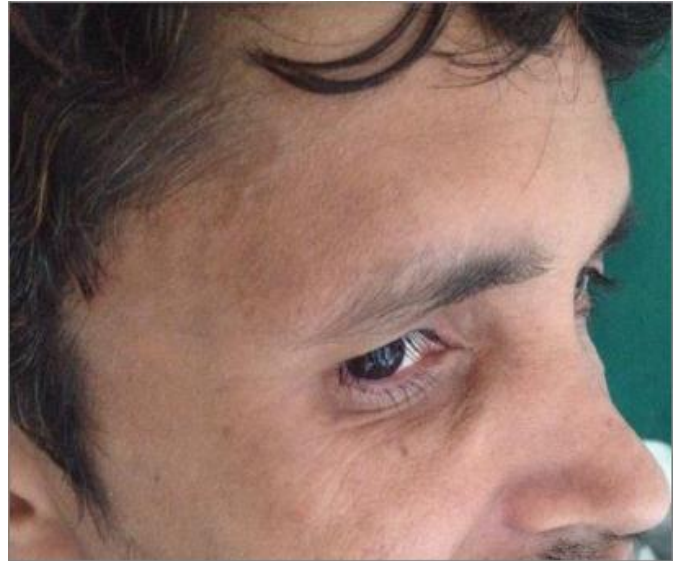At rest



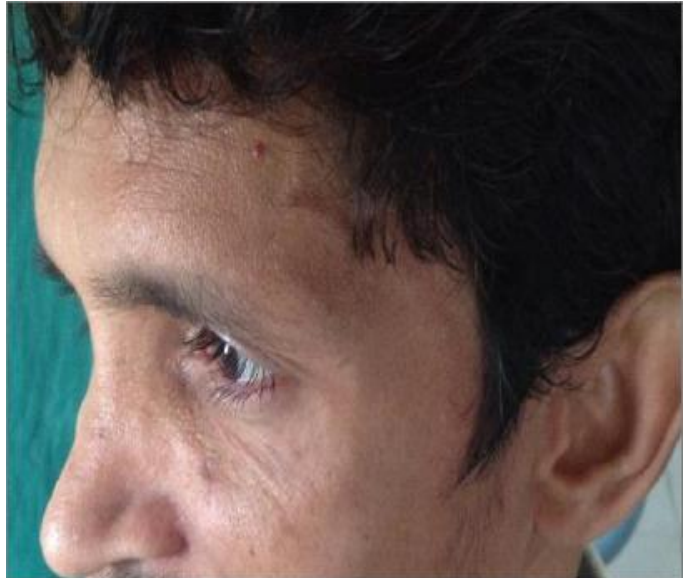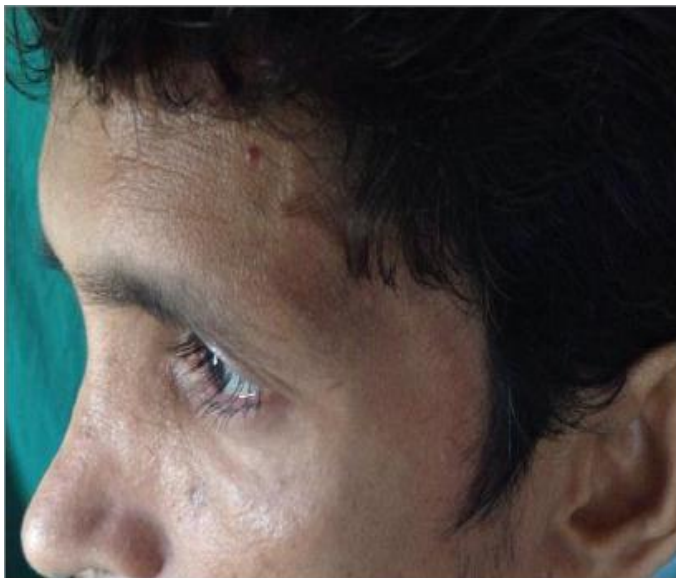At dynamic

After three months

LEFT



RIGHT



At rest

At dynamic

Results

Observation and Results

Mean Age

Table 4: Mean age of study population

Characteristics	Mean Age
Mean Age (years)	41.73 ± 10.80
Total	15

Table 4 is showing the mean age of the sample group was 41.73 with a range of 26-65 years

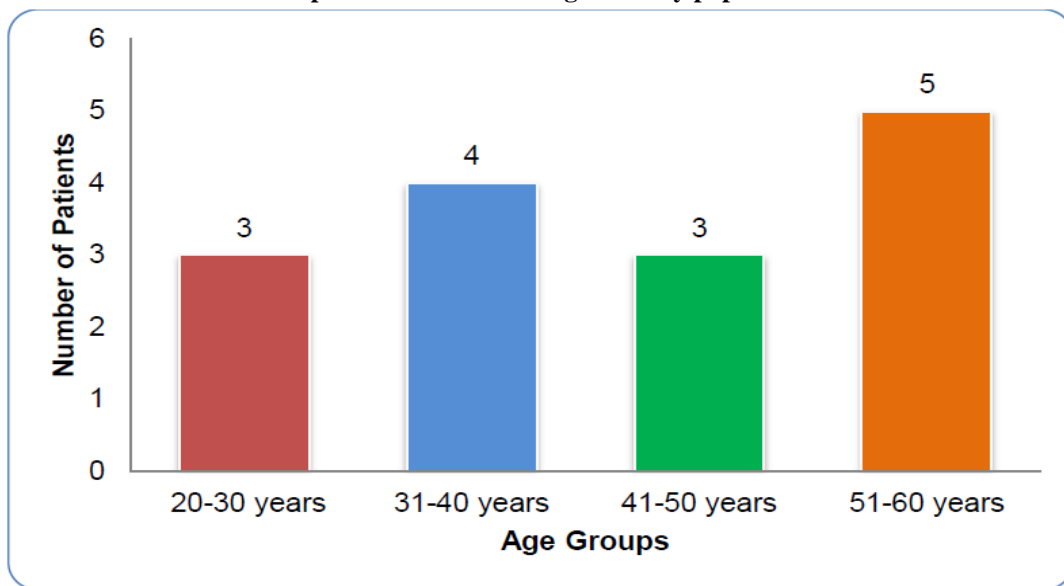
Distribution of age of study population

Table 5: Distribution of age of study population

Characteristics	Values	Percentage
Age group 20-30 years	3	20%
Age group 31-40 years	4	26%
Age group 41-50 years	3	20%
Age group 51-60 years	5	34%
Total	15	100%

Table 5 and graph 1 show that more than 30% of the subject were between 51-60 years of age i.e. in the 5th decade of their life

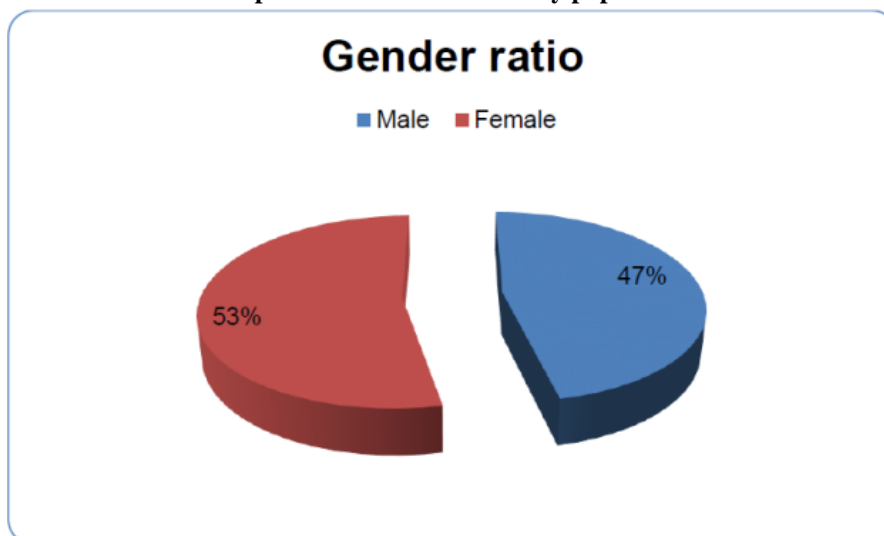
Graph 1: Distribution of age of study population



Gender ratio Table 6: Gender ratio of study population

Gender	Number	Percentage
Male	7	47%
Female	8	53%

Graph 2: Gender ratio of study population



In our study, out of the 15 patients treated, 8 were female (53%) and 7 were male (47%) (Table 6 & Graph 2).

Table 7: Study Medication

Study Drug	Mean Dose of Botox (IU)
Botox Injection	54.92 ± 28.61

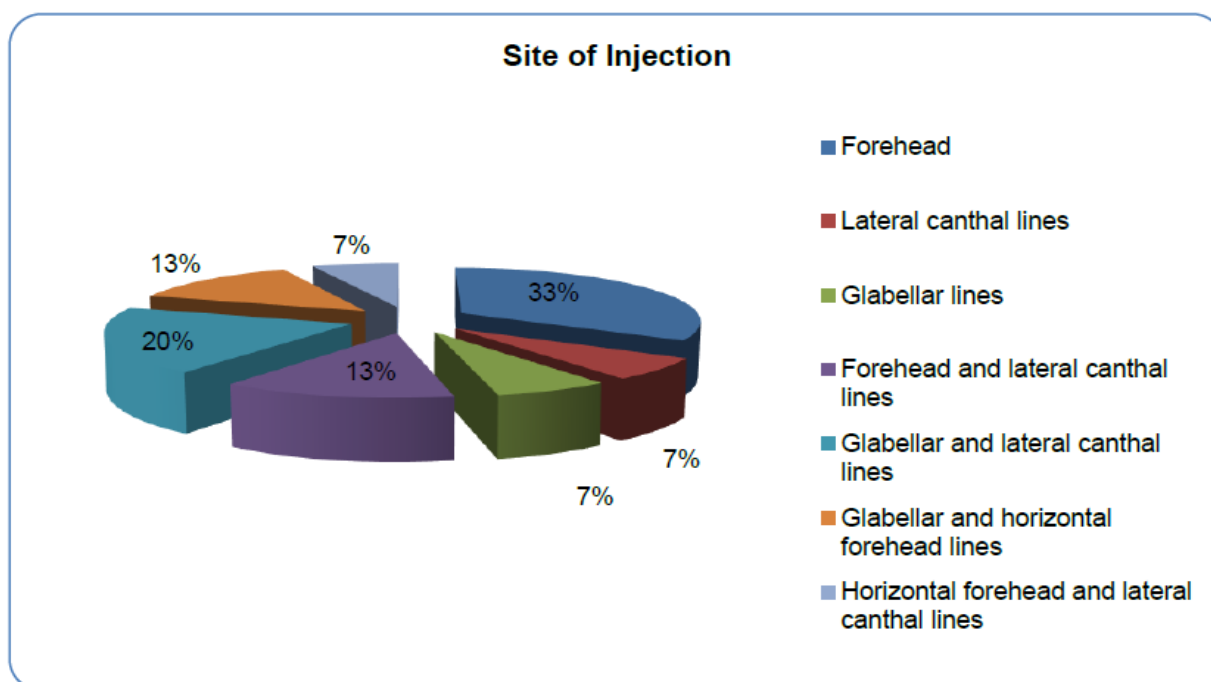
Injection botox was injected for management of facial wrinkles.

The mean dose of BOTOX was used during this study between 54.92 ± 28.61 which show in table 7.

Table 8: Site of Injection of Botox

Sr No.	Site of Injection	Number of Patients/Percentages
1	Forehead lines	5 (33%)
2	Lateral canthal lines (crow's feet lines)	2 (14%)
3	Forehead and lateral canthal lines	2 (7%)
4	Glabellar and lateral canthal lines	3 (20%)
5	Glabellar and horizontal forehead lines	2 (13%)
6	Horizontal forehead and lateral canthal lines	1 (7%)
Total		15

Graph 3: Site of Injection of Botox



Botox was used at many sites in 15 patients which included: 5 forehead wrinkles (33%), 2 crow's feet lines (lateral canthal lines) 14%, 2 forehead and crow's feet lines (7%), 3 glabellar and crow's feet lines (20%), 3 forehead and glabellar line (13%), 1 horizontal forehead line and crow's feet lines (7%) which is enlisted in Table 8 and Graph 3.

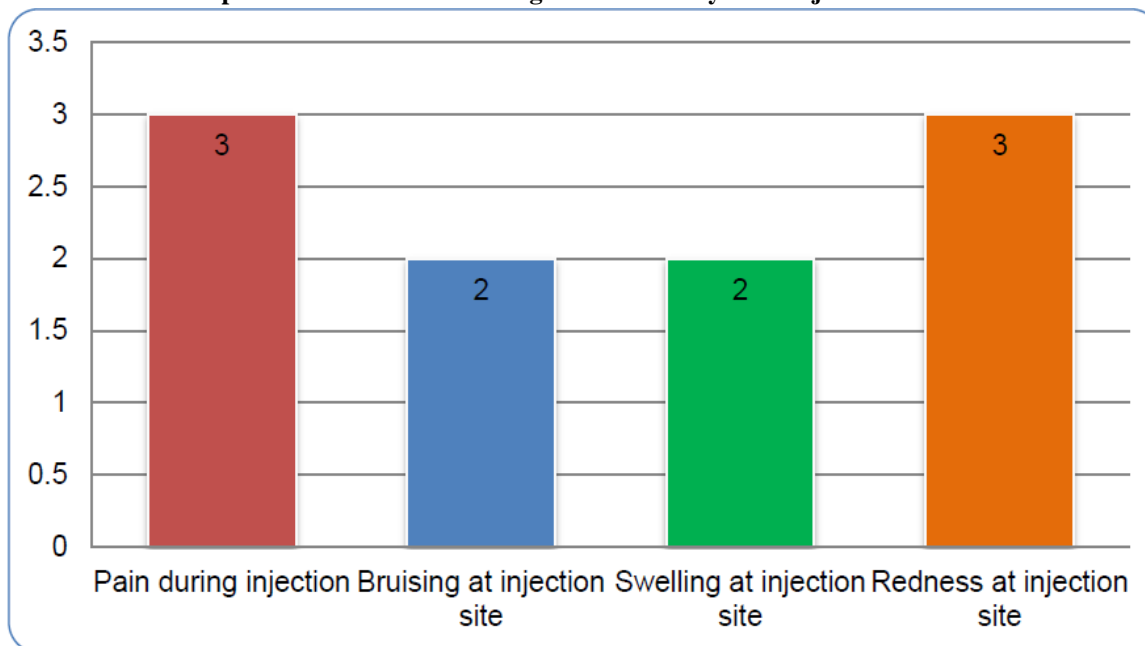
Adverse effects

Six patients (40%) experienced at least one adverse effect. Three patients experienced one effect, two experienced two effects and one patient experienced three effects.

Table 9: Adverse effects during or immediately after injection of Botox

Sr No.	Adverse Effect	Number of Effects	Percentage of Patients
1	Pain during injection	3	20%
2	Bruising at injection site	2	14%
3	Swelling at injection site	2	14%
4	Redness at injection site	3	20%

Graph 4: Adverse effects during or immediately after injection of Botox



Adverse effects during or immediately after injection of botox is presented in Table 9 and Graph 4.

Table 10: Adverse effects one week after injection of Botox

Sr No.	Adverse Event	Number of Events
1	Eyelid Ptosis	0
2	Double Vision	0
Total Events		0

No adverse effects after one week of injection of Botox seen (Table 10)

Post-Surgical Patient Satisfaction Questionnaire' (PSPSQ) score after one week of treatment

Table 11: PSPSQ score after one week of treatment

Score	Median Score	Range
PSPSQ	54	50-57

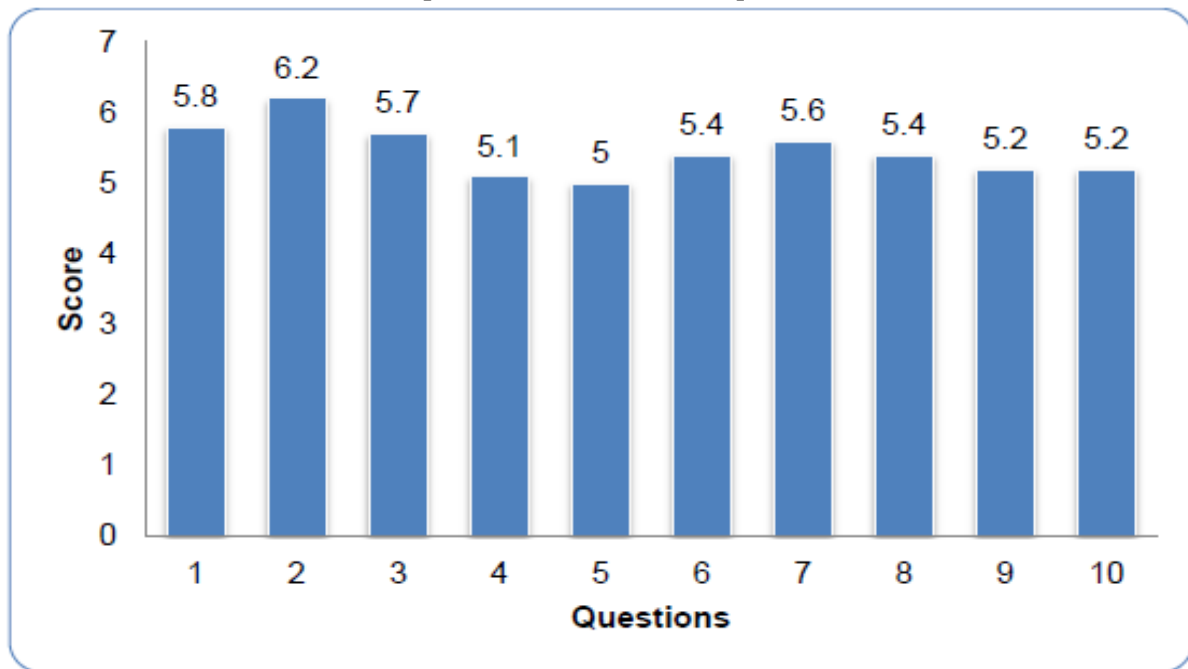
The minimal possible score using PSPSQ is 10 and maximum score is 70. Since median score is 54 that means for majority of patients were likely or very likely satisfied by the procedure. (Table 11)

Average score for each question

Table 13: Mean score for each question

Question no.	Number of responders	Minimum score	Maximum score	Mean Score	Standard Deviation
1	15	5	7	5.8	0.67
2	15	5	7	6.2	0.67
3	15	5	7	5.7	0.59
4	15	5	6	5.1	0.25
5	15	5	5	5	0
6	15	5	6	5.4	0.50
7	15	5	7	5.6	0.61
8	15	5	6	5.4	0.50
9	15	5	6	5.2	0.45
10	15	5	6	5.2	0.45

Graph 5: Mean Score for each question

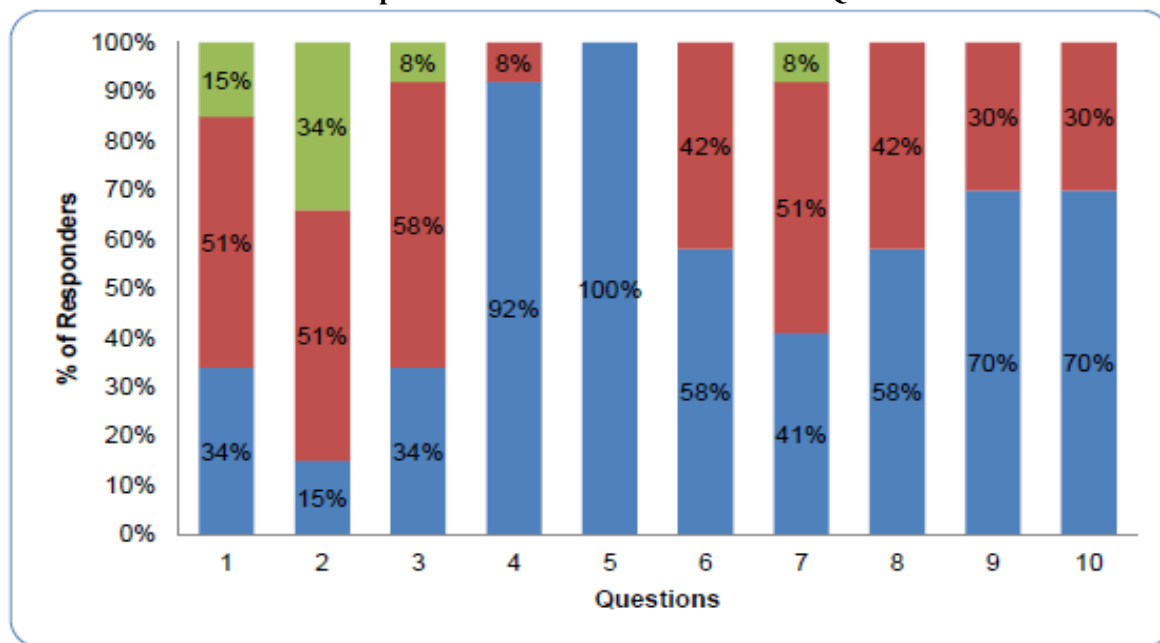


Overall Patient Satisfaction

Table 14: Overall patient satisfaction PSPSQ

Question No	Response	Number of Responders	Percentage of Responders
Q1	5	5	34%
	6	8	51%
	7	2	15%
Q2	5	2	15%
	6	8	51%
	7	5	34%
Q3	5	5	34%
	6	9	58%
	7	1	8%
Q4	5	14	92%
	6	1	8%
Q5	5	15	100%
Q6	5	9	58%
	6	6	42%
Q7	5	6	41%
	6	8	51%
	7	1	8%
Q8	5	9	58%
	6	6	42%
Q9	5	11	70%
	6	4	30%
Q10	5	11	70%
	6	4	30%

Graph 6: Overall Patient Satisfaction PSPSQ



To accurately assess and evaluate the outcome of surgery and to assess the patient's perception of the surgical results a 'post-surgical patient satisfaction Questionnaire' (PSPSQ) having a set of ten questions was given to each patient 1 week postoperatively. The patients reply to the PSPSQ was tabulated and the result analyzed is represented in table 7 and figure 5. The PSPSQ included a total of 10 questions of which the first 3 questions were related to assessing overall patient satisfaction, and the rest were for various other aspects as enumerated below: (Table 14 and figure 6)

1. For the first question- "If you had to make the decision again, how likely would you be to undergo this same procedure?" 100% patients responded positively. Of which 34% subject gave the score of 5 i.e. likely, 51% subjects gave the score of 6 i.e. very likely, 15% subject gave 7 i.e. definitely to this question.
2. When asked 'How likely would you be to recommend this same procedure to others?' 100% patients were satisfied with the treatment. Of which 15% subject gave the score of 5 i.e. likely, 51% subjects gave the score of 6 i.e. very likely, 34% subject gave 7 i.e. definitely to this question.
3. "Considering everything, how satisfied are you now with the results of procedure?" 100% patients were satisfied with the treatment. Of which 34% subject gave the score of 5 i.e. likely, 58% subjects gave the score of 6 i.e. very likely, 8% subject gave 7 i.e. definitely to this question.
4. Acceptance of the neuro-motor changes at treated site (forehead, eyelid, cheek, upper lip) depending upon the site of treatment) when asked the question "Overall, how accepting are you with any change

in neuro-motor function of the associated in structure of the injection site? (Eyelid movement, facial expressions - which ever applicable)". Of which 92% subject gave the score of 5 i.e. acceptable, 8% subjects gave the score of 6 i.e. very much acceptable.

5. Acceptance of the neuro- sensory changes at treated site (forehead, eyelid, cheek, upper lip) depending upon the site of treatment) when asked the question "Overall, how accepting are you with any change in neuro-sensory function of the associated structure of the injection site?" (Eyelid movement, facial expressions - which ever applicable) 100% patient gave the score of 7 i.e. excellent to this question.
6. Satisfied with aesthetics: When asked" Overall, how accepting are you with overall appearance /aesthetics changes?"At the completion of the treatment of which 58% subject gave the score of 5 i.e. they expressed satisfaction of the post treatment result, 48% subjects gave the score of 6 i.e. very likely to this question.
7. Improvement in self-confidence: when asked "Overall how much, has the procedure improved your self-confidence and personality?" Of which 41% subject gave the score of 5 i.e. improvement in their self-confidence and personality, 51% subjects gave the score of 6 i.e. very good, 8% subject gave 7 i.e. excellent personality development after treatment to this question.
8. "Overall, how natural (or artificial) the corrected site appears to you?" Of which 15% subject gave the score of 5 i.e. likely, 51% subjects gave the

score of 6 i.e. very likely, 34% subject gave 7 i.e. definitely to this question.

9. Acceptance of facial contour and symmetry “Overall, how accepting are you with facial aesthetic/symmetry?” Of which 70% subject gave

the score of 5 i.e. good, 30% subjects gave the score of 6 i.e. very acceptable to this question.

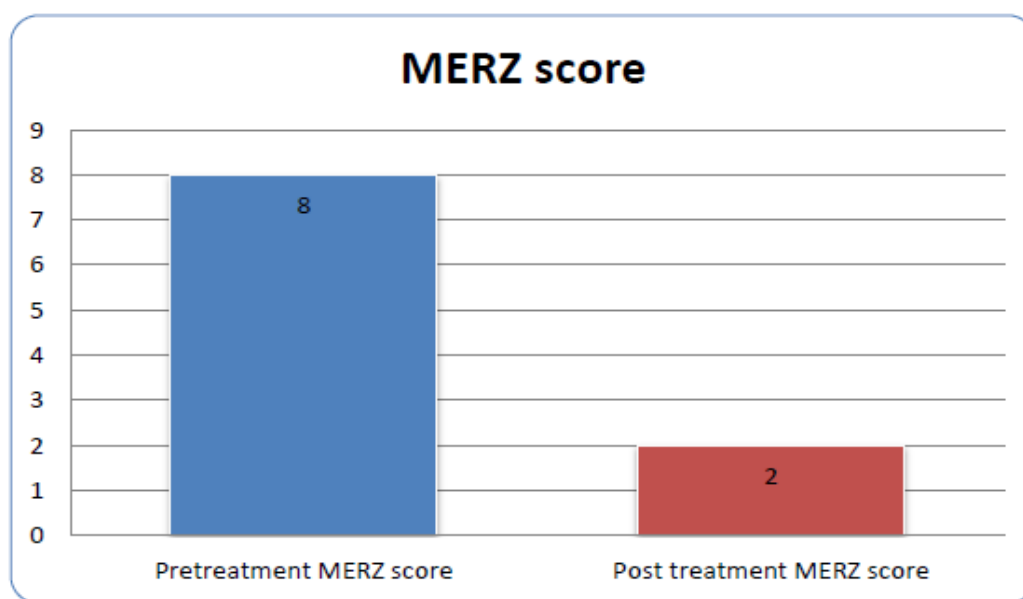
10. When asked “Overall, how accepting are you with pain during injection?” In which 70% patient gave score of 5 i.e. acceptable and 30% patients gave score 6 i.e. very acceptable to this question.

Table 15: Efficacy evaluation of Injection of Botox using MERZ score

Scale	Median Score (range)	P value
Pretreatment MERZ score	8 (4-14)	<0.0001
Post treatment MERZ score	2 (1-6)	
Wilcoxon Matched pairs test, P value<0.05 is considered significant versus pretreatment score		

In MERZ^o scoring system, lower the value better is the effect of drug reducing the wrinkles. (Table 15 & Graph 7)

Graph 7: Efficacy evaluation of Injection of Botox using MERZ score



Wilcoxon Matched pairs test, P value<0.05 is considered significant versus pretreatment score Since p value is less than 0.05 (p<0.0001) the difference between pre and post treatment effect is extremely significant. (The drug is very effective)

Table 16: Longevity of Botox injection

Characteristic	Mean duration of effect	Standard deviation
Duration (days)	125.28	6.60

Longevity/ Duration of effect of Botox injection mean value is 125.28 shows in the Table16.

The following analysis was done using Microsoft Excel office 2007 and Statistical software GraphPad InStat Version 3.06.

Discussion

Botulinum toxin has been used for aesthetic since 1987 in the upper face wrinkles with name of BOTOX. Botulinum toxin is obtained from anaerobic gram positive bacteria. This gram positive anaerobic bacterium produces the most potent neurotoxin known to mankind. Seven distinct antigenic botulinum toxin (A, B, C, D, E, F and G) produced by different strains of Clostridium Botulinum have been described. Human disease is caused by five of these

serotype (A, B, E, F and G). Type A is the strongest, followed by type E and F which are potentially of value in patients who developed antibodies to type A.⁴ BTX acts on neuromuscular endplates which irreversibly inhibit release of ACh (acetylcholine), act as neurotransmitter which paralyse the targeted muscles. BOTOX is very effective for dynamic facial wrinkles.

This study was conducted on patients with dynamic facial wrinkles. 15 cases were selected randomly irrespective of their caste, creed and age from the Department of Oral and Maxillofacial Surgery, Santosh Medical & Dental College and Hospital, Ghaziabad, NCR Delhi.

In this study the cases we included were Patients presenting with dynamic wrinkles of the upper face (glabella, forehead, or crows' feet etc.), and those patients who desiring treatment of the wrinkles and agreed to comply with the requirements of the study and patients who were very much concerned for their fine lines and dynamic facial wrinkles but they were not ready for any surgical treatment and we excluded patients with Neuromuscular disorder e.g.: Myasthenia gravis etc, reported allergy to components of drug, On medications like aminoglycosides, quinine, penicillamine and calcium channel blockers that would interfere with the neuromuscular function, Pregnancy, lactation, during the study period, patients with systemic disorders like hypertension, diabetes mellitus, heart diseases etc and any other condition or situation existed that would put the patient at significant risk. Psychologically unstable patients or who had unrealistic goal and reasons.¹

In this study, out of the 15 patients treated, 8 were female (53%) and 7 were male that means female were more concerned than males which is similar to the study done by Andrew Blitzer et al 1993.⁷

In our study patients included were within the age limit of 20-60 years, with commonly affected age groups 51-60 years (34%), 31-40 years (26%), 20-30 years (20%) and 41-50 years (20%), and the mean age of the patients was 41.73.

In our study various sites for surgery among the total patients were noted. The most common site of facial wrinkles were forehead (33%), followed up glabellar and crow's feet lines (20%), crow's feet lines (14%), glabellar and horizontal forehead lines (13%), forehead and lateral canthal lines (7%), horizontal forehead and crow's feet lines (7%). The study done by M Scott Connor 2003¹¹ also evaluated various site, total number patients were 30 in which 93.3% were glabellar wrinkles and 20% were horizontal forehead wrinkles.

In this study 3 patient experienced pain during injection (20%), 2 patients experienced bruising at injection site (14%), 2 patient experienced swelling at injection site (14%), the study done by Jennifer Clay Cather 2002⁴. also showed (13%) patients experience pain on injection, (1.1%) bruising after injection.

In our study we evaluated adverse effect after 7 days which was eyelid ptosis and double vision but there were no adverse effect noted after one week of injection.

In our study, the patient's satisfaction of the treatment was noted on "post-surgical patient satisfaction questionnaire" 7 days after treatment We collected data from every patient in his study on PSPSQ, So on the basis of data collection mean score were 5.8 for question number 1, score 6.2 for question no 2, score 5.7 for question number 3, score 5.1 for

question number 4, score 5 for question number 5, score 5.4 for question number 6, score 5.6 for question number 7, score 5.4 to question number 8, score 5.2 to question number 9, score 5.2 to question number 10. Dinesh Singh Chauhan et al 2013¹, also evaluated patients in their study on a satisfaction scale and the mean value showed the patient's satisfaction to treatment at the end of 6 months did not touch '0' which indicates the high satisfaction in relief of wrinkles.

All the patients in this study were followed up for a period of 6 months, between interval 24 hours after treatment, 7 day, 30 days, 60 days, 90 days, 120 days, 150 days and 180 days and scored for the response to treatment with BOTOX by patients independently using facial esthetic scale (MERZ) scale. In this scale, we scored 0-4 on the basis of severity according to brow positioning (A), forehead lines- at rest (B) at dynamic (C), glabellar lines – at rest (D) at dynamic (E), lateral canthal lines- at rest (F) at dynamic (G), lip wrinkles- at rest (H) at dynamic (H), marionette lines (J), and neck (K). We evaluated pretreatment score 1 day before treatment and post treatment score recorded, 7 days after treatment.

The P- value of pretreatment and post treatment of MERZ scale score was <0.0001 which is less than 0.05 which showed the difference between pre and post treatment effect was statistically significant.

In our study, Mean dose of BOTOX has been used between 54.92 ± 28.61 , we evaluated patients for 6 months follow up and recorded longevity of BOTOX injection and mean value of injection longevity were 125.28 days.

Conclusion

In some people, there is a habit which promotes to create minute facial wrinkles on the face which gradually darken with time, all these wrinkles also known as habitual facial lines or wrinkles, mimetic wrinkles or facial dynamic wrinkles. BOTOX is safe, very effective, simple and less invasive way to treat facial dynamic wrinkles. Patients whose skin elasticity is preserved and facial expression are dynamic are the ones who can be most preferred for the treatment with BOTOX. Botulinum toxin is not much effective for aging wrinkles (due to loss of elasticity) and sun exposure lines. BOTOX has been used aesthetically from 1987. It acts on neuromuscular endplates and block the neurotransmission by irreversibly inhibition of ACh (acetylcholine) which paralyse the targeted muscle fibers. Handling and reconstitution of drug is easy. After reconstitution we can preserve solution for 3- 7 days at -4 to -8°C.

This study showed female were more concerned than males for their wrinkles because percentage of females were 53%

and males were 47%. In this study Horizontal forehead wrinkles, glabellar and crow's feet (lateral canthal lines) wrinkles has been treated with BOTOX, which showed good result. BOTOX is easy to use with very less complications like pain during injection, swelling immediate after injection and redness immediate after injection, which vanished after few days of treatment.

We also evaluated adverse effect after one week and there were no adverse effects (eyelid ptosis and bruising) seen. No sensitivity was seen of botulinum toxin type A, in any of the patients. days). In this study, we used Botulinum Toxin type-A in every patient because BTXA is the strongest one with maximum longevity among all sub type available for aesthetic use (type B, E & F). Objective evaluation done by using a satisfactory scale showed patients were highly satisfied and drug improved their self-confidence and self-esteem. In this study we included patients between 21-65 years age groups. We used an aesthetic scale (MERZ scale) in this study, evaluated pre and post treatment score which showed major difference between pre and post treatment score that means, BOTOX is highly effective modality to reduce habitual facial dynamic muscle action and helps to achieve self-confidence. According to this study clinical applications of BOTOX for the management of facial dynamic wrinkles is a nonsurgical intervention which was more efficient and safe. So this study suggested that we can use BOTOX to treat habitual facial dynamic wrinkles and we can improve individual's confidence and quality of life.

Bibliography

- [1] Chauhan D S, Cariappa K M et al Botulinum toxin type A for the treatment of hyperkinetic lines of the face. *J. Maxillofac. Oral Surg.* 2013; 12:173-183
- [2] Ellis, David A F, and Tan K W Cosmetic upper facial rejuvenation with botulinum. *J. of Otolaryngology.*1997; 26:92-96
- [3] Niamtu J III Aesthetic use of botulinum toxin A. *J. Oral Maxillofac Surg* 1999; 57:1228-1233
- [4] Cather J C, Cgristian C J et al Update on botulinum toxin for facial aesthetic. *Dermatol Clin.* 2002; 4:749-761
- [5] Niamtu J III The use of botulinum toxin in cosmetic facial surgery. *Cosmetic Facial Surgery.* 2000; 4:1042-3699.
- [6] Kane M, Sattler G Illustrated guide to aesthetic Botulinum toxin injections.*Plastic Surgery.* 2013; 2:30-31.
- [7] Blitzer A, Mitchell et al Botulinum toxin for the treatment of hyperfunctional lines of the face. *Arch Otolaryngol Head Neck Surg* 1993; 119:1018-1022.
- [8] Edmund A, Pribitkin, Greco T M Patient selection in the treatment of glabellar wrinkles with botulinum toxin type a injection. *Arch Otolaryngol Head and Neck Surg* 1997; 123:321-326.
- [9] Ahn K Y, park K Y Botulinum toxin for the treatment of facial hyperkinetic wrinkles lines in Koreans. *Plast.Reconstr.Surg.*2000; 119:778-84.
- [10] Sommer B, Zschocke, Bergfeld D, et al Satisfaction of patients after treatment with botulinum toxin for dynamic facial lines. *J. Maxillofac.Sugr.* 2003; 5:457-460.
- [11] Conner M S, Karlis V et al Management of the ageing forehead: a review. *American Academy of Dermatology* 2002; 2:19-96.
- [12] Flynn T C, Carruthers A et al The use of the ultra-fine needle ii short needle 0.3-cc insulin syringe for botulinum toxin injection. *J. Am acad Dermatol* 2002; 46:931-933.
- [13] Carruthers A J, Nicholas J, Lowe et al A multiple, double blind, randomized, placebo controlled study of the efficacy and safety of botulinum toxin type a in the treatment of glabellar lines. *The American academy of Dermatology.* 2002; 46:840-849.
- [14] Vartanian J, Steven H. D Complications of botulinum toxin a use in facial rejuvenation. *Facial plastic Surg Clin N Am* 2005; 4:22-28.
- [15] Niamtu J III Complications of filler and botox. *Oral maxillofacial Surg Clin N Am* 2008; 21:14-21.
- [16] Kassir R, Kolluru R et al Triple-blind, prospective, internally controlled comparative study between abobotulinum toxin and onabotulinumtoxin for the treatment of facial rhytides. *Dermathol ther* 2013; 2:443-456.
- [17] Chapel Hill et al Advances in the use of botulinum neurotoxins in facial esthetics, *Aesthetic Plast Surg.*2003; 2:100-105.
- [18] De Maio M The minimal approach: an innovation in facial cosmetic procedures. *Aesthetic Plast Surg.*2004; 5:295-300.
- [19] Rubin M G, Cox S E, Kaminer et al Correcting age-related changes in the face by use of injectable fillers and neurotoxins. *Semin Cutan Plast Surg.*2014; 4:333-353
- [20] Coleman K R, Carruthers J Combination therapy with botox and fillers: the new rejuvenation paradigm. *Dermatol Ther* 2004; 3:88-177.
- [21] Steven F et al Treating glabellar lines with botulinum toxin type A hemagglutinin complex: a review of the science, the clinical data, and patient satisfaction. *Clin Interv Ageing* 2010; 5:18-101.
- [22] Kowalski J W, Ray Patient-reported benefit and satisfaction with botulinum toxin type a treatment of moderate to severe glabellar rhytides: results from a prospective open-label study. *Plastic Reconstr Surg.*2007; 5:93-120.

- [23] Alster T S, Lupton J R Botulinum toxin type B for dynamic glabellar rhytides refractory to botulinum toxin type A. *Dermatol Surg.*2007;5:516-8.
- [24] Tan M, Kim E et al Botulinum toxin type a in pregnancy. *Deprt.of Medicine.*2013; 59:1183-1184
- [25] Prager W, Bee E K et al Onset, longevity, and patient satisfaction with incobotulinumtoxina for the treatment of glabellar frown lines: a single-arm, prospective clinical study. *Clin Interv Aging*2013; 8: 449-56.
- [26] Chauhan D S, Cariappa K M, Guruprasad Y Botulinum toxin type for the treatment of hyperkinetic lines of the face. *J Maxillofac Surg*2013; 2:83-173.
- [27] Kang S M, Feneran A et al Exaggeration of wrinkles after botulinum toxin injection for forehead horizontal lines. *J. Maxillafac Surg.*2011; 21-22.
- [28] Stengel G, Bee E K Antibody-induced secondary treatment failure in a patient treated with botulinum toxin type a for glabellar frown lines. *Clin Interv Ageing.*2011; 6:481.
- [29] KassirR, Kolluru A, Kassir M Triple-blind, prospective, internally controlled comparative study between abobotulinumtoxina and onabotulinumtoxina for the treatment of facial rhytids. *Dermatol Dept.* 2013; 2:179-89.
- [30] Carruthers J, and Carruthers A Aesthetic botulinum a toxin in the mid and lower face. *Dermatol Surg.*2004; 5:151
- [31] Kassir R, Kolluru A et al, Triple-blind, prospective, internally controlled comparative study between abobotulinumtoxinA and onabotulinumtoxinA for the treatment of facial rhytides.2013; 2:183-184.
- [32] Vartanian A J, Steven H D Complications of botulinum toxin A use in facial rejuvenation. *Plast Surg Clin North Am.* 2003; 11(4):483-92.
- [33] Min Kang E S, Ashley F et al Exaggeration of wrinkles after botulinum toxin injection for forehead horizontal lines. *Dept of dermatol.* 2011; 2:21-217.
- [34] Prager W, Bee E K et al Onset, longevity, and patient satisfaction with incobotulinumtoxinA for the treatment of glabellar frown lines: a single-arm, prospective clinical study, *Clin Interv Aging.*2013; 450-451.
- [35] Cheng C M, Cosmetic use of botulinum toxin type A in the elderly. *Dermatol Surg.*2007; 83-85
- [36] Stengel G, Bee E K, Antibody-induced secondary treatment failure in a patient treated with botulinum toxin type A for glabellar frown lines. *Clin Interv Aging.*2011; 5; 283-284.

Annexure

ANNEXURE I

Documentation form for aesthetic treatment

Name of patient

Date of birth

Treatment with:

Botulinum toxin

Product:

Units (ml):

Merz Scale

	A	B	C	D	E	F	G	H	I	J	K
Value: Pre score											
Post score											

Date:

Case Sheet

“Evaluation of efficacy and safety of Botox in the management of facial wrinkles”

1. PERSONAL IDENTIFICATION:

NAME:

FATHER'S/HUSBAND'S NAME:.....

AGE/SEX:..... OCCUPATION

ADDRESS:

.....

PHONE NO

2. CHIEF COMPLAINT:.....

.....

3. HISTORY OF PRESENT ILLNESS:

4. MEDICAL HISTORY:

- Heart disease..... YES/NO
- Diabetes YES/NO
- Asthma..... YES NO
- Epilepsy YES/NO
- Hypothyroidism/Hyperthyroidism..... YES/NO
- Blood disorder YES/NO
- Any other YES/NO

5. PAST HISTORY:

- Previous Botox given
- Previous filler given
- Any side effect
- Date of injections given
- Leaser resurfacing with duration
- Any history of facial peels
- (superficial, superficial deep, medium, deep)
- Any aesthetic procedure done before

6. FAMILY HISTORY:

7. PROFESSIONAL HISTORY:

8. DRUG HISTORY:

9. HISTORY OF DRUG INTAKE (If any)

10. HABITS: Tobacco/chewing/smoking/alcohol any other...

EXTRAORAL EXAMINATION:

Symmetry of face:.....

Facial wrinkles present: YES/NO

Site of wrinkle:.....

Any scar present: YES/NO

DEPARTMENT OF ORAL AND MAXILLOFACIAL SURGERY

Santosh Dental College and Hospital, Ghaziabad

INFORMED CONSENT

I, Mr. /Ms.

S/O

Resident of

have been informed about all the benefits and risks during and after the surgical procedure. I am willingly participating in the study conducted by the department of Oral and Maxillofacial Surgery, Santosh Dental College and Hospital.

Should I choose to withdraw from this study at any point; I will be free to do so after giving prior information to the concerned surgeon.

Signature of Surgeon Incharge

Signature of Patient

Date: Date:

Signature of Parent/Guardian

Date:

MASTER CHART

Evaluation of Efficacy and safety of botox in the management of facial wrinkles

S. No.	Patient's Name	Gender	Age	Site of injection	Units of Botox injected	During Injection					After One Week		After One Week		Longevity of Botox injection
						Pain during injection	Bruising at injection site	Swelling at injection site	Redness at injection site	Eyelid ptosis	Double vision	LIKERT scale score (PSPSQ)	Pre-treatment MERZ scale score	Post treatment MERZ scale score	
1	R.P	M	44 Yr	FOREHEAD LINES	50U	Y	N	Y	Y	N	N	54	7	2	4 & 10 days
2	O.P	M	45 Yr	CROW'S FEET LINES	12U	N	N	N	N	N	N	53	4	2	4 months
3	K.D	F	37 Yr	FOREHEAD & CROW'S FEET LINES	50U	N	Y	N	Y	N	N	56	13	3	4 & 7 days
4	L.P	F	52 Yr	FOREHEAD LINES	100U	N	Y	N	N	N	N	50	12	2	4 & 19 days
5	M.E	F	32 Yr	FOREHEAD LINES	100U	N	N	N	N	N	N	57	5	1	4 months
6	K.K	M	28 Yr	FOREHEAD LINES	45U	Y	N	N	N	N	N	54	7	2	4 months
7	I.K	M	32 Yr	CROW'S FEET LINES & FOREHEAD LINES	50U	N	N	Y	N	N	N	54	13	4	4 months 3 days
8	S.R	F	51 Yr	FOREHEAD LINES	50U	N	N	N	N	N	N	54	10	3	4 months 4 days
9	M.D	F	54 Yr	GLABELLAR & CROW'S FEET LINES	40U	N	N	N	N	N	N	50	13	6	4 months
10	S.T	M	35 Yr	GLABELLAR & HORIZONTAL FOREHEAD LINES	100U	N	N	N	N	N	N	55	6	2	4 months 3 days
11	K.P	M	48 Yr	GLABELLAR LINES	16U	N	N	N	N	N	N	55	5	2	3 months 19 days
12	B.D	F	55 Yr	CROW'S FEET LINES & HORIZONTAL FOREHEAD LINES	66U	N	N	N	N	N	N	56	14	4	4 months 2 days
13	S.D	M	29 Yr	GLABELLAR & CROW'S FEET LINES	30U	N	N	N	N	N	N	51	6	2	4 months
14	A.K	F	27 Yr	GLABELLAR & HORIZONTAL FOREHEAD LINES	60U	Y	N	N	Y	N	N	52	8	1	4 months 7 days
15	N.D	F	57Yr	GLABELLAR & CROW'S FEET LINES HORIZONTAL FOREHEAD LINES	100U	N	N	N	N	N	N	55	14	5	4 months