

Ectopic Pregnancy - Practise Essentials, Management - A Continuing Cause of Maternal Morbidity



Dr. Vinu Choudhary*, Dr. Surendra Bisu, Dr. Pavitra Sharma, Dr. Priyanka Rahariya

Senior Resident, Dept. of Obstetrics & Gynaecology, Sawai Man Singh Medical College & Hospital, Jaipur, Rajasthan

Abstract:

It is currently leading casue of pregnancy related death in 1st trimester.

Beside immediate mortality and morbidity, women's future ability to reproduce is also be adversely affected with advent of new diagnostic modalities, early detection and high index of suspicion in ectopic pregnancy morbidity and mortality have considerably declined. Several case report over past few decades revealed that the management of ectopic pregnancy have been revolutionized.

A high index of suspicion coupled with early clinical diagnosis supported by tvs and quantitative baseline serum BHCG has paved the way of medical treatment, thereby reducing morbidity and mortality and financial burden casued by it.

We are presenting the modalities of management in our institute of patient presenting with ectopic pregnancy over a period of one year from 1 aug 2016 to 1 January 2017.

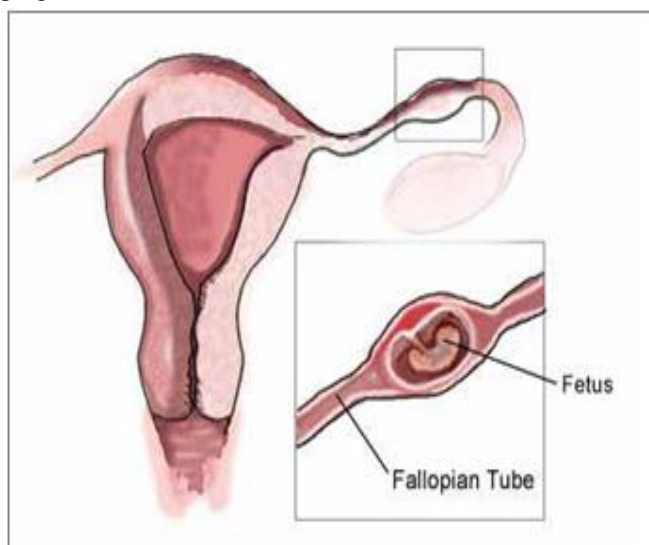
Among 14 patients, majority of them were multi gravid, among which 2 presented with history of infertility treatment. 60% of patient had ampulla as the site of ectopic pregnancy. Among the 14 patient, 3 patients were treated conservative management with inj methotrexate 1mg/kg wt repeat dose every weekly till bhcg.

Definition

When fertilized egg develops anywhere other than endometrial cavity of uterus is known as ectopic pregnancy. Ectopic pregnancy is defined as the implantation and development of the ovum outside the normal uteine cavity

Incidence

Incidence of ectopic pregnancy is 1:150 in normal pregnancies.



Ectopic Pregnancy is a common life-threatening condition affecting about 0.25-1% of all pregnancies

The mortality rate is about 1 per 1000 ectopics (10% of all maternal deaths). Ectopic pregnancy rate increased almost 4 fold (from 4.5 per 1000 pregnancies to 16.8 per 1000 pregnancies since 1970). Fatality rate from ectopic pregnancies dropped almost 90% (from 35.5 per 1000 ectopics to 3.8 per 1000 ectopics). Most ectopic pregnancies occur in women aged 25-34 years. Over 75% of ectopics are diagnosed before 12th week of gestation

Sites of ectopic pregnancy

Extra uterine
 Tubal pregnancy- 97 %
 Ampullary- 55 %
 Isthmus- 25 %
 Infundibular- 18 %
 Interstitial- 2 %
 Abdominal pregnancy- 1 %
 Ovarian pregnancy- 0.5%
 Uterine
 Cervical
 Cornual
 Caesarian scar

Incidence of ectopic pregnancy

Increased due to PID, use of IUCD, tubal surgeries and assisted reproductive techniques. Ranges from 1:25 to 1:250. Average range is 1 in 100 normal pregnancies. Recurrence rate- 15% after 1 and 25% after 2 ectopics

Etiology

Tubal pregnancy occurs either because the fallopian tube offers the fertilized egg a congenital environment for implantation or any delay in the ovum transport across the fallopian tube causes the fertilized egg to implant in the tube itself.

The risk factors predisposing to ectopic tubal implantation may be Congenital or Acquired.

Congenital factors: - Tubal hypoplasia, tortuosity, congenital diverticuli (rudimentary horn) and accessory ostia.

Acquired factors: - Pelvic infections
Tubal sterilization and constructive surgeries

Contraceptive use: Progestasert > Copper containing IUCD > Progesterone Only Pill

Infertility treatments: IVF, Ovulation induction using clomiphene and gonadotropin

H/o previous ectopic pregnancy
Endometriosis or leiomyoma

Diagnosis & clinical presentation

Clinical Presentation of acute ectopic pregnancy
Amenorrhoea (seen in 75% cases) followed by:

- Abdominal pain (acute, agonizing pain) seen in 100% cases.

It is the most consistent symptom of ectopic pregnancy.

- Appearance of vaginal bleed
Features of shock – pulse rapid & feeble, hypotension, cold & clammy.

Abdominal Examination: Abdomen-tense, tender and distended Shifting dullness may be present (depending on the amount of hemorrhage). Muscle guarding usually absent Cullen's sign - bluish discoloration around the umbilicus may be present.

- Unilateral adnexal mass may be palpated. On Bimanual examination
- Vaginal mucosa appears blanched
- Uterus: normal size / slightly bulky
- Extreme tenderness on cervical movement
- Fornices - tender

No mass generally felt through fornices
Unruptured tubal ectopic pregnancy

Amenorrhoea.

Continuous uneasiness on one side of flank sometimes may be colicky.

Bimanual examination; Uterus soft with evidence of pregnancy.

A pulsatile small, well circumscribed tender mass may be felt in fornix, separate from uterus.

Clinical Presentation of a chronic ectopic pregnancy

Amenorrhoea

Lower abdominal pain - acute or dull aching

Vaginal bleeding - scanty, dark colored and continuous in nature

Others dysuria, rise of temperature

On examination

Looks ill

Pulse persistently high

Features of shock absent

Bimanual examination-Pale vaginal mucosa

Uterus may be bulky

Illdefined boggy extremely tender mass felt in fornix

Differential diagnosis

1. Obstetric causes

Abortion of early intrauterine pregnancy (incomplete and missed abortion)

Septic abortion

Pregnancy with ruptured corpus luteal cyst

Pregnancy with ovarian torsion

Pregnancy with degenerated fibroid

2. Gynecological causes

DUB

Endometriosis

Ruptured Corpus luteum

Torsion of adnexal mass

Acute /Subacute Salpingitis

Fibroid with degeneration

Non Gynecological conditions

Appendicitis

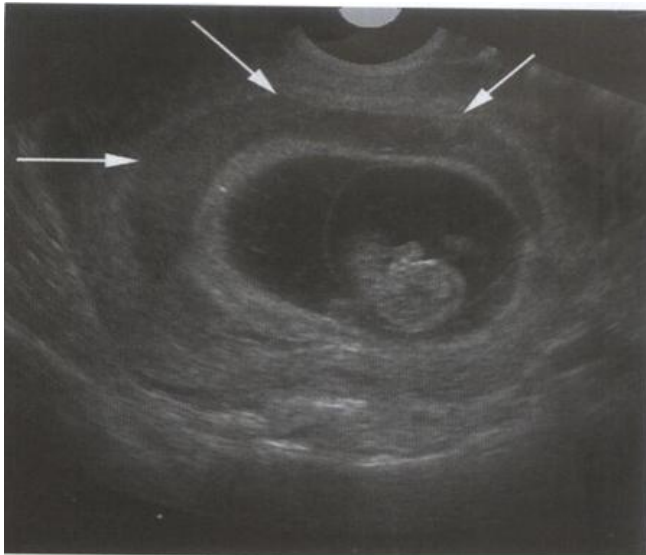
Gastroenteritis

Perforated peptic ulcer

Renal Colic

Mesenteric embolism

Subchorionic haemorrhage



Subchorionic hemorrhage at 10 weeks. Note the crescentic appearance of the blood products (arrows) as they confirm to the uterine shape.

Spontaneous Abortion

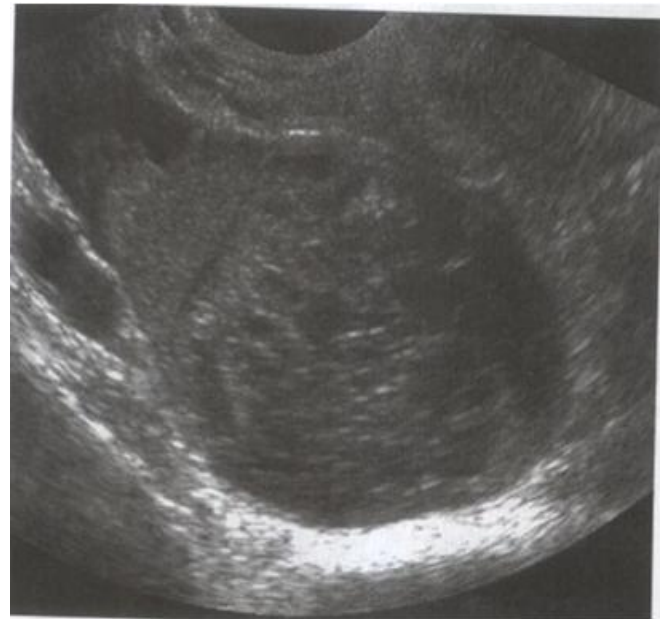Clinical Features

- The initial period of amenorrhoea tends to be longer
- Bleeding appears prior to pain, the reverse is seen in tubal pregnancy
- Bleeding is bright red and profuse
- General condition is proportionate to visible blood loss
- No features of intraperitoneal bleeding
- Fornix palpation gives negative findings
- D and E relieves the symptoms
- Histological examination shows presence of villi

Ruptured Corpus Luteum Cyst

Clinical Features

Short period of amenorrhoea
Pain abdomen
Slight vaginal bleeding
UPT negative

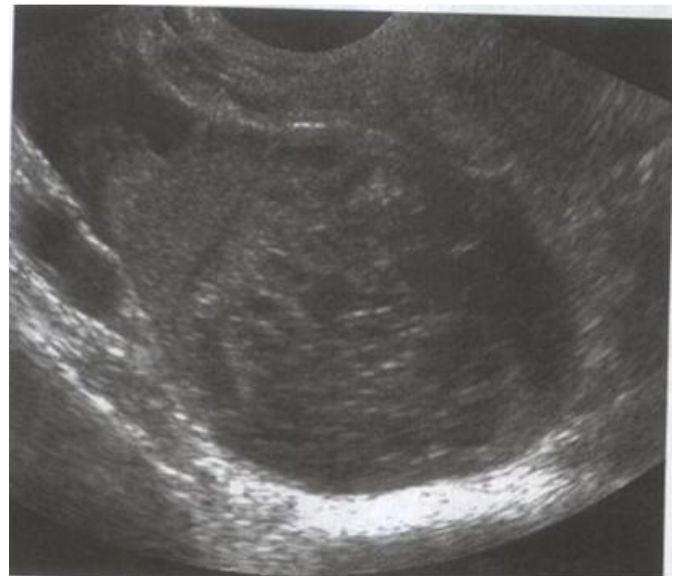

Hemorrhagic corpus luteum cyst. Note the heterogeneous cyst contents with strands of internal echoes .

Endometriosis

Clinical Features

Dysmenorrhoea with premenstrual intensification
Dyspareunia and pain abdomen

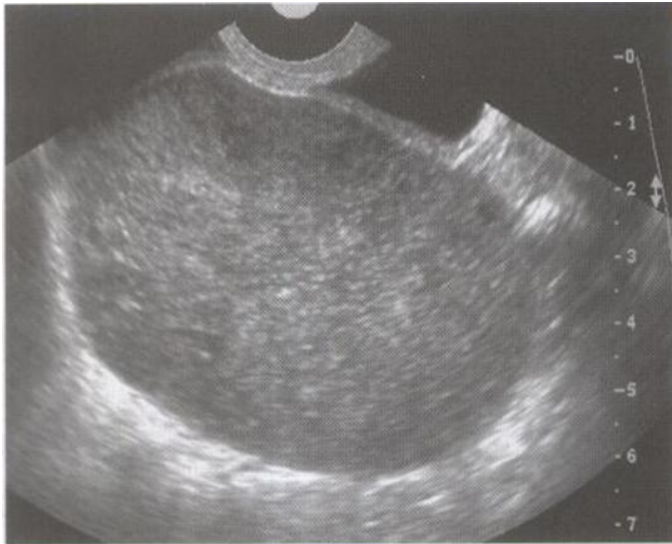

Hemorrhagic corpus luteum cyst. Note the heterogeneous cyst contents with strands of internal echoes .

Ovarian Torsion

Clinical Features

Pain abdomen
Tenderness
Nausea / Vomiting



Torsion in a patient with acute right lower quadrant pain. Transvaginal view shows an enlarged edematous-appearing ovary.

Salpingitis

Clinical Features

Previous history of similar attacks of pain is present

Pain is burning in nature

It is bilateral.

Amenorrhea is absent (although slight bleeding may appear)

Rise of temperature is more

It is unlikely to cause fainting / collapse

Pelvic examination shows bilateral tenderness or bilateral mass may be palpable

Leucocytosis is present

Mode of termination

Such pregnancy terminates between 6-8 weeks.

Earliest interruption in isthmic implantation 6-8 weeks as it is the narrowest part of the tube and least distensible.

Interstitial pregnancy usually terminates between 3-4 months and ampullary in 8-12 weeks.

1. Tubal mole- Small haemorrhages occur in chorio-capsularis space separating the villi from their attachments.

Fate of tubal mole-

- Complete absorption
- Abortion - Complete, incomplete
- Pelvic haematocele

2. Tubal abortion- Common in ampullary/infundibular pregnancy

- Complete - peritubal/pelvic haematocele
- Incomplete - diffuse intraperitoneal haemorrhage

3. Tubal rupture- Common in isthmic and interstitial pregnancy.

- Roof- diffuse intraperitoneal haemorrhage
- Floor- intraligamentary haematoma or paratubal haematoma

4. Tubal perforation

- Roof- secondary abdominal pregnancy
- Floor- secondary intraligamentary pregna

Diagnosis

By history and clinical examination suspected ectopic pregnancy can be divided into three groups.

Acute ectopic

Chronic ectopic

Unruptured ectopic pregnancy In the management of acute ectopic pregnancy, when patient is obviously ill due to severe internal bleeding there is no need and no time for any investigation other than HB, blood grouping, cross matching and immediate resuscitation along with laparotomy. In sub-acute variety certain investigations may be required to confirm the diagnosis.

Hormonal tests:-

Urine pregnancy test: - Positive only in 50% cases

β -hcg estimation:

Serum β -hCG levels less than 1500 IU/L is seen in ectopic pregnancy. If the level does not rise or rises by less than 66 % from previous reading, ectopic pregnancy or missed abortion should be suspected.

Culdocentesis:

Aspiration from pouch of Douglas is helpful if non clotted blood can be aspirated. Presence of blood in the pouch justifies laparotomy.

Ultrasound:

In an ectopic pregnancy uterus appears empty and a mass can be located in one of the lateral fornix. β -hCG in the urine and serum, empty uterus, adnexal mass and free fluid in the peritoneal cavity is pathognomic of an ectopic pregnancy. Transvaginal ultrasound detects uterine gestation sac 1 wk earlier than transabdominal probe.

True and pseudo gestation sac

Character	True GS	Pseudo GS
Location	Eccentrically	Centrally
Shape	Round & regular	Irregular
Double ring sign	Present	Absent
Yolk sac and fetal pole	Present	Absent
Increase in sac size	1 mm/ day	Absent

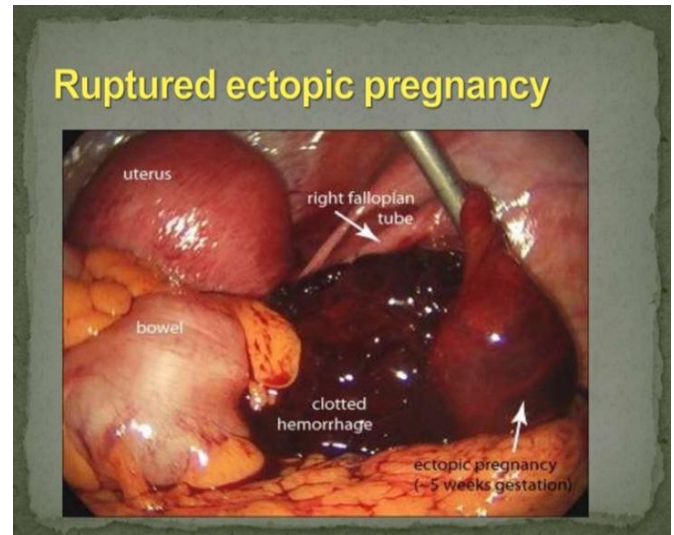
Demonstration of the gestational sac with or without a live embryo (Begel's sign).

The gestational sac appears as an intact well defined tubal ring by 6 weeks when it measures 5 mm in diameter.

Afterwards it can be seen as a complete sono lucent sac with the yolk sac and the embryonic pole with or without heart activity inside

Dilatation and Curettage: Finding of decidua without chorionic villi is suggestive of ectopic pregnancy.

Laparoscopy: This is the gold standard for diagnosing ectopic pregnancy. It is useful when ectopic pregnancy is suspected and there are no signs of extrauterine gestational sac and serial beta HCG levels are rising inappropriately and ultrasound shows no intrauterine gestational sac.



MANAGEMENT OF ECTOPIC PREGNANCY

Expectant Management

All cases of chronic or suspected ectopic admitted and kept under observation in hope of spontaneous resolution.

Indication

Decreasing serial HCG titres.

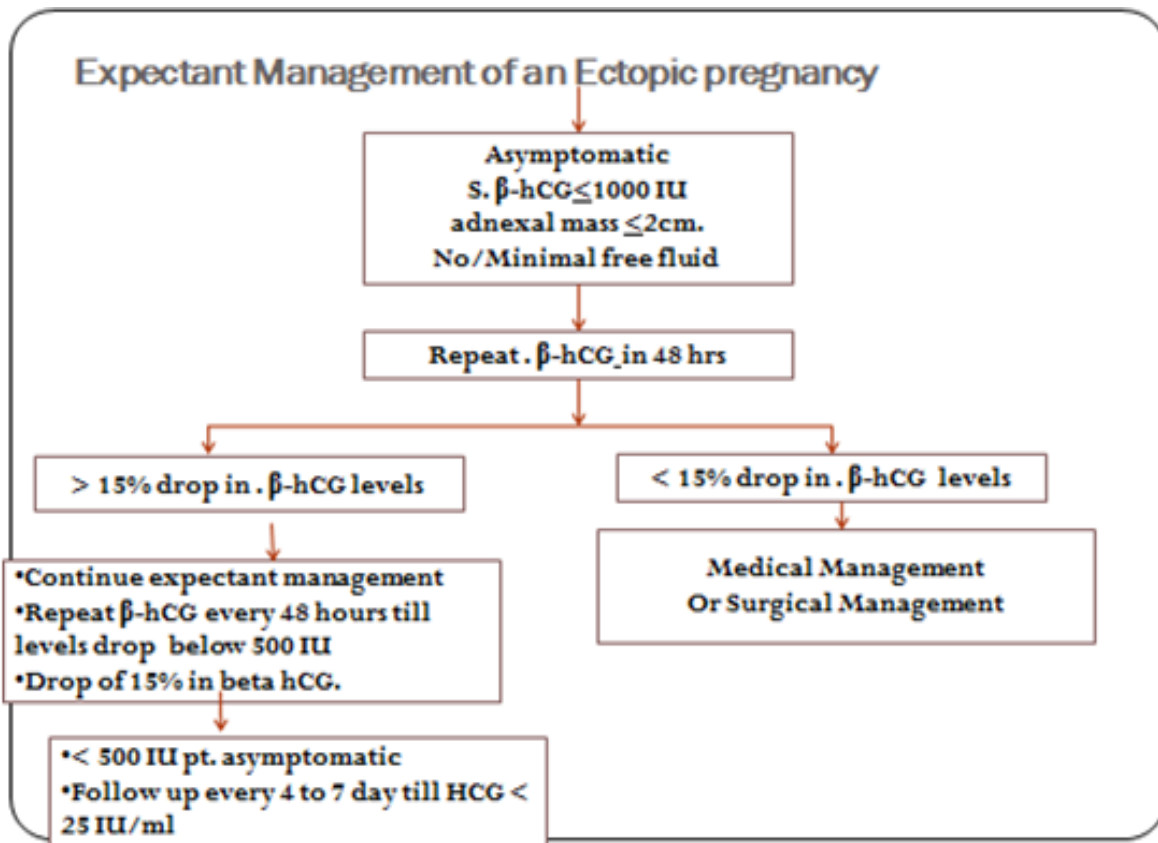
Tubal pregnancies only.

No evidence of intra-abdominal bleeding or rupture assessed by vaginal sonography.

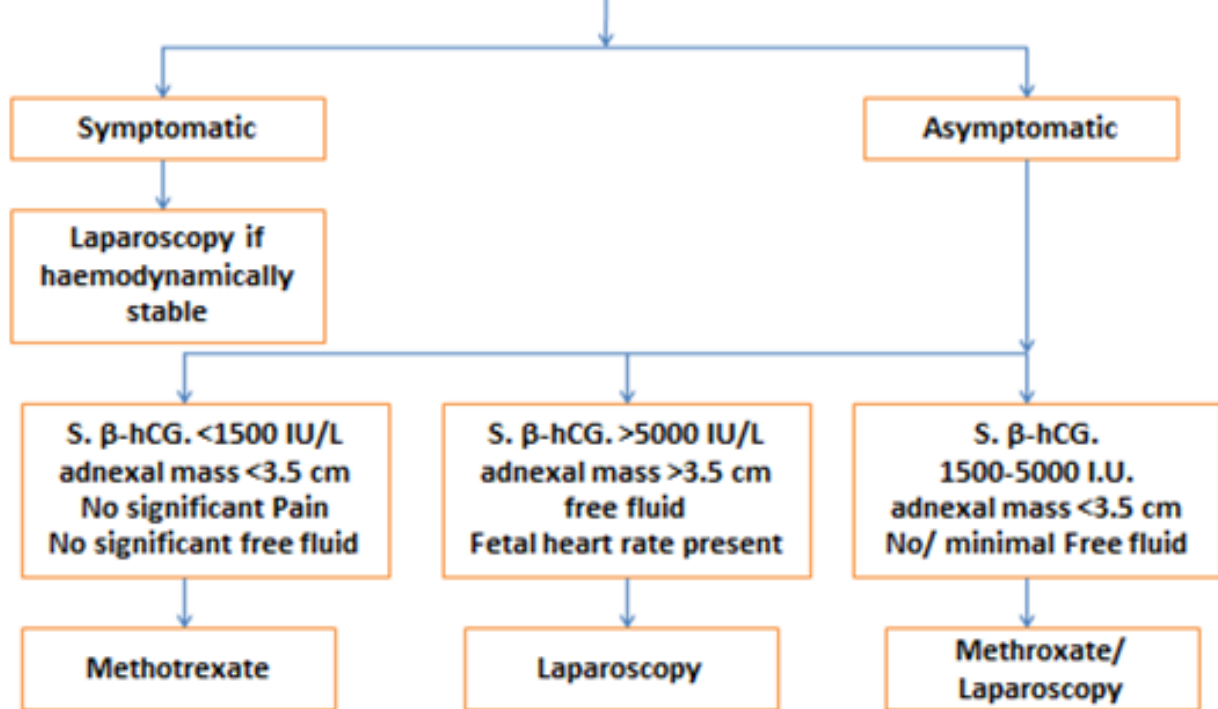
Diameter of the ectopic mass <3.5 cms.

Additional Criteria

Baseline HCG < 1000 IU/L & falling for best results.



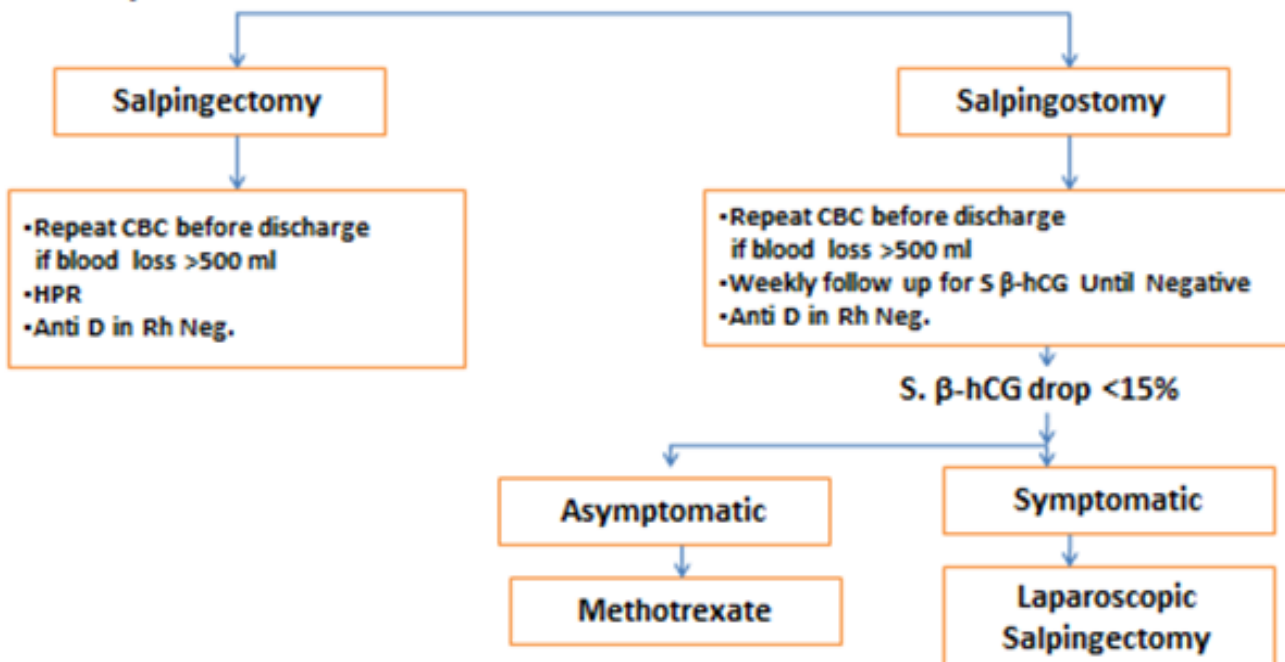
NICE GUIDELINES FOR MANAGEMENT OF AN ECTOPIC PREGNANCY

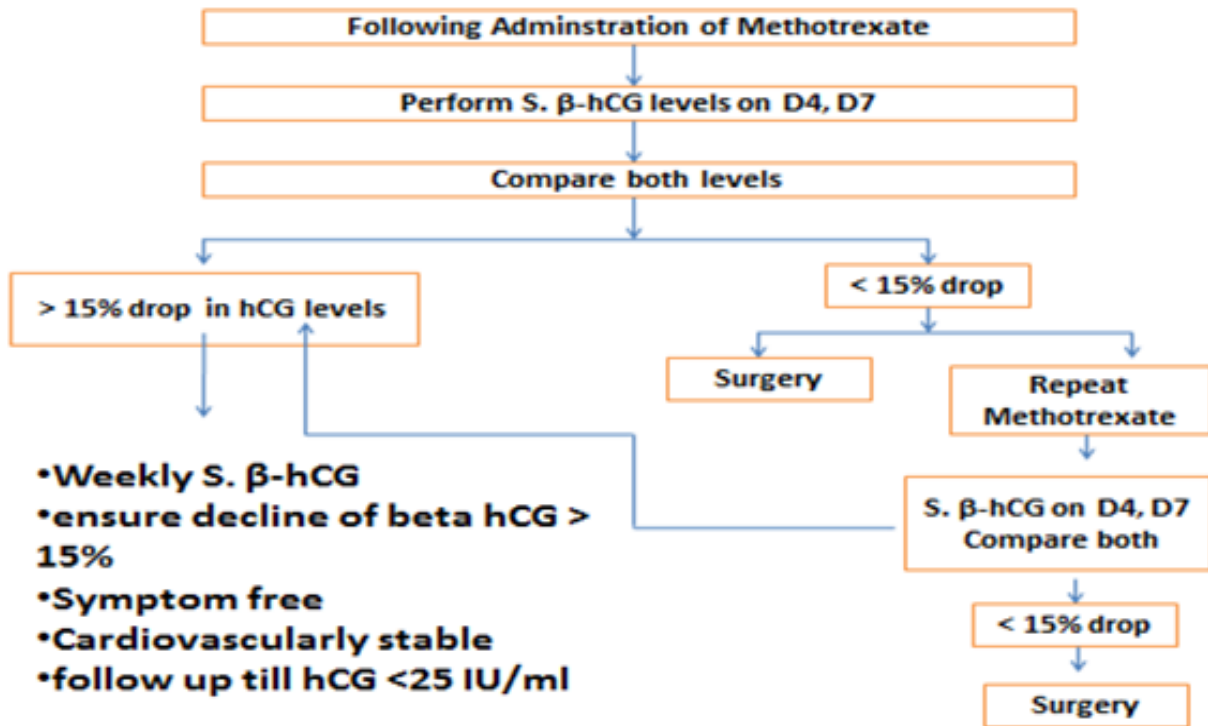


SURGICAL MANAGEMENT OF ECTOPIC PREGNANCY In HAEMODYNAMICALLY STABLE PATIENT

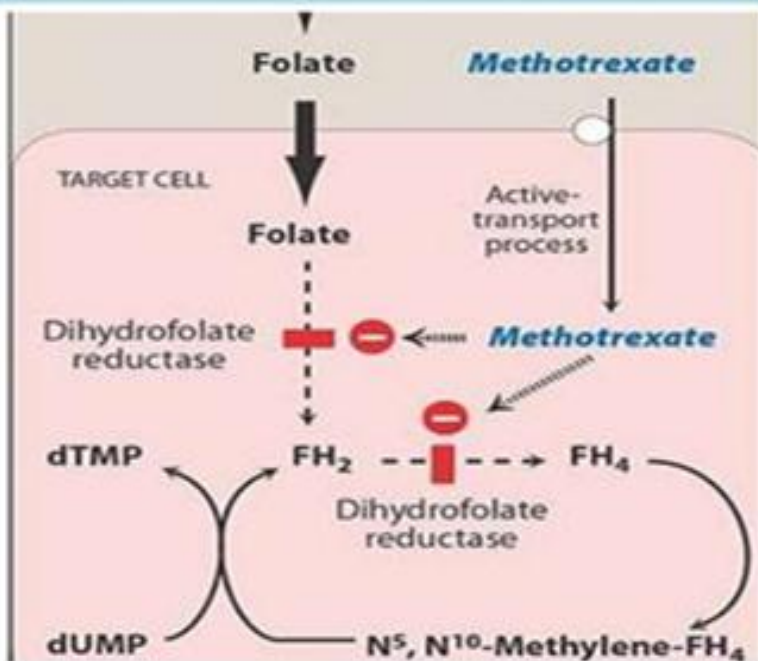
Patient Criteria

1. Adnexal Mass > 3.5 cm
2. Fetal Heart rate present.
3. S. β-hCG > 5000 IU/l





Methotrexate



Folic acid not useful in toxicity

Folinic acid N^5 formyl FH_4 should be given which is converted to N^5, N^{10} -Methylene- FH_4 and bypasses the inhibited reductase

Adenine, guanine, thymidine, methionine, serine

28

Medical Management

Absolute Requirements

Hemodynamic stability.
 No evidence of acute intra-abdominal bleeding.
 Reliable commitment to comply with required follow-up care.
 No contraindications to treatment.

Preferable Requirements

Absent or mild pain.
 Serum beta HCG level less than 10,000 IU/L (best results seen with HCG < 2000 IU/L).
 Absent embryonic heart activity.
 Ectopic gestational mass less than 3.5 cms in diameter

Medical Management

- Surgically administered drugs
 - Methotrexate
 - Potassium chloride
 - Prostaglandins(PGF2 α)
 - Hyperosmolar Glucose
 - Actinomycin D
 - Vasopressin
- Systemic drug
 - Methotrexate

Surgical Management

It is done in all those patients who did not fulfill the criteria laid down for medical management.

It should be done in all cases of ruptured ectopic.

Laparoscopy Indicated in Haemodynamically stable patients.

Laparotomy Indications

Patient is hemodynamically unstable.

Ruptured ectopic.

Cornual pregnancy/interstitial pregnancy.

Abdominal/ovarian pregnancy.

When laparoscopy is difficult due to extensive abdominal and pelvic adhesions

Conservative Surgery

Salpingostomy

It is the procedure of choice when the patient has an unruptured ectopic pregnancy and wishes to retain her future fertility.

Done to remove a small pregnancy less than 2 cm in length and located in the distal third of the fallopian tube.

The recommended surgical procedure for ampullary ectopic pregnancy.

Salpingotomy

Same as salpingostomy,incision line sutured

Segmental resection and anastomosis

It is the procedure of choice in isthmic pregnancy. Fimbrial expression

Ideal in cases of distal ampullary pregnancy and is done digitally.

Radical Surgery

Salpingectomy

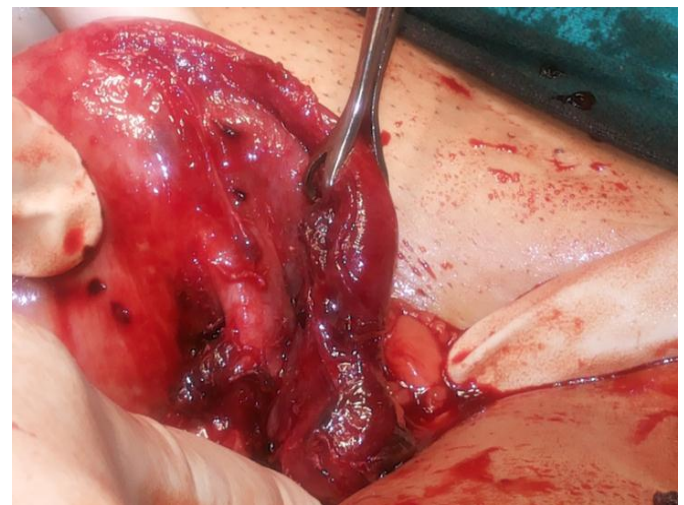
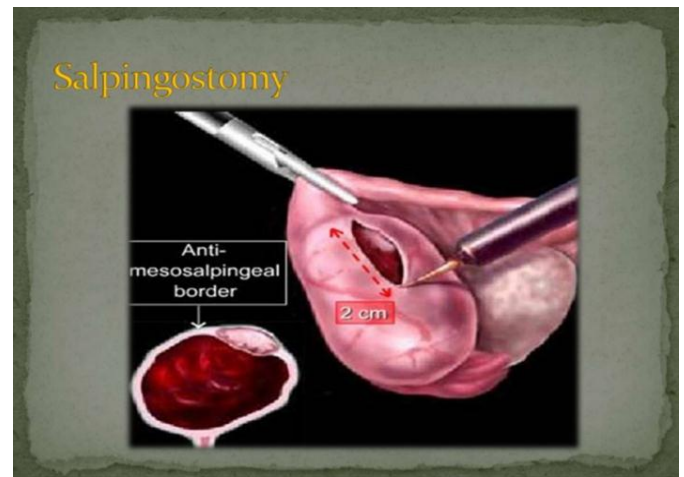Salpingo Oophorectomy

Indications

The patient has completed her family.

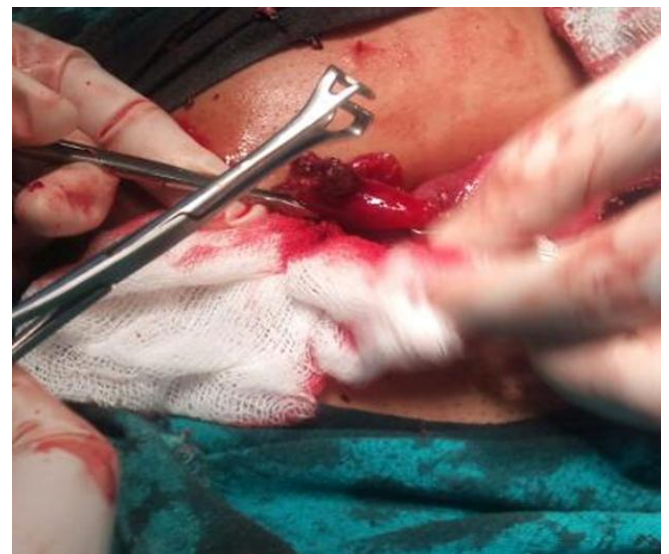The tubes are grossly damaged.

Ectopic pregnancy has recurred in a tube already treated conservatively.Uncontrolled bleeding. Uncontrolled bleeding

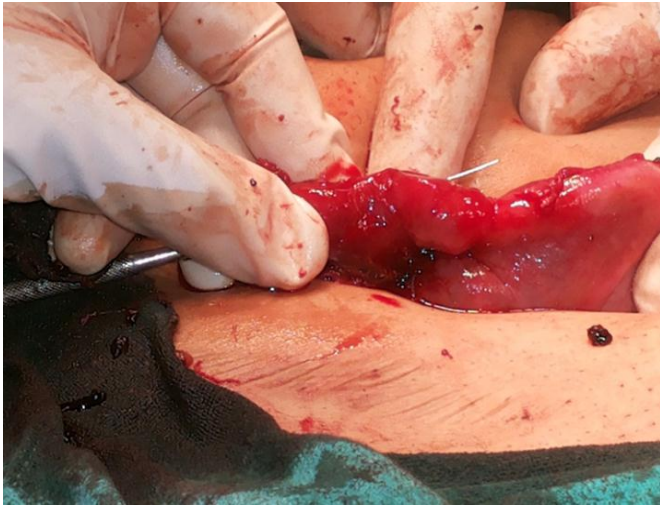


- Linear horizontal incision of around 2cm given on antimesentric border of right fallopian tube.

Product scooped out and saved in formaline for histopathology report.



Probe inserted from fimbrial end than incision stiched with Vicryl no 5-0



Interstitial pregnancy

Definition: - A pregnancy developing in the interstitial portion of fallopian tube.

Usually rupture at 12-14 wks.

Soft, tender, asymmetrical enlargement of uterus seen on examination.

USG Criteria: -

Empty uterine cavity.

Chorionic sac seen separately 1 cm from the most lateral edge of the uterine cavity.

A thick myometrial layer surrounding the chorionic sac.

Interstitial line sign - It is an echogenic line extending from the endometrial cavity into the cornual region and abutting the gestational sac.

It prevent recurrence of the intersitital pregnancy.

Differential Diagnosis

Pregnancy in bicornuate uterus.

Fibroid in pregnant uterus

Ecentrically located intrauterine pregnancy.

Management

Conservative – Ultrasound guided medical treatment.

Laparotomy - Ipsilateral uterine artery ligation f/b excision of interstitial pregnancy by cornual resection or with salpingectomy.

Ovarian pregnancy

Spiegelberg Criteria: -

Tube on the affected site must be intact.

Gestational sac occupies the normal position of the ovary.

Gestational sac connected to the uterus by uteroovarian ligament.

Ovarian tissue must be found on its wall on histological examination.

Abdominal pain before 7 week is typical presentation. In USG gestational sac may be seen.

D/D

- Haemorrhagic corpus luteum cyst.
- Spontaneous abortion with a haemorrhagic corpus luteum cyst.

Management

- If Early Diagnose - Localise surgical resection of the mass with conservation of the ovary.

In Late Case - oophorectomy

Abdominal pregnancy

Gestational sac implanted in the peritoneal cavity.

Primary - is rare

Secondary

MMR is very high due to high incidence of internal haemorrhage and sepsis.

Clinical Presentation

H/o disturbed tubal pregnancy during early month.

Minor eliments of normal uterine pregnancy are exaggerated as nausea, vomiting.

Decrease fetal movement and pain abdomen.

P/A Examination

Uterine contour is not well defined.

Persistent abnormal attitude and position of fetus on repeated examination.

Studiford Criteria of Primary Abdominal Pregnancy

Both the tube and ovary must be normal.

Absence of uteroperitoneal fistula.

Presence of a pregnancy related exclusively to the peritoUSG

Gestational sac lies outside the uterus.

Abnormal fetal lie usually above the maternal pelvis.

Extrauterine placental tissue.

Management

Urgent laparotomy irrespective of the period of gestation.

Laparotomy - Promote delivery of the fetus with removal of the placenta (If it is accessible and without excessive blood loss).In case of doubt clamp the cord, to leave the placenta in situ and close the abdomen.

Methotrexate should not be given.

Cervical pregnancy

Definitions: - A pregnancy developing in the cervical canal below the level of internal os.

1% of all ectopic pregnancy.

Rubin Criteria

Cervical gland must be opposite the placental attachment.

Placental attachment to the cervix must be situated below the uterine vessels entrance or below peritoneal reflexion of the anterior surface of the uterus.

Fetal element must be absent from the corpus uteri. Clinical Presentation

Painless 1st trimester bleeding P/V.

Lower abdomen discomfort and cramping pain.

Increase pelvic pressure or back pain.

Examination

Cervix appear cyanotic, hyperemic and soft in consistency.

External os usually open or may reveals bulging membrane.

Cervix diffusely enlarged reaching the size of uterus.

D/D

Spontaneous abortion

Cervical tumour

Placenta previa

USG

Exact location of the gestational sac below the level of uterus corpus.

Trophoblastic invasion of the cervix - it appear as hyperechogenic trophoblastic thick ring around the implantation site.

Visualization of endocervical canal extending above the margin of GS.

Localisation of the placenta in cervix.

Sliding sign absent - If gentle pressure on the cervix given by USG probe GS slide in case of spontaneous abortion Doppler

Peritrophoblastic blood flow from an active vascular supply

Management

Systemic chemotherapy.

- * GA <6 wks without cardiac activity.
- * Multi dose regime of Methotrexate is more effective.

Intraamniotic Methotrexate or KCL.

- * If GA is <12 wks and fetal heart activity present intraamniotic KCL 3.5 ml of 2 mEq/ml should be

administered first f/b systematic Methotrexate. Procedure performed under the TVS.

Hysterectomy

1. Hemodynamically unstable patients
2. If family is completed
3. Uterine pathology present
4. Age > 40 yrs

Ectopic Pregnancy- Our Vision

It is currently leading casue of pregnancy related death in 1 st trimester.

Beside immediate mortality and morbidity, women's future ability to reproduce is also be adversely affected with advent of new diagnostic modalities , early detection and high index of suspicion in ectopic pregnancy morbidity and mortality have considerably declined. Several case report over past few decades revealed that the management of ectopic pregnancy have been revolutionized.

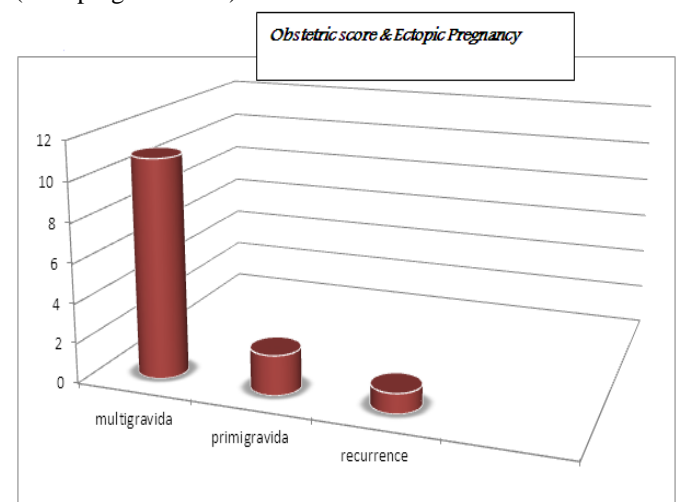
A high index of suspicion coupled with early clinical diagnosis supported by tvs and quantitative baseline serum BHCG has paved the way of medical treatment, thereby reducing morbidity and mortality and financial burden casued by it.

We are presenting the modalities of management in our institute of patient presenting with ectopic pregnancy over a period of one year from 1 aug 2016 to 1 January 2017.

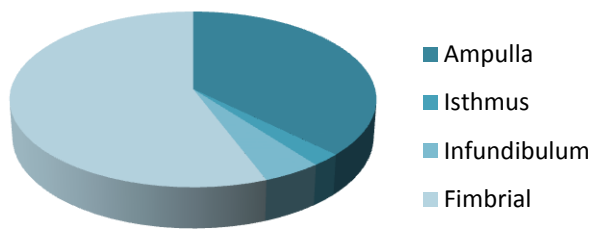
Among 14 patients, majority of them were multi gravid , among which 2 presented with history of infertility treatment . 60% of patient had ampulla as the site of ectopic pregnancy. Among the 14 patient, 3 patients were treated conservative management with inj methotrexate 1mg/kg wt repeat dose every

Weekly till bhcg <2 iu

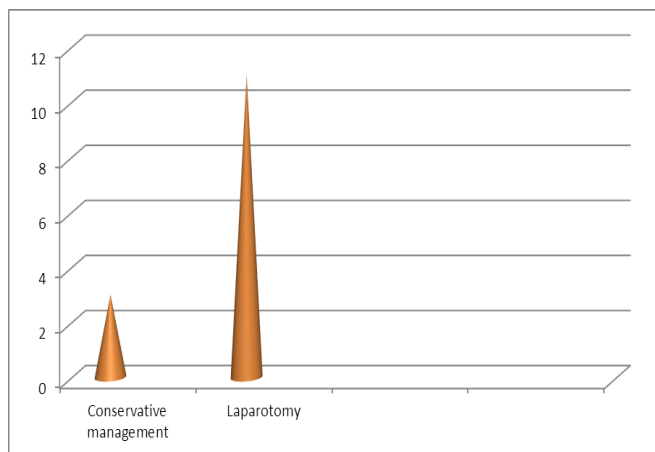
(Non-pregnant level)



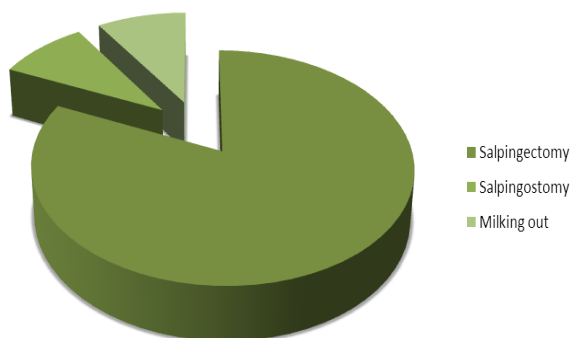
Sites of Ectopic Pregnancy



Among the remaining patient except one, in which laparoscopic removal followed by aspiration done, rest all laprotomy was done. Amongst laparotomy, in one patient salpingostomy was done and in one milking out fimbrial expulsion was done.



Sales



Pregnancy is likely to occur among sterilized women, when it does there are a chance of ectopic pregnancy. In 1992 ectopic pregnancy accounted for 9% of all pregnancy related death. Because information on effectiveness of tubal sterilization in preventing pregnancy is limited, it has been difficult to determine the risk of ectopic pregnancy after

tubal sterilization. According to a study by Peterson, the highest proportion of ectopic pregnancy was amongst women who underwent bipolar coagulation followed by interval partial salpiestomy.

Among the risk factor for ectopic pregnancy after tubal sterilization – method of sterilization, age at the time of sterilization, race or ethnic group, history of pelvic inflammatory diseases before sterilization. Were satisfactorily significant.

Ectopic pregnancy after tubal sterilization is not rare, particularly among women sterilized before age of 30 yr and all women undergoing this procedure should be informed that ectopic pregnancy may occur long after sterilization. Tubal surgery has been reported to be greatest risk factor for ectopic pregnancy, other risk factors - prior pid, h/o smoking, iucd, prior spontaneous or induced abortion and assisted reproductive technology. We present a case of spontaneously conceived pregnancy with a foetal heart beat in fallopian tube after ipsilateral salpingectomy is exceedingly rare and corneal rupture case reported in literature. Mechanism by which a recurrent ectopic pregnancy after ipsilateral salpingectomy occur is unclear. 3 theories

Contralateral fertilization occurred and fertilized egg migrated across endometrial cavity to fallopian tube remnant.

2) Occur of recanalization due to inadequate diathermy allowing for passage of the ovum on damaged side into tubal remnant.

Spermatozoa passes through patent fallopian tube travel to fallopian tube on damaged side. Further more studies reported that salpingectomy is associated with a lower rate of persistent trophoblast than salpingostomy.

Gynaecologist should be aware that ectopic pregnancy may not only occur repeatedly but may also present atypically. Therefore salpingectomy effort can be undertaken to minimize the length of tubal remnant to assure adequate coagulation of tissue to reduce the risk of recurrence.

Salpingostomy, salpingectomy, and tubal surgery

Data in the literature have failed to demonstrate substantial and consistent benefit from either salpingostomy or salpingectomy with regard to improving future reproductive outcome. However, despite the risk of persistent ectopic pregnancy, some studies have shown salpingostomy to improve reproductive outcome in patients with contralateral tubal damage. Yao and Tulandi concluded from a literature review that laparoscopic salpingostomy had a reproductive performance that was equal to or slightly better than

salpingectomy; however, slightly higher recurrent ectopic pregnancy rates were noted in the salpingostomy group.

In reporting on 10 years of surgical experience in Paris, Dubuisson et al concluded that, for selected patients who desire future fertility, using salpingectomy, which is simpler and avoids the risk of persistent ectopic pregnancy, is possible and can result in a comparable fertility rate to tubal conservation surgery. Future fertility rates were no different with either surgical approach when the contralateral tube was either normal or scarred but patent.

Clausen reviewed literature from the previous 40 years and concluded that only a small number of investigators have suggested, indirectly, that conservative tubal surgery increases the rate of subsequent intrauterine pregnancy. He also concluded that the more recent studies may reflect an improvement in surgical technique.

In an earlier study, Maymon et al, after reviewing 20 years of ectopic pregnancy treatment, concluded that conservative tubal surgery provided no greater risk of recurrent ectopic pregnancy than the more radical salpingectomy.

The modern pelvic surgeon has been led to believe that the treatment of choice for unruptured ectopic pregnancy is salpingostomy, sparing the affected fallopian tube and thereby improving future reproductive outcome.

However, if the treating surgeon has neither the laparoscopic skill nor the instrumentation necessary to atraumatically remove the trophoblastic tissue via linear salpingostomy, then salpingectomy by laparoscopy or laparotomy is not the wrong surgical choice. Leaving a scarred, charred fallopian tube behind after removing the ectopic pregnancy but requiring extensive cautery to control bleeding does not preserve reproductive outcome.

Fertility following surgery

Previous history of infertility has been found to be the most significant factor affecting postsurgical fertility.

Parker and Bistis concluded that when the contralateral fallopian tube is normal, the subsequent fertility rate is independent of the type of surgery. [36] Similarly, a prospective study of 88 patients by Ory et al indicated that the surgical method had no effect on subsequent fertility in women with an intact contralateral tube.

Several other studies reported that the status of the contralateral tube, the presence of adhesions, and the presence of other risk factors, such as endometriosis, have a more significant impact on future fertility than does the choice of surgical procedure.

According to Rulin, salpingectomy should be the treatment of choice in women with intact contralateral tubes, because conservative treatment provides no additional benefit and incurs the additional costs and morbidity associated with persistent ectopic pregnancy and recurrent ectopic pregnancy in the already damaged tube.

Future fertility rates have been found to be similar in patients who are treated surgically by laparoscopy or laparotomy. Salpingectomy by laparotomy carries a subsequent intrauterine pregnancy rate of 25-70%, compared with laparoscopic salpingectomy rates of 50-60%. Very similar rates exist for laparoscopic salpingostomy versus laparotomy.

A slightly higher recurrent ectopic pregnancy rate exists in patients treated by laparotomy (17-28%), regardless of conservative or radical approach, when compared with laparoscopy (18%). This surprising finding is believed to be secondary to increased adhesion formation in the group treated by laparotomy.

Comparison of medical and surgical treatment of small, intact extrauterine pregnancies also revealed similar success and subsequent spontaneous pregnancy rates in a prospective, randomized trial.

A study by Xu et al found that in women undergoing 51,268 fresh in vitro fertilization-intracytoplasmic sperm injection (IVF-ICSI) cycles, previous ectopic pregnancy has no effect on IVF-ICSI outcomes. The study also found that women with a prior history of ectopic pregnancy have a higher recurrence risk of ectopic pregnancy after IVF in comparison with women with no history of ectopic pregnancy.

Methotrexate versus surgery

The success rates after methotrexate are comparable with laparoscopic salpingostomy, assuming that the previously mentioned selection criteria are observed. The average success rates using the multiple-dosage regimen are in the range of 91-95%, as demonstrated by multiple investigators. One study of 77 patients desiring subsequent pregnancy showed intrauterine pregnancies in 64% of these patients and recurrent ectopic pregnancy in 11% of them. Other studies have demonstrated similar results, with intrauterine pregnancy rates ranging from 20-80%.

The average success rates for the single-dosage methotrexate regimen are reported to be from 88-94%. In a study by Stovall and Ling, 113 patients (94%) were treated successfully, 4 (3.3%) of whom needed a second dose. [39] No adverse effects were encountered. Furthermore, 87.2% of these patients achieved a subsequent intrauterine pregnancy, whereas 12.8% experienced a subsequent

ectopic pregnancy. [39] Other studies have reported similar results, with some mild adverse effects and lower reproductive outcomes.

A meta-analysis that included data from 26 trials demonstrated a success rate of 88.1% with the single-dose methotrexate regimen and a success rate of 92.7% with the multiple-dose regimen. [41] A small, randomized clinical trial also demonstrated the single-dose regimen to have a slightly higher failure rate. [42] A hybrid protocol, involving 2 equal doses of methotrexate (50 mg/m²) given on days 1 and 4 without the use of leucovorin, has been shown to be an effective and convenient alternative to the existing regimens. [43]

Complications

Complications of ectopic pregnancy can be secondary to misdiagnosis, late diagnosis, or treatment approach. Failure to make the prompt and correct diagnosis of ectopic pregnancy can result in tubal or uterine rupture (depending on the location of the pregnancy), which in turn can lead to massive hemorrhage, shock, disseminated intravascular coagulopathy (DIC), and death. Ectopic pregnancy is the leading cause of maternal death in the first trimester, accounting for 9-13% of all pregnancy-related deaths. In the United States, an estimated 30-40 women die each year from ectopic pregnancy.

Any time a surgical approach is chosen as the treatment of choice, consider the complications attributable to the surgery, whether it is laparotomy or laparoscopy. These include bleeding, infection, and damage to surrounding organs, such as the bowel, bladder, and ureters, and to the major vessels nearby. Infertility may also result secondary to loss of reproductive organs after surgery. Also consider the risks and complications secondary to anesthesia. Make the patient aware of these complications, and obtain the appropriate written consents.

Patient Education & Counselling

Advise patients receiving methotrexate therapy to avoid alcoholic beverages, vitamins containing folic acid, nonsteroidal anti-inflammatory drugs (NSAIDs), and sexual intercourse, until advised otherwise. A signed written consent demonstrating the patient's comprehension of the course of treatment must be obtained.

Provide an information pamphlet to all patients receiving methotrexate; the pamphlet should include a list of adverse effects, a schedule of follow-up visits, and a method of contacting the physician or the hospital in case of emergency, as well as the need to return to the emergency department for concerning symptoms.

Patients undergoing assisted reproduction technology should be educated regarding their risk of heterotopic pregnancy.

Patients with risk factors for ectopic pregnancy should be educated regarding their risk of having an ectopic pregnancy. Women who are being discharged with a pregnancy of unknown location should be educated regarding the possibility of ectopic pregnancy and their need for urgent follow-up.

Key message points

- Clinicians should be suspicious of ectopic pregnancy in any woman of reproductive age presenting with abdominal or pelvic symptoms. The diagnosis of ectopic pregnancy can be difficult and protracted.
- A diagnosis of 'pregnancy of unknown location' should trigger further diagnostic pathways and follow-up until the final outcome of the pregnancy is known.
- Medical management with methotrexate is successful for small, stable ectopic pregnancies.

References

- [1] Walker JJ. Ectopic pregnancy. *Clin Obstet Gynecol.* 2007; 50:89–99.
- [2] Della-Giustina D, Denny M. Ectopic pregnancy. *Emerg Med Clin North Am.* 2003; 21:565–584.
- [3] Varma R, Gupta J. Tubal ectopic pregnancy. *Clin Evid (Online)* 2009;2009:1409
- [4] Shaw JL, Dey SK, Critchley HO, et al. Current knowledge of the aetiology of human tubal ectopic pregnancy. *Hum Reprod Update.* 2010; 16:432–444.
- [5] Horne AW, Duncan WC, Critchley HO. The need for serum biomarker development for diagnosing and excluding tubal ectopic pregnancy. *Acta Obstet Gynecol Scand.* 2010; 89:299–301.
- [6] Farquhar CM. Ectopic pregnancy. *Lancet.* 2005; 366:583–591.
- [7] Goldner TE, Lawson HW, Xia Z, et al. Surveillance for ectopic pregnancy - United States, 1970-1989. *MMWR CDC Surveill Summ.* 1993; 42:73–85.
- [8] Chang J, Elam-Evans LD, Berg CJ, et al. Pregnancy-related mortality surveillance - United States, 1991-1999. *MMWR Surveill Summ.* 2003; 52:1–8.
- [9] Nama V, Manyonda I. Tubal ectopic pregnancy: diagnosis and management. *Arch Gynecol Obstet.* 2009; 279:443–453.

- [10] Leke RJ, Goyaux N, Matsuda T, et al. Ectopic pregnancy in Africa: a population-based study. *Obstet Gynecol.* 2004; 103:692–697.
- [11] Karaer A, Avsar FA, Batioglu S. Risk factors for ectopic pregnancy: a case-control study. *Aust N Z J Obstet Gynaecol.* 2006; 46:521–527.
- [12] Akande V, Turner C, Horner P, et al. British Fertility Society Impact of Chlamydia trachomatis in the reproductive setting: British Fertility Society Guidelines for practice. *Hum Fertil (Camb)* 2010; 13:115–125.
- [13] Shaw JL, Wills GS, Lee KF, et al. Chlamydia trachomatis infection increases fallopian tube PROKR2 via TLR2 and NF κ B activation resulting in a microenvironment predisposed to ectopic pregnancy. *Am J Pathol.* 2011; 178:253–260.
- [14] Clayton HB, Schieve LA, Peterson HB, et al. Ectopic pregnancy risk with assisted reproductive technology procedures. *Obstet Gynecol.* 2006; 107:595–604.
- [15] Steptoe PC, Edwards RG. Reimplantation of a human embryo with subsequent tubal pregnancy. *Lancet.* 1976; 1:880–882.
- [16] Furlong LA. Ectopic pregnancy risk when contraception fails. A review. *J Reprod Med.* 2002; 47:881–885. [PubMed] Ankum WM, Mol BW, Van der Veen F, et al. Risk factors for ectopic pregnancy: a meta-analysis. *Fertil Steril.* 1996; 65:1093–1099.
- [17] Bouyer J, Coste J, Shojaei T, et al. Risk factors for ectopic pregnancy: a comprehensive analysis based on a large case-control, population-based study in France. *Am J Epidemiol.* 2003; 157:185–194.
- [18] Shaw JL, Oliver E, Lee KF, et al. Cotinine exposure increases Fallopian tube PROKR1 expression via nicotinic AChR α -7: a potential mechanism explaining the link between smoking and tubal ectopic pregnancy. *Am J Pathol.* 2010; 177:2509–2515.
- [19] Talbot P, Riveles K. Smoking and reproduction: the oviduct as a target of cigarette smoke. *Reprod Biol Endocrinol.* 2005; 3:52.
- [20] Corpa JM. Ectopic pregnancy in animals and humans. *Reproduction.* 2006; 131:631–640. [PubMed]
- [21] Hasan R, Baird DD, Herring AH, et al. Patterns and predictors of vaginal bleeding in the first trimester of pregnancy. *Ann Epidemiol.* 2010; 20:524–531.
- [22] Weckstein LN, Boucher AR, Tucker H, et al. Accurate diagnosis of early ectopic pregnancy. *Obstet Gynecol.* 1985; 65:393–397.
- [23] Jehle D, Krause R, Braen GR. Ectopic pregnancy. *Emerg Med Clin North Am.* 1994; 12:55–71.
- [24] Chez RA, Moore JG. Diagnostic errors in the management of ectopic pregnancy. *Surg Gynecol Obstet.* 1963; 117:589–596.
- [25] Tay JI, Moore J, Walker JJ. Ectopic pregnancy. *BMJ.* 2000; 320:916–919.
- [26] Kaplan BC, Dart RG, Moskos M, et al. Ectopic pregnancy: prospective study with improved diagnostic accuracy. *Ann Emerg Med.* 1996; 28:10–17.
- [27] Lewis G, Drife J. Why Mothers Die 1997-1999: The Confidential Enquiries into Maternal Deaths in the United Kingdom. RCOG Press; London, UK: 2001.
- [28] Lewis G. The Confidential Enquiry into Maternal and Child Health (CEMACH). Saving Mothers' Lives: Reviewing Maternal Deaths to Make Motherhood Safe 2003-2005. RCOG Press; London, UK: 2007.
- [29] Cantwell R, Clutton-Brock T, Cooper G, O'Herlihy C, et al. Deaths in early pregnancy. In: Cantwell R, Clutton-Brock T, Cooper G, et al., editors. Centre for Maternal and Child Enquiries (CMACE). Saving Mothers' Lives: Reviewing Maternal Deaths to Make Motherhood Safe 2006-2008. RCOG Press; London, UK: 2011. pp. 81–84.
- [30] Robson SJ, O'Shea RT. Undiagnosed ectopic pregnancy: a retrospective analysis of 31 'missed' ectopic pregnancies at a teaching hospital. *Aust N Z J Obstet Gynaecol.* 1996; 36:182–185.
- [31] Wedderburn CJ, Warner P, Graham B, et al. Economic evaluation of diagnosing and excluding ectopic pregnancy. *Hum Reprod.* 2010; 25:328–333.