

# Clinical presentation of Cysticercosis in Bihar

Priyanka<sup>\*1</sup>, Prof. U.P Sinha<sup>2</sup>, Sunil Kumar<sup>3</sup>, Sunita Kumari<sup>4</sup>



## **Abstract:**

**Purpose:** To study the clinical presentation and treatment outcome of patients with ocular & extracocular cysticercosis in Bihar.

**Method:** The study included 14 patients who were diagnosed as ocular or extraocular cysticercosis presenting to Eye OPD. PMCH between January 2016 to March 2017. The mode of presentation, the results of various investigations and the treatment outcome of these cases were studied.

**Result:** The age of the patients were between 11 to 45 years. Two patients presented with subconjunctival F.B sensation and watering. Out of eight patients with NCC, three patients presented with Seizures, headache with vomiting and two with decreased vision while, two patients presented with complain of severe headache. One patient was asymptomatic and diagnosed with positive CT scan during routine examination for occasional headaches. Three patients with intraventricular cyst presented with floaters and diminished vision. One patient presented with proptosis.

CT scan was normal in cases with subconjunctival cyst. In all other patients with intravitreal cysts, orbital cyst and seven patients of NCC, CT scan was positive for cysts. In one patient with papilledema, CT was normal, hence MRI was done that showed vesicular lesions.

Two patients with subconjunctival cyst and three with intraventricular cyst underwent surgery for cyst removal. Rest patients were treated with Albendazole and Prednisolone. Patients with seizures were initially treated with anticonvulsants and mannitol. Three patients with optic atrophy did not improve. No Sign of improvement of vision was seen in patients with intravitreal cyst. Rest of the patients showed improvement with treatment.

**Conclusion:** - USG Bscan, CT scan, MRI and excisional biopsy of the cyst helps to establish the diagnosis of cysticercosis affecting eyes and brain.

**Keywords:** - Cysticercosis, Neurocysticercosis (NCC), subconjunctival cyst.

## **Introduction**

The disease is endemic in Africa, South East Asia, Eastern Europe & Central and South America. Cysticercus cellulose may become encysted in various bodily tissues, predominantly central nervous system and ocular tissues.

## **Material and Method:**

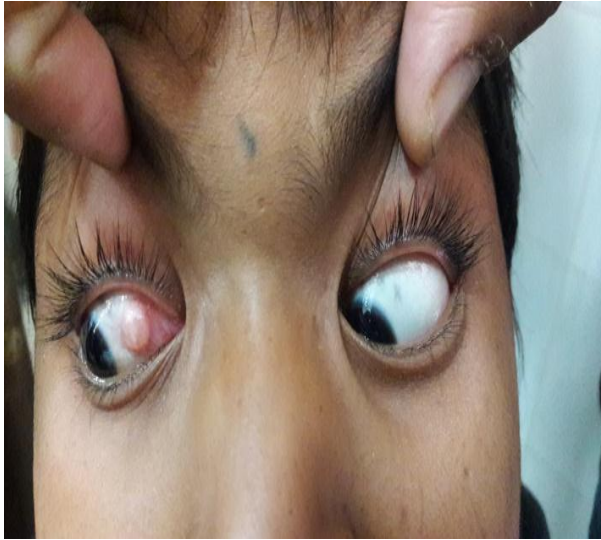The present study included total 14 patients who were diagnosed to have cysticercosis of either ocular or extraocular variety from January 2016 to January 2017 at Eye OPD PMCH, Patna. Inclusion criteria was confirmed cases of cysticercosis, diagnosed either with positive CT / MRI results showing cystic lesions or a positive histopathological examination of the Cystic lesions.

The age, gender, mode of presentation of each patients were recorded. Ophthalmic examination included visual acuity,

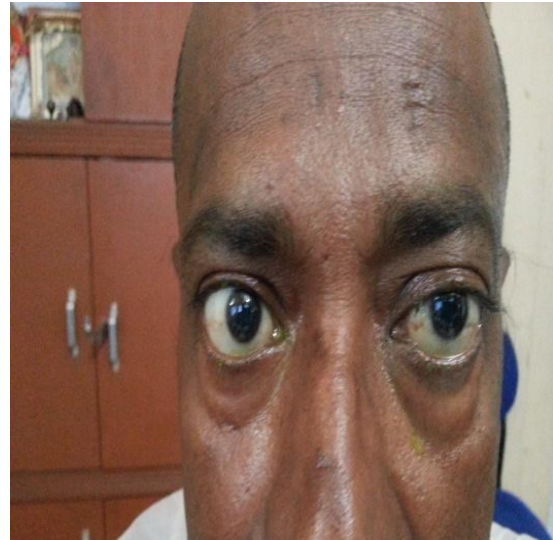
colour vision, slit lamp examination, fundus examination by Indirect ophthalmoscopy. Routine lab investigations included TLC, DLC, ESR, Stool microscopy for parasite. CT scan of brain and orbit was done in all cases & MRI in 2 cases where the CT was normal in spite of papilloedema.

Surgical excision of two cases of Subconjunctival cyst and surgical removal of three intravitreal cyst with histopathological examination was done. Two patients with optic atrophy had previously been treated with VP shunt at higher center.

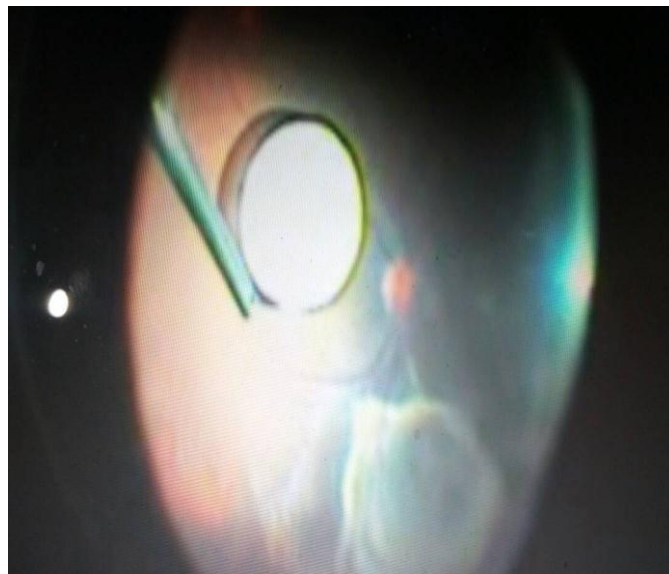
Medical treatment with Albendazole (15 mg/kg/day) in two divided doses and Prednisolone (15 mg/kg/day) as a single dose was given for three weeks. Steroid was then tapered over 2 weeks. Patients with seizure were treated initially with anticonvulsants and IV Mannitol. Anticysticercal drugs were not used in patients with intravitreal cyst.



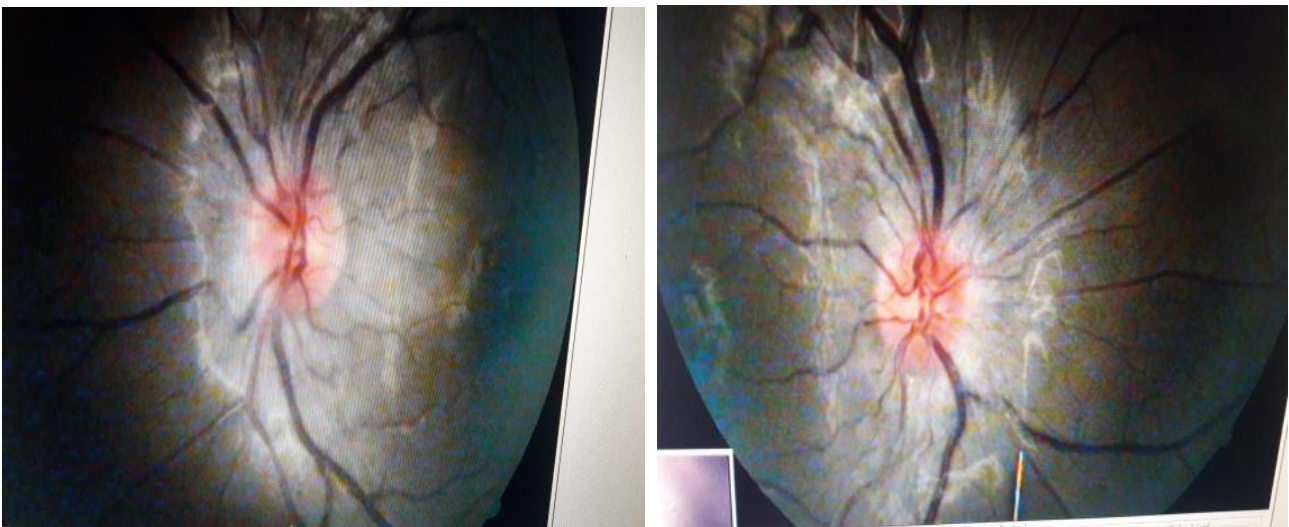
**Fig 1** Showing RE Subconjunctival Cyst.



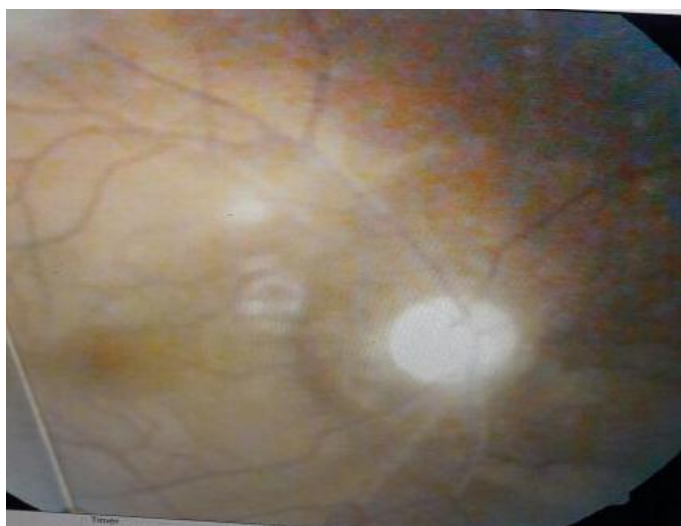
**Fig 2** showing LE Proptosis



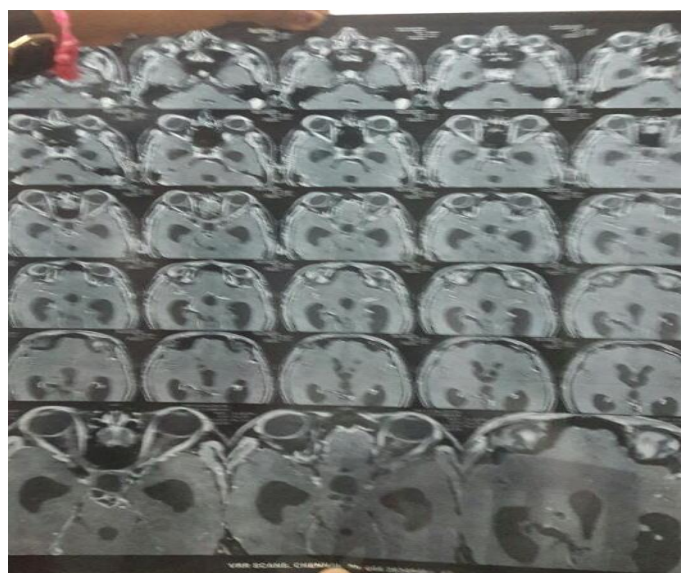**Fig 3** Showing two Intravitreal cysts, one (at top) alive and (bottom) one dead



**Fig 4:** Fundus photograph of a case of NCC Showing Bilateral Papilloedema



**Fig 5** Fundus photo of a case of NCC presenting as optic atrophy



**Fig 6** MRI showing ring enhancing lesion in suprasellar cistern with dilatation of ventricles

**Table 1** Showing Clinical Presentation of Cysticercosis

S. No	Age/Sex	Presentation	Symptoms	Signs	CT Scan	MRI
1	11/ M	Subconjunctival cyst	FB sensation, redness	Yellow translucent SC cyst	Normal	Not Done
2	12/ M	Neurocysticercosis	Seizures, Headache vomiting	Bilateral Early Pappiloedema	Positive	-----
3	11/ F	Neurocysticercosis	Seizures, Headache	Bilateral Pappiloedema	Positive	-----
4	24/ F	Intravitreal cyst	Floater, Decreased Vision	Intravitreal cyst with macular edema	Positive	-----
5	43/ M	Orbital Cysticercosis	Unilateral protrusion of LE	LE Proptosis	Positive	-----
6	16/ M	Intravitreal cyst	Decreased Vision	Two cysts, one live and 1 dead	Positive	-----
7	40/ F	Subconjunctival cyst	FB sensation , redness	Yellow translucent SC cyst	Normal	-----
8	23/ F	Neurocysticercosis	Headache	Normal fundus	Positive	-----
9	28/ F	Neurocysticercosis	Asymptomatic	Normal fundus	Positive	-----
10	26/ F	Neurocysticercosis	Decreased vision	Bilateral optic atrophy	Positive	Positive

11	30/F	Intravitreal cyst	Decreased vision	Single translucent cyst	Positive	-----
12	11 / M	Neurocysticercosis	Headache	Normal fundus	Positive	-----
13	13 / M	Neurocysticercosis	Decreased vision	Bilateral optic atrophy	Positive	-----
14	26 /F	Neurocysticercosis	Seizures, Headache Decreased vision	Bilateral optic atrophy	Positive	Positive

In the study, 6 patients were male and 8 were female. Age of the patient were in a range of 11 yrs to 45 years. Most of the patients (i.e. 64.2%) were below 25 years old.

### Result: 1

Human Cysticercosis is a parasitic infection caused by *Cysticercus cellulose*, the larval form of the cestode, *Taenia Solium*. Human acquire cysticercosis by accidental ingestion of faecally contaminated food or water that contains ova of *T. Solium*.

### Result: 2

Among eight cases of neurocysticercosis, three patients presented with seizures, headache and vomiting, two with severe headache while rest presented with marked decrease in vision. One patient who was asymptomatic was diagnosed during routine CT scan.

The patients with subconjunctival cyst, presented with F.B. sensation and redness and pain. In two patients, indirect ophthalmoscopy revealed a free floating intravitreal cyst while in one, it showed one dead and one live cyst (Fig 3.). One patient presented with unilateral (LE) proptosis. (Fig 2)

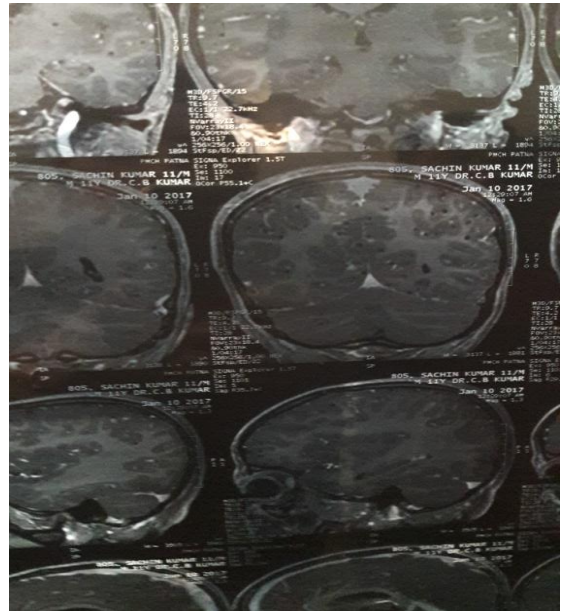
Medical treatment was effective in six cases. Patient with proptosis (case 5) showed complete resolution after 4 weeks of treatment with Albendazol and oral steroids. Treatment was also effective in two patients with NCC presenting with seizures (case 2, 3) where initial treatment was done with anticonvulsants and mannitol. CT was normal after 2 months of treatment in cases 8, 9 and 12. No improvement was seen in cases with optic atrophy ( case 10 , 13 , 14 ).

Subconjunctival cyst was excised in toto in case 1 while it ruptured during removal in case 7 and was treated with anticysticercal therapy post operatively. Histopathological examination showed cysticercus larva having invaginated scolex and hooklets and mixed inflammatory cells were seen in surrounding tissues.

Intravitreal cysts was surgically removed (in case 4, 11) and diagnosis confirmed by histopathological examination but patients did not gained vision post operatively. Two patients with optic atrophy had previously been treated with VP (Ventriculoperitoneal shunt) at higher center. Stool examination was negative in all cases. Lab investigation showed eosinophilia in only 2 cases.

CT scan of brain & orbit was done in all cases and MRI was also in two cases.

CT scan was normal in cases with subconjunctival and intravitreal cysts. CT scan showed cysts in vesicular stage in brain parenchyma in most of the cases of NCC. In 7th case with optic atrophy, MRI showed ring enhancing lesion in suprasellar cistern, in quadrigeminal plate cistern & interpenduncular subthalamic region with dilatation of third, fourth and lateral Ventricles which is rare.



**Fig 7: MRI showing cyst in vesicular stage with classical “hole with a dot appearance” indicating scolex.**

### Discussion

Schott in 1836, first demonstrated *Cysticercus cellulose* i.e. larval form of cysticercosis. Neurocysticercosis was first reported in 1888 by Armstrong, in a pt. with seizures

Neurocysticercosis is the most common manifestation of cysticercus infection, with brain parenchyma being commonest site.

Ocular cysticercosis occur in 13-46 % of the infected patients. 35% of the cysts were found in subretinal space, 22% in the vitreous, 22% in the subconjunctival space, and 5% in anterior segment and only 1% in orbit (Kruger - Leite et al).

In our study, 64.2% of patients were below 25 years old. In a study by Reddy et al, 90% of patients were less than 15

years of age. Malik et al reported 68% in the age group of 10-30 yrs. In the study 57% cases were of NCC, 14.2% of subconjunctival cyst, 21.4% of intravitreal cyst.

Neurocysticercosis remains mostly asymptomatic, MC presentation is seizures/ epilepsy (79%), severe headache (38%), focal deficit (10%), and sign of raised intracranial tension in (12%).

In our study, most common presentation of NCC was with papilloedema and optic atrophy (62.5%). Seizure was present in 37.5% cases. Subconjunctival cysticercosis presented as yellow subconjunctival, mass with congestion.

The intravitreal cysts appear as free floating translucent cyst.

CT scan shows characteristic hypodense mass with a central hyperdensity suggestive of scolex. Adjacent soft tissue inflammation is seen as ring enhancement lesion.

MRI shows cysts which appears as cystic lesion with a central dot i.e. "hole with a dot" representing scolex. In our study most of the cysts were multiple in number in vasicular stage, diffusely distributed in brain parenchyma

In one case with optic atrophy, MRI revealed ring enhancing lesion (i.e. active cyst causing inflammation) in suprasellar cistern, involving ventricles which is rare.

Besides imaging technique, histopathological demonstration of cysts with invaginated scolex and hooklets confirms the diagnosis. Positive test results from a serum Enzyme linked Immunosorbant Assay (ELISA) for anticysticercal antibodies help confirm the diagnosis where scolex is not visible; however negative test results do not exclude cysticercosis. A complete blood count may reveal eosinophilia.

Neurocysticercosis has been treated effectively with Albendazole and Praziquantel. However, Albendazole was found to be more effective and less expensive when compared with Praziquantel (Sotelo et al).

In our study, patients were treated with Albendazole and Prednisolone for 4 weeks. Anticonvulsant & mannitol were used initially for those presenting with seizures, headache & vomiting.

Intravitreal cysts and NCC associated with raised intracranial tension (Seizures, unconsciousness & vomiting) i.e. cysticercus encephalitis are contraindications for antiparasitic therapy.

Even with treatment, intraocular cysticercosis is associated with a poor prognosis.

A high index of suspicion is required for the diagnosis of ocular & Neurocysticercosis because of endemic nature of infestation in our region. CT scan, MRI, B Scan, Biopsy of lesions and ELISA for anticysticercal antibodies help to establish the diagnosis.

A combination of oral Albendazole and corticosteroid should be given in confirmed cases, after excluding intraocular cysticercosis.

## Reference

- [1] In Duke Elders S, editors, Cysticercosis, system of ophthalmology CV Masby, St. Louis, 1978 P 40.
- [2] Sekhar GC, Lemke BN, Orbital cysticercosis ophthalmology 1997.
- [3] Malike SRK, Gupta AK, Chaudhary S. Ocular Cysticercosis, Am j. Ophthalmol. 1968, 66: 1168.
- [4] Kruger – Leite, Jalkh AE, Quiroz H, Schepens CL. Intraocular, cysticercosis, AM.J. Ophthalmol 1985; 99: 252-7.
- [5] Perry HD, Font RI Cysticercosis of the Eyelid. Arch ophthalmol 1978; 96: 1255-7.
- [6] De Brutto OH, Sotelo J. Albendazole therapy for subarachnoid and ventricular Cysticercosis. J. Neurosurg. 1990; 72: 816-7.

## Conclusion