

# Clinical Profile and Pattern of Uveitis in a Tertiary Care Centre

Raji Kurumkattil MS, DNB<sup>1</sup>, Sanjay Kumar Dhar MS, DNB<sup>2</sup>, Vijay Kumar Sharma MS, DNB<sup>3</sup>, Hemant Singh Trehan, MS<sup>4</sup>, Anuradha Singh MBBS<sup>5</sup>

<sup>1</sup>Associate Professor, <sup>2</sup>Assistant Professor, <sup>3</sup>Assistant Professor, <sup>4</sup>Professor, <sup>5</sup>Resident  
Department of Ophthalmology, Army Hospital(R&R), Delhi Cantt. PIN110010



Email id - <sup>1</sup>[drrajisatyapal@yahoo.co.in](mailto:drrajisatyapal@yahoo.co.in), <sup>2</sup>[csanjaydhar@yahoo.com](mailto:csanjaydhar@yahoo.com), <sup>3</sup>[vijaysharma007@gmail.com](mailto:vijaysharma007@gmail.com),  
<sup>4</sup>[hstarti@gmail.com](mailto:hstarti@gmail.com), <sup>5</sup>[anuradha9000@gmail.com](mailto:anuradha9000@gmail.com)

\*Corresponding Author -

**Dr. Raji Kurumkattil**

Associate Professor, Department of Ophthalmology, Army Hospital(R&R), Delhi Cantt. PIN 110010.  
Email: [drrajisatyapal@yahoo.co.in](mailto:drrajisatyapal@yahoo.co.in), Ph No 09654193600

## **Abstract:**

We conducted an institutional based retrospective study on 141 uveitic patients treated at our center between Apr 2014 - Apr 2016 and analyzed the pattern of uveitis. A complete ophthalmologic examination was done in all patients. Relevant serological and radiological investigations were carried out based on clinical features to reach definitive diagnosis. Evaluations by concerned specialist were done as and when indicated. The main outcome measured included pattern of uveitis according to anatomical classification and etiology. Most patients were treated on outpatient basis. Classification of uveitis was done based on IUSG classification.<sup>[1]</sup> The final etiological diagnosis was done based on clinical features, lab investigations, and systemic evaluation. Male to female ratio was 3: 1. Mean age was 34.91. Anterior uveitis is the commonest type which constituted 80 cases (56.74%) followed by retinal vasculitis (19.15%), posterior uveitis 14 (9.93%), pan uveitis 11 (7.8%) pars planitis 6 (4.25%) and scleritis 2 (2.13%). Specific diagnosis could be made in 33 (37.5%) cases of anterior uveitis. Rest was idiopathic. Among 27 cases of vasculitis 4 were positive for tuberculosis and 1 patient was found to have sarcoidosis. Out of 141 cases, 24 (17.73%) had specific ocular disease and in 36 cases (24.82%) definite systemic association could be identified. More male preponderance is seen in our study, may be due to the clientele being the serving soldiers in the productive age group.

**Keywords:** Uveitis; vision loss; classification; clinical profile.

## **Introduction**

The spectrum of etiology of "uveitis" is very vast and it can be variable due to complexities in the etiology, geography, racial, nutritional and socio economic differences.<sup>[2]</sup> Severe visual loss due to uveitis accounts for 10% of blindness in the Western world.<sup>[3]</sup> With the advances in technologies the accurate diagnosis has become easy; even then it can be a challenge to the treating ophthalmologist. Evaluation of pattern of uveitis in a population gives an insight into the prevalence of a particular type of disease and occurrence of any new pattern of disease. Numerous studies from different part of India and world, have been reported in literature enumerating the etiology and pattern of uveitis.<sup>[4,5]</sup> We describe a retrospective study, which was carried out at our center to evaluate various etiology, clinical features and associated systemic association in patients of uveitis.

## **Material and Methods**

We conducted an institution based retrospective study on 141 uveitic patients treated at our center between Apr 2014 - Apr 2016 and analyzed the pattern of uveitis. The patients were classified into different group according to international uveitis study group (IUSG) classification.<sup>[1]</sup> A comprehensive ocular examination was performed in all patients. The examination profile was as follows: visual acuity by Snellen's chart, refraction, intraocular pressure by applanation tonometry, slit lamp biomicroscopic examination, and a detailed fundus examination. Ocular findings were analyzed in each case. Other investigations like fundus fluorescein angiography (FFA), Ultrasound AB Scan, Ultra Sound Biomicroscopy (UBM), Optical coherence tomography was carried out when required. Routine blood tests included complete blood count along with erythrocyte sedimentation, radiography of the chest,

Mantoux test and serological tests like ELISA for HIV, VDRL. Based on the clinical features, ancillary tests like Anti-nuclear antibody (ANA), HLA-B27, TORCH titre (especially in paediatric group), serum angiotensin converting enzyme (ACE), serum calcium, X Ray Sacroiliac joints, lumbar spine, and CT Chest were included in selected cases to reach a definitive diagnosis. Evaluation by concerned specialist was done whenever indicated.

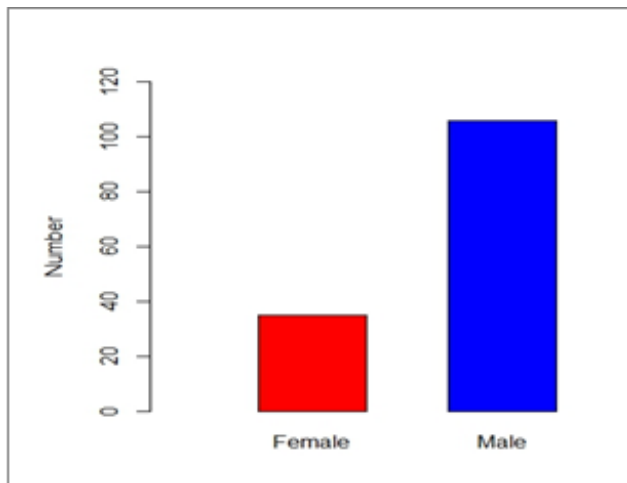


Figure 1: sex wise distribution of patients.

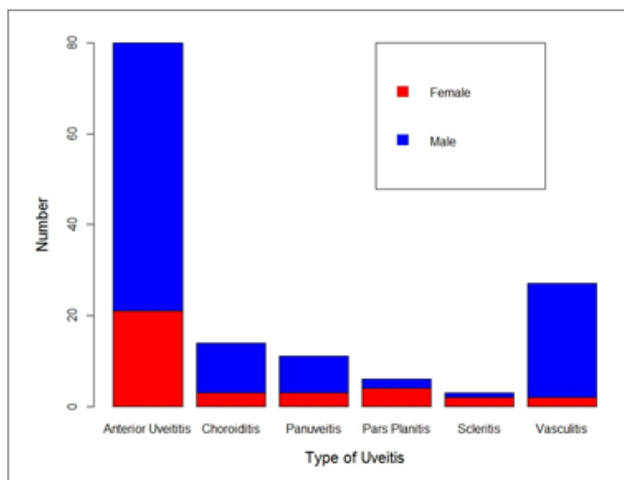


Figure 2: Bar graph depicting sex wise distribution of number of patients with different types of Uveitis

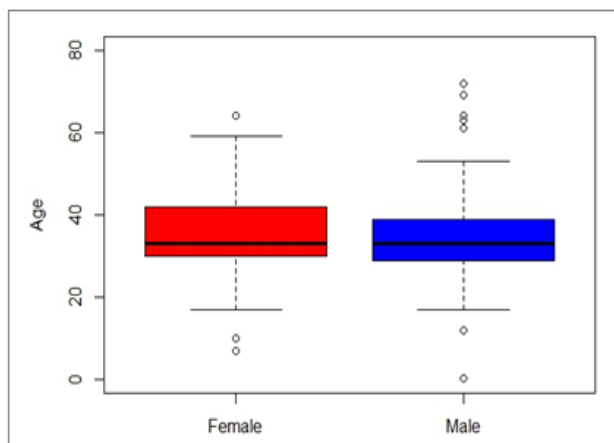


Figure 3: Age distribution

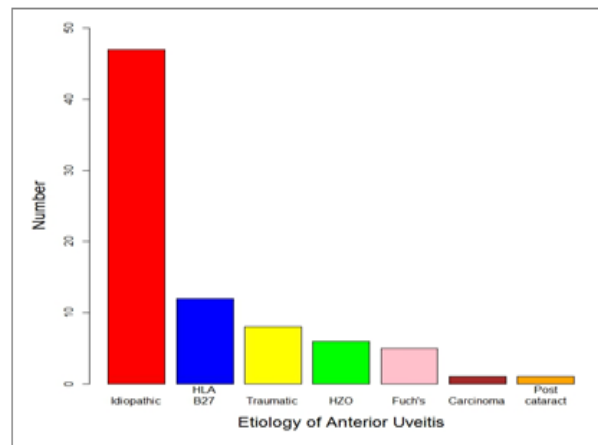


Figure 4: Bar graph showing etiology of anterior uveitis

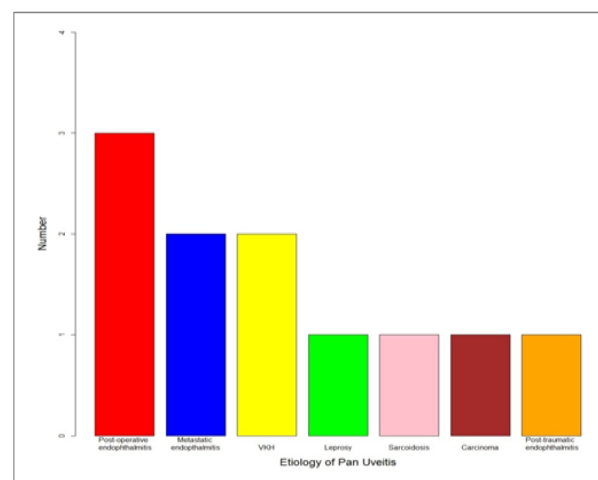


Figure 5: Graph showing etiology of Pan uveitis

## Results

In this retrospective study 141 patients were included. The purpose of the study was to identify the clinical and etiological profile of uveitis at our center. 106 were males and 35 were females. Male to female ratio was 3: 1 (figure 1 & 2). Mean age was 34.91 (figure 3). Anterior uveitis is the commonest type which constituted 80 cases (56.74%). Specific diagnosis could be made in 33 (37.5%) cases of anterior uveitis (figure 4). Commonest etiology was seronegative spondyloarthropathy (12 cases), followed by post traumatic uveitis, Herpes Zoster and Fuch's heterochromic irido cyclitis respectively. Rest was idiopathic. Retinal vasculitis (19.15%) constituted the second most cause of uveitis. Among 27 cases of vasculitis 4 were positive for tuberculosis and 1 patient was found to have sarcoidosis. 2 patients developed vasculitis following viral fever.

Among 14 cases of posterior uveitis (9.93%), idiopathic choroiditis was seen in 4 (28.7%) cases Cat scratch disease (3 cases, 21.42%), Toxoplasmosis (2 cases, 14.29%), Tuberculosis 2 cases (14.29%), Cytomegalo virus (CMV) retinitis 2 cases (14.29%), and acute posterior multifocal

placoid pigment epitheliopathy (APMPPE) constituted 1 case (7.14%).

11 patients had Pan uveitis 11 (7.8%), 6 had intermediate uveitis (4.25%) and 2 patients were detected to have scleritis (2.13%). Out of the cases of Panuveitis, one patient was suffering from Leprosy, 3 had vogt Koyanagi Harada's (VKH) disease, sarcoidosis was detected in 1 patient and 1 patient had tuberculosis. Panuveitis due to sympathetic ophthalmia was diagnosed in one case and 3 had metastatic endophthalmitis.

Out of 141 cases, 24 (17.73%) cases had specific ocular disease and in 36 cases (24.82%) definite systemic association could be identified. More male preponderance is seen in our study, may be due to the clientele being the serving soldiers in the productive age group.

### Discussion

The population attending our institute constituted a mixed ethnicity, belonging to all parts of India. More male preponderance is seen in our study (75.18%), may be due to the clientele being the serving soldiers in the productive age group. Various studies from Western countries and India also showed increase incidence of uveitis in males.<sup>[6,7]</sup> Anterior uveitis is the commonest type which constituted 80 cases (56.74%). Specific diagnosis could be made in 33 (37.5%) cases of anterior uveitis. Rest was idiopathic. The second commonest type was vasculitis (19.15%) due to various etiology. Third commonest type was the posterior uveitis (9.93%). Among the posterior uveitic group idiopathic choroiditis was the commonest subtype seen in our study. Serpiginous choroiditis is the commonest type of posterior uveitis reported by various studies from North India.<sup>[5,6]</sup> Only 01 case of CMV retinitis was seen in our study. Rathinam et al, in their study mentioned that there is a increase in the incidence of uveitis due to leprosy, tuberculosis and leptospiral uveitis.<sup>[8]</sup> In our series we could not find out the etiology for intermediate uveitis. Patients who had pan uveitis was due to endophthalmitis. vogt Koyanagi Harada's disease. Leprosy and sarcoidosis constituted a very small component of pan uveitis.

### Conclusion

This study reflects the causes and distribution of uveitis at our centre. Acute anterior uveitis of undetermined cause is the commonest cause of uveitis, followed by vasculitis. Uveitis is a vision threatening ocular disorder with numerous etiologies. It should be mandatory that a proper uveitis registry should be maintained and because in the difficulty in making precise diagnosis and complicated management, it is imperative that affected patients may be referred and closely monitored by concerned specialist to prevent irreparable ocular damage

**Financial interest:** None

**Conflicts of interest:** None

### References

- [1] Jabs DA, Nussenblatt RB, Rosenbaum JT. Standardization of uveitis nomenclature (SUN) working group. Standardization of uveitis nomenclature for reporting clinical data. Results of the first international workshop. *Am J Ophthalmol.* 140:509-16; 2005.
- [2] Nussenblatt RB. The national history of uveitis. *Int Ophthalmol.* 14: 303-308; 1990.
- [3] Weiner A, BenZ Ezra D. Clinical pattern and associated conditions in chronic uveitis. *Am J Ophthalmol.* 112: 151-158; 1991.
- [4] Gautam N, Singh R, Agarwal A, Yangzos S, Dogra M, Sharma A. Pattern of uveitis at a tertiary referral institute in North India. *Ocul Immunol Inflamm.* 1-8. Dec 2016.
- [5] Singh R, Gupta V, Gupta A. Pattern of uveitis in a referral eye clinic in north India. *Indian J of Ophthalmol.* Jun; 52(2):121-5; 2004.
- [6] Venkatesh P, Gogia V, Shah B, Gupta S, Sagar P, Garg S. Pattern of uveitis at the apex institute for eye care in India: Result from a prospectively enrolled patient data base (2011-2013). *Int Ophthalmol.* 36(3):365-75, 2016.
- [7] Semology and classification of uveitis. *Brezin AP Rev Prat.* 49(18):1982-8, 1999.
- [8] Rathinam SR, Namperumalsamy P. Global variation and pattern changes in epidemiology of uveitis. *Indian J Ophthalmol;* 55:173-83, 2007.