

# Angiolymphoid Hyperplasia with Eosinophilia Developing in a 9 Year Old Patient with History of Tuberculosis

Amrit Kaur Kaler,<sup>\*1</sup> Naveen Kumar BJ<sup>2</sup>

<sup>\*1</sup>Associate Professor, Department of Pathology;

<sup>2</sup>Professor and HOD, Department of Pathology;

The Oxford Medical College, Hospital and Research Centre, Bangalore, Karnataka



## **Abstract**

*Angiolymphoid hyperplasia with eosinophilia (ALHE) is a rare benign reactive vasoproliferative disease, presenting as painless vascular papules or nodules in the dermal and subcutaneous tissue particularly in the head and neck region. The etiology is uncertain whether; reactive or neoplastic; but its association with Tuberculosis is rare and very few cases have been reported so far. We present a nine year old girl with a swelling on the dorsum of foot since 3 months. She reported to have taken treatment for Tuberculosis when she was six years. Excisional biopsy showed vascular proliferation with prominent mixed inflammatory component, diagnosed as ALHE based on histopathological and Immunohistochemical methods. Its association in the present case showed possibly a result of complex immunological mechanism secondary to chronic infection like tuberculosis.*

*We present a case of ALHE with a very rare presentation on the dorsum of the foot in a 9 year old female with a history of Tuberculosis.*

**Keywords:** *Angiolymphoid hyperplasia with eosinophilia • Tuberculosis • Vasoproliferative lesion.*

## **Introduction**

Angiolymphoid Hyperplasia with eosinophilia (ALHE) is a vasocentric process involving the muscular arteries of head and neck, characterized by infiltrates of lymphocytes and eosinophils.<sup>[1]</sup> ALHE clinically presents as a single to multiple red dome shaped papules or sub cutaneous nodules. It is rarely seen in trunk, extremities and genitalia.<sup>[2]</sup> ALHE is most commonly seen in young to middle aged females, rarely in children.<sup>[3]</sup> About one fifth of the patients have peripheral blood eosinophilia and lymphadenopathy.<sup>[4]</sup>

The aetiology of ALHE is still unclear; vascular or lymphoproliferative; or heterogeneous group of entities. Some authors have proposed hypersensitivity reaction or a tissue reaction to a previous trauma as seen in cases of acquired traumatic A-V fistula.<sup>[5]</sup> There has been a case report of an ALHE in a patient of peripheral T cell Lymphoma.<sup>[1]</sup> The association of ALHE with tuberculosis is very rare and the purpose of this case report is to define the possible association of immune derangement in a case of Tuberculosis with ALHE.

## **Case report**

A nine year old female attended our outpatient department with complain of swelling on dorsum of foot since 90 days with no history of fever, pain or trauma. Patient gave a history of tuberculosis 3 years back and has taken treatment for the same for a period of six months. Based on the clinical presentation, a clinical diagnosis of pyogenic granuloma was made. Peripheral blood showed 18% eosinophilia. Complete surgical excision of the mass was performed under local anaesthesia and the mass was sent for histopathological examination. The tumour measured 2.5x2x1cm, firm in consistency with no ulceration. Cut surface showed a well circumscribed solid gray white nodule with minute foci of haemorrhage. Microscopy revealed lobular proliferation of thick and thin walled blood vessels lined by plump endothelial cells separated by fibrocollagenous stroma. (Fig 1) The inflammatory component is composed of a diffuse infiltrate predominantly of eosinophils, lymphocytes and plasma cells. (Fig 2) Immunohistochemical studies showed CD34 positivity for vascular endothelial cells. (Fig 3 & 4) Based on clinical, histopathological and immunohistochemistry, a diagnosis of Angiolymphoid Hyperplasia with eosinophilia (ALHE) was made.

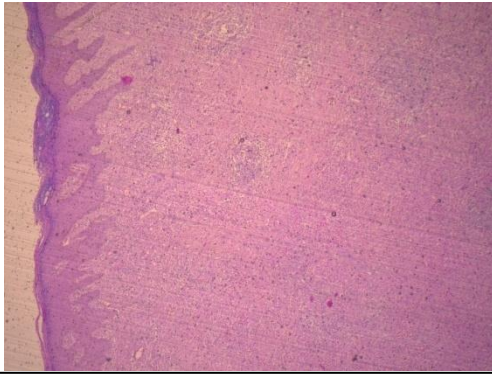


Fig 1: Low Power: Lobular proliferation of blood vessels with acanthotic epidermis

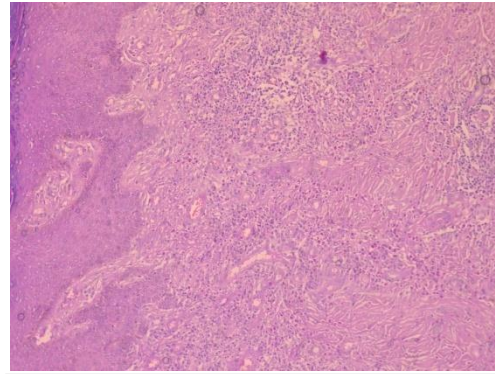


Fig 2: High Power: Mixed Inflammatory infiltrate amongst vascular proliferation

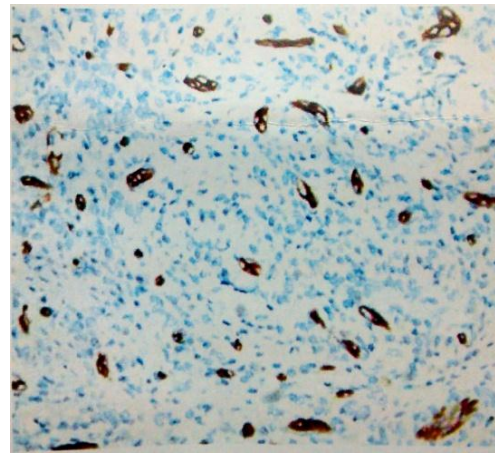
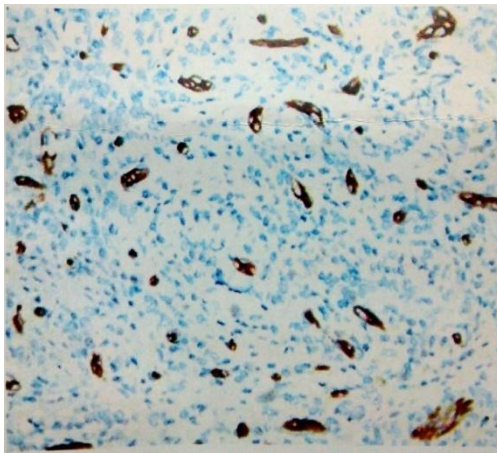


Fig 3 & 4: CD34 positivity for vascular component

## Discussion

ALHE also known as epithelioid hemangioma, and histiocytoid hemangioma, was first described by Wells and Whimster in 1969.<sup>[6]</sup> Wilson - Jones and Bleeher also described the entity under the name inflammatory angiomatous nodule with abnormal blood vessels in scalp and ears-pseudo or atypical pyogenic granuloma in the same year. ??

Angiolymphoid hyperplasia with eosinophilia is seen more commonly in young to middle aged women between the age of 20 and 50 years.<sup>[3]</sup> The present case in this study presented in a pediatric age group a 9 year old girl which makes it even rarer. ALHE is usually seen as a solitary, but multiple ones are reported in 20% cases. Majority of the studies described these lesions located in the head and neck and rare locations in the trunk and extremities.<sup>[2]</sup> Rare extra cutaneous involvement has also been reported in nasal mucosa, muscle, bone and salivary glands.<sup>[8]</sup> The present case has a very rare presentation of a solitary lesion on dorsum of the foot which has not been reported in the literature till now. The presenting feature may be nonspecific, can lead to the delay in diagnosing. In this case, the swelling was not noticed by the patient since long, since it was on the dorsum of foot.

Hyper-eosinophilia is inconstant (21%) and is not required for the diagnosis.<sup>[4]</sup> The present case also showed increased eosinophils (16%) on peripheral smear examination.

The etiology of ALHE is unknown, some authors consider ALHE as a neoplasm arising from endothelial cells, and other suggests it is secondary to an inflammatory reaction to complex immunological mechanisms. Trauma, hormonal changes and infections (Human T-cell lymphotropic virus (HTLV) or Human Herpesvirus 8 (HHV-8)) and environmental factors such as insect bite, trauma, and infections have been suggested to play a role in the pathogenesis.<sup>[9]</sup> Associations of ALHE with nephrotic syndrome and pregnancy have been described.<sup>[10]</sup> Interleukin 5 and vascular endothelial growth factors were also found to be increased in some cases.<sup>[10]</sup> In the present case, the patient had a past history of tuberculosis and is possibly a result of complex immunological mechanism secondary to chronic infection.

The histopathological differential diagnosis includes Kimura's disease, insect bites, granuloma pyogenicum, epithelioid hemangioendothelioma and angiosarcoma of face and scalp. ALHE and KD share many histopathological characteristics; but can be differentiated as ALHE is characterized by dilated and bizarre shaped blood vessels with prominent endothelial cells showing vacuolation in the

cytoplasm. The vessels are surrounded by ring of fibroplasia. Lymphoid follicles are seen only in 10% of cases. In contrast, KD is a subcutaneous lesion, characterized by diffuse and nodular inflammatory infiltrate containing lymphoid follicles; are absolutely necessary for the diagnosis. Eosinophils are seen in both the lesions but are more abundant in KD. Clinically, important differences include large diameter of the lesion, longer time of evolution and the erythematous and purpuric colour favours ALHE, reflecting the vascular nature of the disease.<sup>[11]</sup> Epithelioid hemangioendothelioma shows vessels myxoid or sclerotic stroma. The tumor did not show nuclear abnormality and abnormal mitosis of the endothelial cells which ruled malignancies like angiosarcoma.

Immunohistochemical study shows endothelial cells positive for CD 31, CD 34 and vWF.<sup>[4]</sup> CD 34 is positive in this case, which confirmed the dilemma in diagnosis; because of the rare presentation on the dorsum of the foot. In the absence of treatment, lesions may increase or decrease spontaneously. Re-occurrence after incomplete excision is observed in 30% of cases. No metastatic cases have been reported. Considering the possible involution of the lesions, a simple follow up for 3 to 6 months is recommended. Many therapeutic procedures include electro-dessication, cryotherapy, and systemic corticoid treatment, intra lesional injections of sclerosing products, phototherapy or alpha 2a interferon.<sup>[11]</sup>

## Conclusion

ALHE is a low grade inflammatory vascular neoplasm secondary to complex immunological mechanism in response to various stimuli. It is a rare affliction with a challenging diagnosis due to its association with wide range of conditions from infective to malignant. But its association with Tuberculosis needs to be studied and investigated further.

## References

- [1] Lous F Gonzalez-Cuyar, Fabio Tavora, X Frank Zhao et al. Angiolymphoid hyperplasia with eosinophilia developing in a patient with history of T cell Lymphoma: evidence of multicentric T cell lymphoproliferative lesion. *Diagnostic Cytopathology* 2008; 3:22.
- [2] Botet MV, Sanchez JL. Angiolymphoid hyperplasia with eosinophilia: report of a case and review of the literature. *J Dermatol Surg Oncol* 1978, 4(12): 931-36.
- [3] El Sayed F, Dhaybi R, Ammoury A, Chababi M: Angiolymphoid hyperplasia with eosinophilia: efficacy of isotretinoin? *Head Face Med* 2006; 2:32-36.

- [4] Olsen TG, Helwig EB. Angiolymphoid hyperplasia with eosinophilia. A clinicopathologic study of 116 patients. *J Am Acad Dermatol* 1985; 12 (5 Pt 1): 781 - 96.
- [5] Aoki M, Kimura Y, Kusunoki T, Tahara S, Kawanah S. Angiolymphoid hyperplasia with eosinophilia associated with anomalous dilation of occipital artery: IL-5 and VEGF expression of lesional mast cells. *Arch Dermatol* 2002; 138:982-4.
- [6] Wells GC, Whimster IW. Subcutaneous angiolymphoid hyperplasia with eosinophilia. *Br J Dermatol* 1969; 81:1-14.
- [7] Endo M, Shibata M, Iwamoto I, Suzuki H, Hayakawa M: Angiolymphoid hyperplasia with eosinophilia. *Eur J Dermatol* 1998; 8:175-177.
- [8] Hollo P, Marschalko M, Sikos G, Harsing J, Horvath A. Angiolymphoid hyperplasia with eosinophilia in pregnancy. *J Eur Acad Dermatol Venereol* 2005; 19:645-6.
- [9] Azizzadeh M, Namazi MR, Dastghaib L, Sari-Aslani F. Angiolymphoid hyperplasia with eosinophilia and nephritic syndrome. *Int J Dermatol* 2005; 44:242-4.
- [10] Calonje E, Fletcher CD. Tumors of Blood Vessels and Lymphatics. In: Fletcher CD, editor. *Diagnostic Histopathology of Tumors*. 2. Vol. 1. London, Hartcourt Publishers Limited; 2000. pp. 55-56.
- [11] Isohisa T, Masuda K, Nakai N, Takenaka H, Katoh N: Angiolymphoid hyperplasia with eosinophilia treated successfully with imiquimod. *Int J Dermatol* 2014; 53:e43-e44.