

# Intravitreal Triamcinolone Acetonide in Treatment of Macular Edema Associated with Branch Retinal Venous Occlusion

Priyanka, Shekhar Chaudhry, U. P. Sinha, Deepak Mishra



## **Abstract:**

**Purpose:** - To study safety and efficacy of Intravitreal Triamcinolone acetonide as treatment of macular edema in cases of Branch retinal venous occlusion.

**Material & Method:** - In a prospective study, 14 patients with BRVO with persistent macular edema were treated with intravitreal triamcinolone (4 mg) for macular edema. Snellen's visual acuity, intraocular Pressure (IOP), measurement of central macular thickness by OCT and frequency of complications were studied during follow up at 1 month and 3 months.

**Results:** - In the present study, the median age of 14 patients was 48.5 yrs and median duration of symptoms before injection was 3 months. Mean baseline visual acuity was  $0.10 \pm 0.04$  in affected eye. Mean visual acuity at 1 month follow up was  $0.55 \pm 0.17$  and at 6 months was  $0.48 \pm 5.11$  (n=8) in the affected eye. All patients except completed the 1 month examination while only 8 patient followed up to 3 months. The eyes with BRVO demonstrated a significant improvement in mean foveal thickness (Central macular thickness) Mean baseline foveal thickness as measured by OCT was  $371 \pm 80.75$  (n=14). At one month follow up, the mean foveal thickness was  $227.2 \pm 44.4$ , and at three months the thickness was  $243.75 \pm 29.46$  (n=8).

Two patients developed recurrences of macular edema, hence second injection of triamcinolone was given. Two patients developed early Posterior sub capsular cataract but surgery was not needed during the study period.

One patient developed raised IOP for which was controlled by aqueous suppressants. Six patients lost follow-up at 3 months. No patients developed serious complication like Retinal detachment, or endophthalmitis.

**Conclusion:** - Intravitreal injection of triamcinolone acetonide may be effective in treatment of patients with persistent macular edema in BRVO. However, the significant effect may persist for one month and retreatment may be necessary in few patients. In this study, severe complications were not noted.

**Keywords:** Intra vitreal Triamcinolone, macular edema. Intraocular Pressure (IOP), Central macular thickness (CMT).

## **Introduction**

Branch retinal vascular occlusion is a common retinal vascular disorder. Although visual prognosis is good, macular edema can be a cause of significant visual morbidity (Gutman & Zegarra 1974). Macular edema is found in 58-100% cases and persisted in two out of three cases (Gutman & Zegarra 1974, Michles & Gaes 1974 & Green et al 1980).

Macular edema occurs due to increase in capillary permeability due to breakdown of blood-retinal barrier, possibly mediated in part by vascular endothelial growth factor (VEGF), a 45 K Da glycoprotein.

In the Branch retinal vein occlusion (BRVO) study eyes that received grid laser treatment were found to be more likely to

improve in vision, than untreated eyes but many cases of macular edema in BRVO do not respond to laser photocoagulation and there is no treatment for macular edema in BRVO with foveal capillary non-perfusion.

Corticosteroids, a class of substance with anti-inflammatory properties have been demonstrated to inhibit the expression of VEGF gene. Additionally, corticosteroids have been demonstrated to abolish the induction of VEGF by the proinflammatory mediators, platelet derived growth factor and platelet-activating factors in a time and dose dependent manner.

Triamcinolone acetonide, a long acting corticoid derivative, hence reduces the permeability of endothelial cells & stabilizes the blood retinal barriers (Jonas et al 2005).

In this study, the safety and efficacy of triamcinolone acetonide was evaluated in patients with macular edema due to BRVO.

### Material & methods

Informed consent for all patients were taken. Inclusion criteria was patient with vascular tortuosity, retinal hemorrhage (blot & flame shaped), cotton wool spots and persistent macular edema in BRVO with BCVA  $\leq$  0.25 decimal. Patients with glaucoma, steroid responders and patients not willing to follow-up were excluded.

In all patients clinical examination including snellen's visual acuity, intraocular pressure (IOP) measurement, fundus photography, angiography and OCT (Topcon) was done first at baseline and then 1 month and 3 month after injection.

### Surgical technique

Topical 0.5% proparacaine hydrochloride was applied in affected eye. After painting the eyelids and conjunctiva with

5% Iodine & draping the eye, eye speculum was used. With 30 G needle, 0.1 ml of triamcinolone acetonide was injected slowly through inferior pars plana ie 4 mm from limbus in phaic eye and 3.5mm in pseudophakic eye. Post injection antibiotic steroid drop was used for 3 weeks.

Post injection, patient were followed up at 1 week, 1 month & 3 months period. At 1 week visit IOP was recorded and at 1 month and 3 month follow-up, BCVA, IOP and OCT was done. Patients were also assessed for any adverse effects (Endophthalmitis, Retinal detachment, cataract, raised IOP).

### Statistical Analysis

BCVA noted, was converted into decimals for analyses. BCVA and central macular thickness at baseline and follow up were summarized using mean  $\pm$  SD changes from baseline to follow-up and statistical significance of these findings were evaluated using Paired - t test.

**Table 1: Showing visual acuity at baseline, 1 month, and 3 month follow up (Snellens visual Acuity converted to decimal for analysis)**

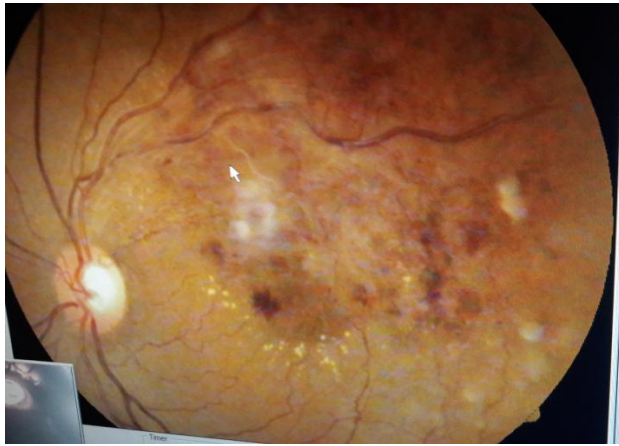
Serial NO	Age	Sex	Diagnosis	BCVA Baseline	BCVA at 1 Month	BCVA at 3 Month
1	52	M	RE IT BRVO	0.1	0.63	0.5
2	45	M	LE Macular BRVO	0.16	0.63	0.63
3	46	F	RE IT BRVO	0.04	0.63	0.5
4	50	F	RE ST BRVO	0.06	0.5	-----
5	42	F	LE IT BRVO	0.1	1.0	-----
6	48	M	RE ST BRVO	0.06	0.5	-----
7	49	M	RE ST BRVO	0.16	0.63	0.5
8	58	M	LE IT BRVO	0.1	0.32	-----
9	56	M	LE Macular BRVO	0.16	0.6	0.32
10	48	F	RE IT BRVO	0.08	0.5	0.63
11	46	M	RE ST BRVO	0.2	0.6	0.5
12	54	M	LE IT BRVO	0.06	0.32	-----
13	62	F	LE Macular BRVO	0.16	0.5	0.32
14	40	M	RE ST BRVO	0.08	0.32	-----

IT (Infero temporal), ST (Supero temporal), RE (right eye), LE (Left eye)

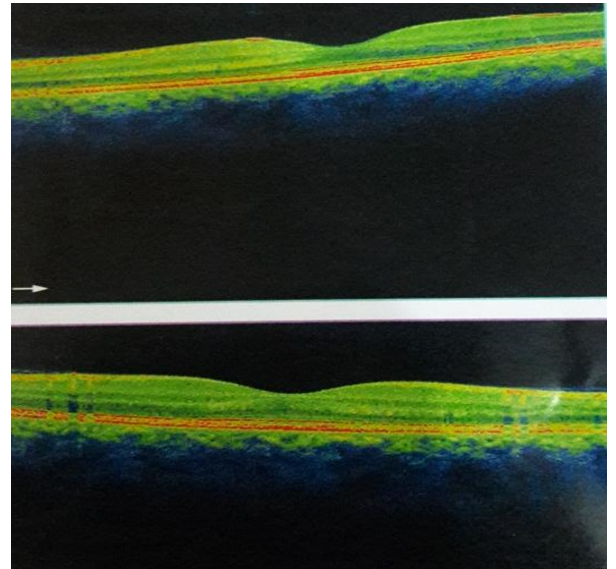
**Table 2: Showing IOP (Intraocular pressure) And CMT (Central macular thickness) at Baseline, 1 month and 3 month follow-up**

Serial No	Baseline IOP	IOP 1 week	IOP at 1 month	IOP at 3 month	CMT Baseline	CMT 1 month	CMT at 3 month
1	12	14	14	16	305	212	298
2	16	17	16	15	570	230	220
3	18	16	14	12	398	210	240
4	14	12	13	-----	300	200	----
5	16	14	14	-----	398	230	-----
6	19	18	16	-----	380	220	-----
7	16	15	14	15	345	226	256
8	14	16	12	-----	401	276	-----

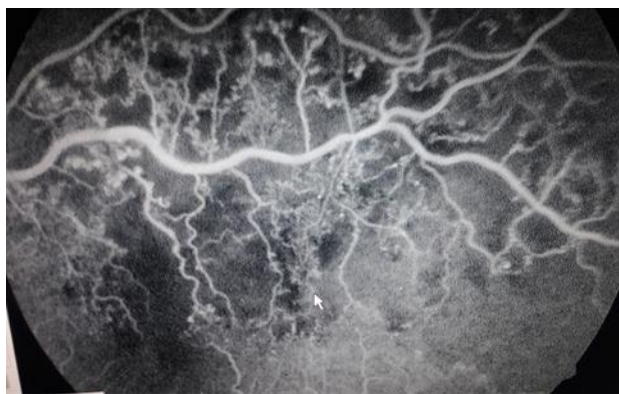9	12	14	14	16	301	198	240
10	18	16	15	18	305	204	196
11	14	12	12	14	318	212	246
12	20	26	21	-----	425	210	-----
13	16	14	14	12	280	214	254
14	14	18	17	-----	468	240	-----



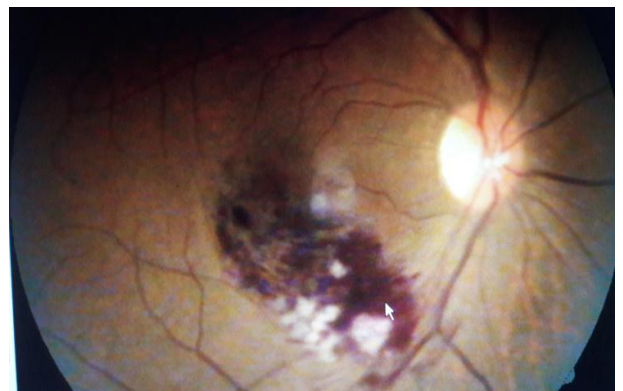**Fig 1: Fundus photograph of ST BRVO with Macular edema**



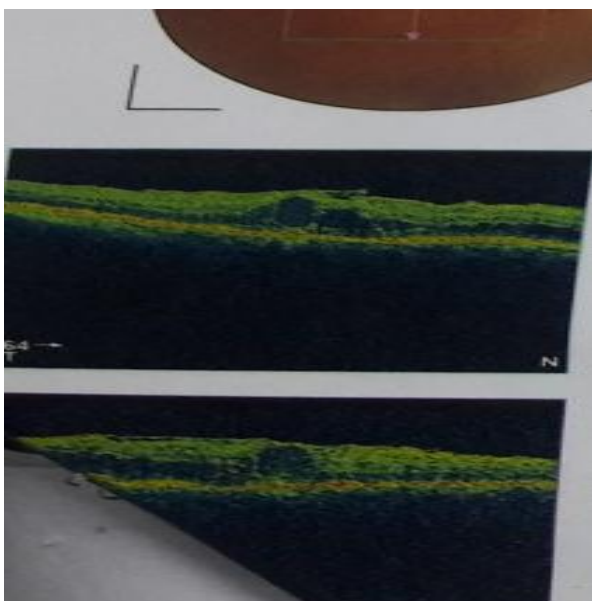
**Fig 4: OCT showing resolution of macular edema -1 month post injection**



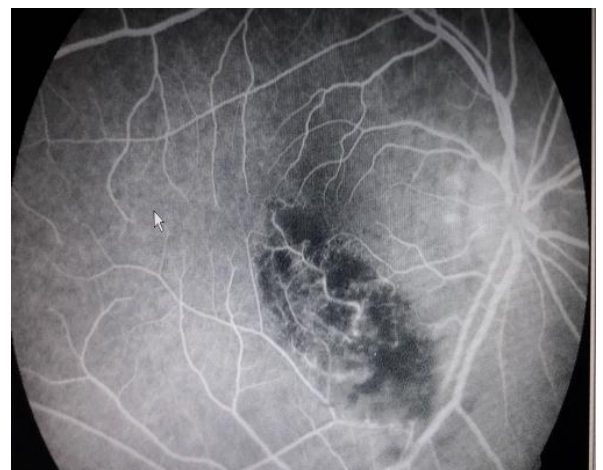**Fig 2: FFA showing BRVO with good macular perfusion**



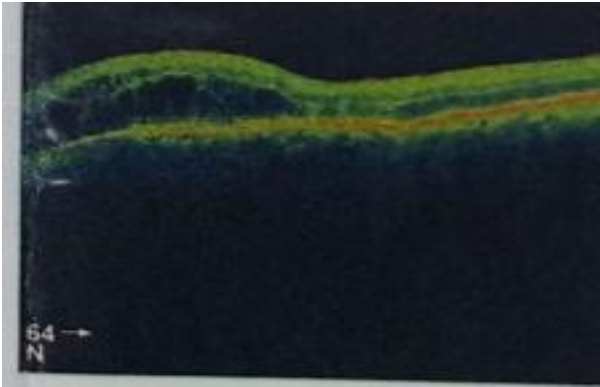
**Fig 5: Showing fundus photograph of Macular BRVO**



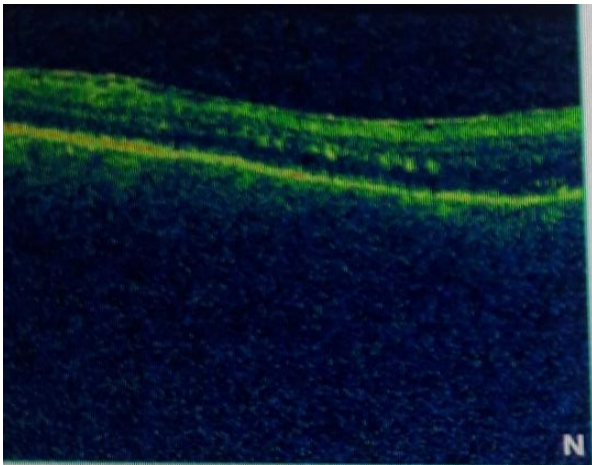
**Fig 3: OCT showing cystoid macular Edema (Before intravitreal injection of TA)**



**Fig 6: FFA showing blocked hypofluorescence due to masking by blood and cotton wool spots**



**Fig 7: OCT image of macular edema Preinjection**



**Fig 8: OCT image after 1 month of IVTA.**

## Result

Fourteen patients with BRVO with macular edema were included in this study done between January 2016 to February 2017. The median age of the patients was 48.5 yrs. The mean duration since diagnosis and treatment was 8 weeks. There were nine male and five females' patients in the group. Right eye was involved in 8 cases and left eye in 6 cases in the study. Six patients were phakic and eight patient were pseudophakic. Eleven patients with major BRVO and three with macular BRVO.

All patients completed follow up at 1 week, 1 month while six patients lost follow up at 3 months.

In two patients macular edema increased after 1 month and received second injection.

Mean BCVA was  $1.10 \pm 0.04$  at baseline,  $0.55 \pm 0.17$  at 1 month. ( $P = < 0.0001$ ), and  $0.48 \pm 0.11$  ( $N=8$ ) at three months. ( $P = < 0.0001$ ). Hence, there was a significant improvement in visual accuty of these patients. Mean IOP was  $15.5 \pm 3.22$  at baseline,  $17.5 \pm 3.37$  at 1 month ( $P = 0.120$ ) and at 3 months it was  $15.37 \pm 2.32$  ( $P = 0.921$ ). This difference was not statistically significant.

Mean macular thickness was  $371 \pm 80.75$  before treatment,  $215.2 \pm 44.49$  at 1 month ( $P = < 0.0001$ ), and  $254 \pm 29.46$ .

( $n=8$ ) at 3 months ( $P = < 0.0009$ ). By conventional criteria this was considered to be extremely significant. One eye developed raised IOP at 4 week examination and was treated with aqueous suppressants. Two patients developed early posterior subcapsular cataract. No eye needed cataract surgery during the study. No serious side effect, such as endophthalmitis or retinal detachment was seen during the study.

## Discussion

In our study, intravitreal triamcinolone injection showed significant visual improvement in patients with macular edema in BRVO. Intravitreal TA injection has been studied in various ocular pathologies including diabetic macular edema. (Martidis et al. 2004; Jonal et al 2003; Krepler et al 2004; Massin et al 2004) and macular edema due to CRVO or BVO (Greenberg et al. 2002; Jonal et al 2002; Degenring et al 2003; Park et al 2003; Chen et al 2004; Jonas et al 2005; Krepler et al 2005) in which reduction of macular edema could be observed.

Two case reports of intravitreal TA in patients with macular edema due to BRVO have been published (Degenrin et al 2003; Chen et al 2004) both of these describe a favorable outcome with resolution of macular edema and visual improvement observed 3 months and 5 weeks after treatment respectively.

In our study, the gain in visual acuity as well as reduction in macular edema was significant statistically, but a correlation between change in macular thicknss and VA was not statistically evaluated due to small sample.

The most common side effect after intravitreal injection of triamcinolone is an IOP rise. In our study one patient (7.14%) developed IOP  $> 22$  mg. However, in other studies, rise in IOP was reported to in 25-36% of cases (Challa et al 1998).

The occurrence of posterior subcapsular cataract is a known complication of topical or system steroid and has been described in 10-57% of patient after triamcinolone injection (Challa et al 1998). Our follow up was short, although early posterior sub-capsular cataract was seen in two patients (14.2%).

Intraocular infections is a major risk of every intraocular injection & has been observed after triamcinolone injection (Moshfegi et al 2003; Nelson et al 2003).

In our study, the major limitation is the small number of cases and short follow up. However, this study revealed a positive effect of intravitreal triamcinolone injection in patients with macular edema after BRVO which was statistically significant.

## Conclusion

Intravitreal injection of triamcinolone may be an effective treatment for patients with macular edema in BRVO. Further investigation is needed to balance the risk (like retinal detachment, vitreous hemorrhage, RD) of this treatment modality against the potential benefit.

## Reference

- [1] BRVO study group (1984) Argon laser photocoagulation for macular edema in branch vein occlusion.
- [2] Michel RG & Gass JDM (1974): The natural course of retinal branch vein obstruction. *Trans Am Acad ophthalmol Otolaryngol* 78: 166-177.
- [3] Krepler K, wagner J, sack S & wedrich A (2004); the effect of intravitreal triamcinolone on diabetic macular edema. *Graefes Arch Ophthalmol*.
- [4] Roth DB, Chich J, Sporn MJ, Green SN, Yarian DL & Chaudhary (2003); Non-infectious endophthalmitis associated with intravitreal triamcinolone injection. *Arch ophthalmol* 121:1279-1282.
- [5] Schindler RH, Chandler D, Thresher R, Machemer The clearance of intravitreal triamcinolone acetonide. *Am J. Ophthalmol* 1982; 93:415-417.
- [6] Martidis A, Duker JS, Greenberg PB, et al. Intravitreal triamcinolone for refractory diabetic macular edema. *Ophthalmology* 2002; 109:920-927.
- [7] Clemett RS, Kohner EM & Hamilton AM (1973) the visual prognosis in retinal branch vein occlusion. *Trans AM soc UK* 93:53-535.