

A Study of Nutrient Foramina of Humerus at Chhattisgarh State

Dr. Bhavana Khandve¹, Dr. Amrish Verma^{*2}

¹Assistant Professor, Department of Anatomy Chandulal Chandrakar Memorial Medical College Durg

²Associate Professor, Department of Orthopedics Chandulal Chandrakar Memorial Medical College Durg



*Corresponding Author

Dr. Amrish Verma

Associate Professor, Dept. of Orthopedics

Chandulal Chandrakar Memorial Medical College Kachandur, Durg.

Introduction

Nutrient foramen is an opening in the bone shaft which allows passage to the blood vessels of the modularly cavity of a bone for its nourishment and growth.^[1] The nutrient artery enters individual bones obliquely through a nutrient foramen.^[2] The nutrient artery is the principal source of blood supply to a long bone and nutrient foramen is an opening in the bone shaft which gives passage to the particularly important during its active growth period in the embryo and fetus, as well as during the early phase of ossification.^[3] Nutrient foramen are directed towards elbow in upper limb (directed towards lower end of humerus and upper ends of radius and ulna), while in lower limb nutrient foramen is directed away from knee (that is, upper end for femur and lower ends of tibia and fibula). This is said to be due to one end of limb bones growing faster than the other and generally follows the rule, "to the elbow I go, from the knee I flee." Their positions in mammalian bones are variable and may alter during the growth phase. The topographical knowledge of these nutrient foramina is useful in operative procedures to preserve the circulation^[4-6] Nutrient artery is the major source of blood supply to bone and it plays an important role in healing of fracture, Orthopedic surgical procedures like vascularized bone microsurgery requires the detailed knowledge of the blood supply. In vascular bone grafting, the blood supply by nutrient artery is extremely important and must be preserved in order to promote fracture healing.^[7] Humphrey was working on the direction and obliquity of nutrient canals postulated periosteal slipping theory, the canal finally directed away from the growing end.^[8] Fracture healing or

hematogenic osteomyelitis is closely related to the vascular system of the bone.^[9] Study of nutrient foramina in upper limb is very important for morphological, clinical, and pathological point of view. Detailed data on the blood supply to the long bones is invariably crucial in the development of new transplantation and resection techniques in orthopedics.^[10] Humerus is the largest and longest bone of the upper limb. It is supplied by nutrient artery which is a branch of brachial artery. The nutrient artery enters the bone through nutrient foramen located on antero-medial surface a little below its midpoint which is directed downwards and opens close to the medial border.^[11]

Materials & Methods

The study was conducted on 80 humeral collected from Anatomy Department of CMMC Durg, Chhattisgarh state. Damaged bones and pathologically deformed bones were excluded from the study. Length of each humerus bone was measured with the help of osteometric board. Bones were divided into three zones; Zone I – upper 1/3rd, Zone II – Middle 1/3rd and Zone III – lower 1/3rd. With the help of hand lens bones were observed for the number, direction and location of nutrient foramen with respect to the surface and borders. Among 80 bones studied, 40 were left sided and 40 were right sided. The prior permission was taken from institutional ethical committee of CMMC DURG.

Objectives: Objectives of present study is to determine number direction and location of nutrient foramen of humerus.

Result

Table1: Number of nutrient foramina on humerus

No. of nutrient foramina	Right		Left		Both %
	Number	Percentage	Number	Percentage	Percentage
1	32	58	45	75	70
2	22	40	10	16.6	29
Absent	1	2	-	-	3

The percentage of the bones having one nutrient foramen is 70% and two foramina are 29%. Among the bones studied

there was no dominant foramen in two bones

Table2: Location of nutrient foamen on humerus

Location of nutrient foramina	Right		Left		Both (%)	
	Number	Percentage	Number	Percentage	Number	Percentage
Medial border	42	38	36	33	78	71
Antero medial surface	20	18	30	27.2	44	40
Lateral border	5	5			5	5
Anterior border	1	1	2	2	3	3
Posterior surface			4	4	4	4

Among the bones studied there was no dominant foramen in two bones. About 57% of humerus bones have nutrient foramen located on the medial border. Next in the order are

Anteromedial surface (43%), anterior border (4%). Lateral border (5%), Posterior surface (3%).

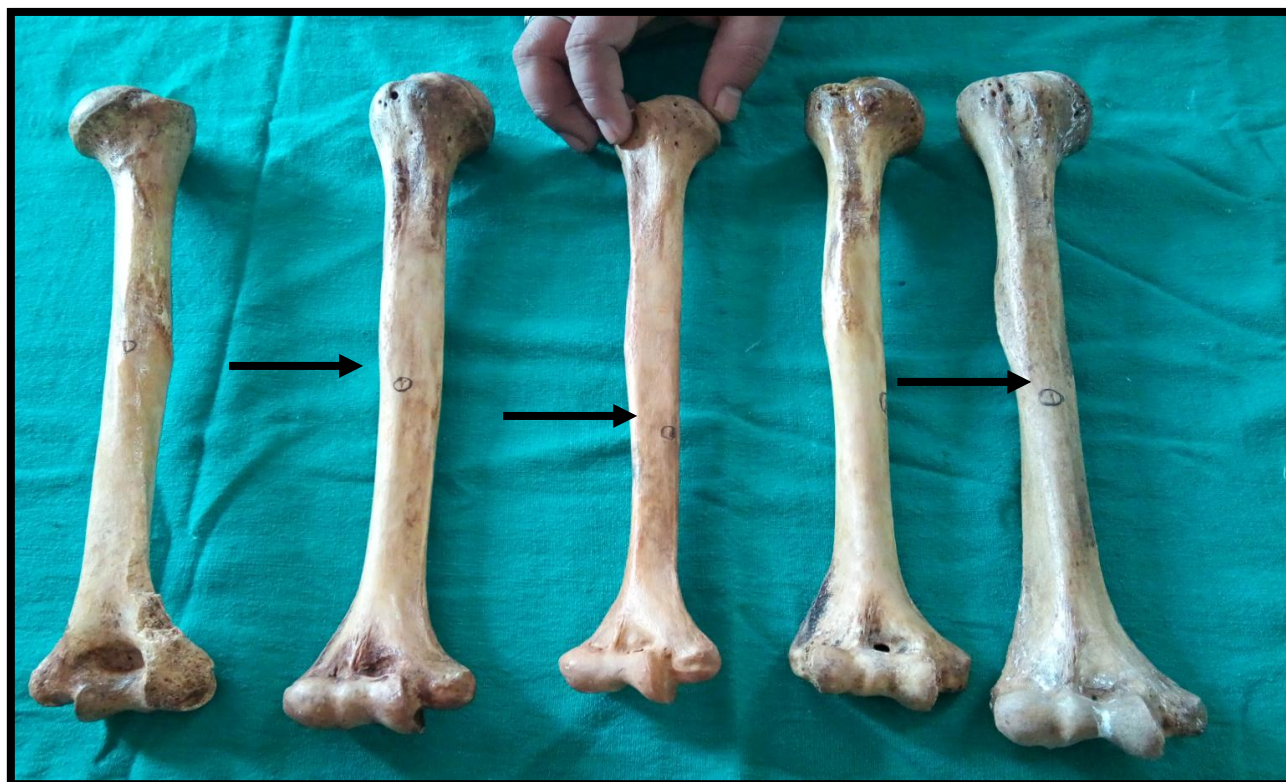


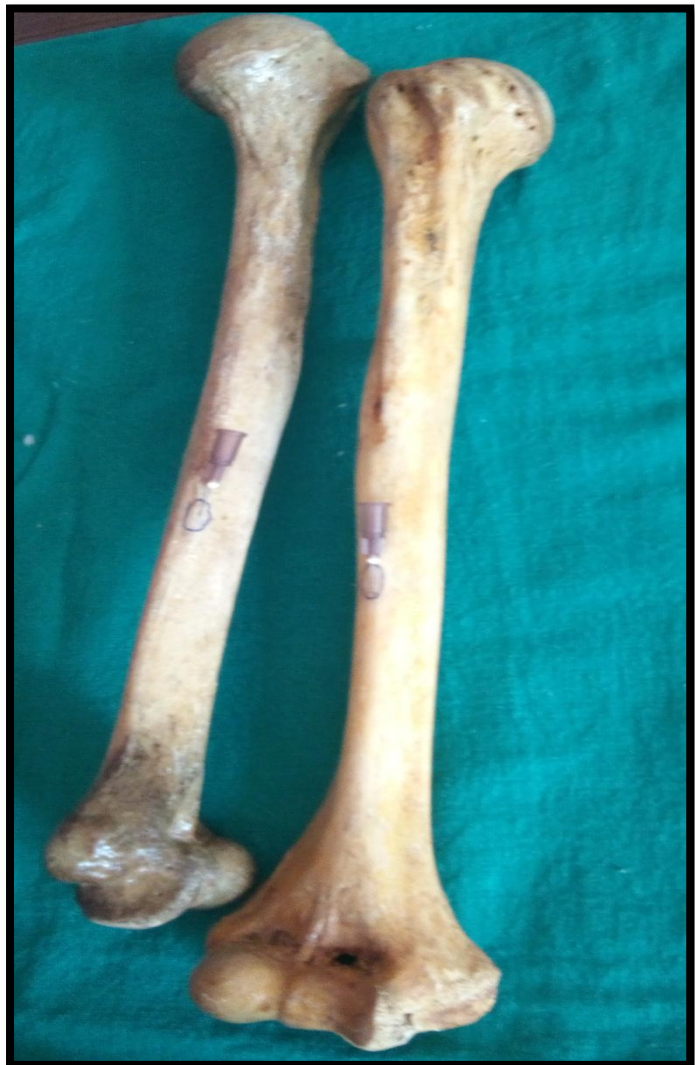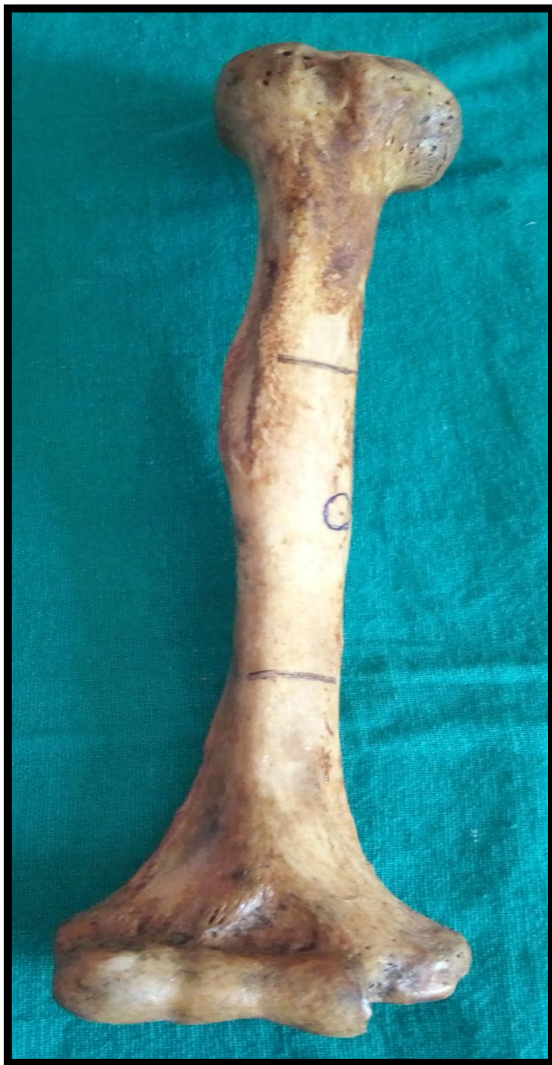Fig 1 shows Location of nutrient Foramen

Table 3-Location of nutrient foramen with respect to zones of humerus

ZONES	RIGHT	LEFT	BOTH
Middle 1/3	42	52	94
Junction of middle and lower1/3	5	18	23
LOWER1/3	2		2

Majority of the bones i.e. 85% have the nutrient foramen located in the middle 1/3rd, 21% at the junction between middle 1/3rd and lower 1/3rd and 2% in the lower 1/3rd.

Direction of nutrient foramen: It was observed that all the nutrient foramina were directed towards the elbow joint i.e. away from the growing end.



Discussion

The blood supply to bones is a very important factor in fracture healing.^[12] In spite of optimal treatment, some fractures heal slowly or fail to heal. This indolent fracture healing may be related to the severity of the injury, poor blood supply, age and nutritional status of the patient or other factors.^[13] Humerus receives highest vascularity among all the bones of upper limb. It is mainly supplied by a branch of brachial artery and also by the branches of axillary, radial and ulnar arteries.^[8]

The constancy of the main nutrient artery to humeral diaphysis is remarkable. The danger of damaging this artery is greatest in open reduction of the fracture involving the mid-shaft region of the bone.^[14]

A study done by **Khan AS et al** on 75 humeri, 90% of humeri had single nutrient foramen. Among them, 96% were located on the middle 1/3rd of anteromedial surface, 2.67% on the posterior surface and 1.33% on the anterolateral surface.^[15] **Ukoha UU et al** studied 150 humeri and found that 66% of them had a single nutrient foramen, 18% had double foramina and 26% had no

foramen. In their study all foramina except one were directed away from the growing end.^[16]

Roul B et al in their study observed that nutrient foramen was found in middle 1/3rd in most of the cases and in lower 1/3rd in few cases.^[17] This finding was supported by another study done by **Chandrasekaran S et al**. The result of the present study also correlates with this. In addition to that the percentage of location of nutrient foramen on the anteromedial surface was 89.92%, on the posterior surface 8.53% and on the anterolateral surface it was 1.55%.^[7]

Carroll stated that the nutrient artery enters through the restricted antero-medial surface, in the middle 1/3rd of the humerus and that the surgeries which are done on the middle 1/3rd of the shaft of the humerus should be handled well without causing damage to the nutrient foramen, in order to prevent delayed unions or non-unions of the fractures.^[17]

According to the study of **Yaseen S et al** on 100 dry humeri, 79% had 1 foramen, 19% had 2 foramina and only 2% had 3 foramina. In our study we did not find 3 foramina. In their study 88.5% of foramina were present on the anteromedial surface, 3.5% on anterolateral surface and 11%

on the posterior surface. With respect to the zones 89% were located in Zone II and 11% in Zone III. None of them were located in Zone I.^[18] In a study of 200 humerii by **Joshi H et al** 63% had a single nutrient foramen which implies that the major blood supply to humeral shaft will enter at one particular point.^[19]

In the present study, percentage of the bones having one nutrient foramen is 70% and two foramina are 29%. Among the bones studied there was no dominant foramen in two bones. About 57% of humerus bones have nutrient foramen located on the medial border. Next in the order are Anteromedial surface (43%), anterior border (4%). Lateral border (5%), Posterior surface (3%). Majority of the bones i.e. 85% have the nutrient foramen located in the middle 1/3rd, 21% at the junction between middle 1/3rd and lower 1/3rd and 2% in the lower 1/3rd. The anatomical knowledge of nutrient foramen is important for orthopaedic surgeons during operations on the humerus like bone grafting and microsurgical bone transplantation.^[20] Precise location of nutrient artery before elective surgery also plays an important role in arterial anastomoses for vascularized grafts.^[21]

Conclusion

It is evident from the study that majority of the humerus bones have single nutrient foramen and they are mainly located on the anteromedial surface especially in the middle 1/3rd. The direction of these foramina is always constant which is away from the growing ends. An understanding of the position and number of the nutrient foramina in long bones is important in orthopaedic surgical procedures such as joint replacement therapy, fracture repair, bone grafts and vascularized bone microsurgery. Orthopaedic surgical procedures like vascularized bone microsurgery requires the detailed knowledge about the blood supply of the operating bone.

Therefore the anatomical knowledge of nutrient foramen is important for orthopaedic surgeons during operations on the humerus like bone grafting and microsurgical bone transplantation.

References

- [1] Malukar O, Joshi H. Diaphysial Nutrient Foramina In Long Bones And Miniature Long Bones, *NJIRM*; 2011;2(2):23-26
- [2] Kizilkanat, E.; Boyan, N.; Ozsahin, E. T.; Soames, R. & Oguz, O. Location, number and clinical significance of nutrient foramina in human long bones. *Ann. Anat.*, 2007; 189:87-95.
- [3] Henderson RG. The position of the nutrient foramen in the growing tibia and femur of the rat. *J Anat* 1978; 125(pt 3):593-599.

- [4] Bharathi A, Janaki V, Gouri TLS, Archana. Morphometric variations of nutrient foramen in adult human humerus in Telangana region. *Journal of Dental and Medical sciences* 2016; 15(4):43-6.
- [5] Mysorekar VR, Diaphysial nutrient foramina in human long bones, *J Anat*, 1967, 101(Pt4):813-822.
- [6] Taylor GI, Fibular transplantation. In: Serafin D, Bunke HJ (eds), *Microsurgical composite tissue transplantation*, C.V. Mosby Co., St. Louis, 1979;418-423.
- [7] Harris HA. *Bone Growth in Health and Disease*. London, Humphrey Milford. 1933.
- [8] Yaseen S, Nitya W, Ravinder M. Morphological and Topographical study of Nutrient foramina in adult humerii. *International journal of innovative research and development* 2014; 3(4):07-10.
- [9] Skawina A., Wyczolkowski M. Nutrient foramina of humerus, radius and ulna in Human Fetuses. *Folia Morphol.*, 1987;46: 17-24.
- [10] Kirschner, M. H.; Menck, J, Hennerbichler, A., Gaber, O. & Hofmann, G. O. Importance of arterial blood supply to the femur and tibia transplantation of vascularized femoral diaphyseal and knee joints. *World J. Surg.*, 1998;22:845-52.
- [11] Standring S. Functional anatomy of the musculoskeletal system. *Gray's Anatomy. The Anatomical basis of clinical practice*. 40th edition. London: Churchill Livingstone Elsevier, 2008;91.
- [12] Carroll SE. A study of nutrient foramina of the humeral diaphysis. *J Bone Joint Surg* 1963;45-3(1):176-81
- [13] Chandrasekaran S, Shanthi K C A study on the nutrient foramina of adult humerii. *Journal of clinical and diagnostic research* 2013; 7(6):975-7.
- [14] Buchholz RW, Brown CMC, Heckman JD, Tornetta P, McQueen MM, Ricci WM. Bone and joint healing. In: Buckwalter JA, Einhorn TA, Marsh JL, Gulotta L, Ranawat A, Lane J, editors, *Rockwood and Green's Fractures in Adults*. 7th edition. Philadelphia: Lippincott Williams and Wilkins, 2010; 1:90.
- [15] Khan AS, Shah Z, Inayat Q. Anatomical variations in diaphyseal nutrient foramina of humerus in cadavers from Khyber Pakhtunkhwa, Pakistan. *Khyber Medical University Journal* 2014; 6(1):18-21.
- [16] Ukoha UU, Umeasalugo KE, Nzeako HC, Ezejindu DN, Ejimofor OC, Obazie IF. A study of nutrient foramina in long bone of Nigerians. *National Journal of Medical Research* 2013; 3(4):304-8.
- [17] Roul B, Goyal M. A study of nutrient foramen in long bones of superior extremity in human being. *International Journal of Current Research in Life Sciences* 2015; 4(4):198-200.

- [18] Joshi H, Doshi B, Malukar O A study of the nutrient foramina of the humeral diaphysis. National Journal of Integrated Research in Medicine 2011; 2(2):14-7.
- [19] Laing PG. The arterial supply of the adult humerus. The journal of Bone and Joint surgery 1956; 38(5):1105-16.
- [20] Solanke KS, Bhatnagar R, Pokhrel R. Number and position of nutrient foramina in humerus, radius and ulna of human dry bones of Indian origin with clinical correlation. OA Anatomy 2014; 2(1):01-4.
- [21] Asharani S K, Ajay Ningaiah. A Study on nutrient foramen of humerus 2016, 4(3):2706-9