

Analysis of Bronchoscopic Findings in Patients Diagnosed with Malignancies

Dr Deepali R Gaikwad

MBBS, DTCD, DNB (Resp Diseases)

Consultant Pulmonologist, Advika Chest Clinic,

Former Associate Professor, MIMER Medical College, Talegaon Dabhade, Pune, Maharashtra

Email- drg1818@rediffmail.com



Address - Radhainagari, B-2 / 503, Pimple Suadagar,

Near Hotel Govind Garden, Aundh Camp, Pune. Maharashtra-411027, India

Abstract:

Objective: To evaluate bronchoscopic findings in patients referred for bronchoscopy.

Method: This is a prospective study done at tertiary care centre. Observations of bronchoscopy were noted in patients referred from various departments for flexible fiberoptic bronchoscopy.

Results: Of 48 cases studied, 23 cases (47.9%) were males and 25 cases (52.08%) were females. Male to female sex ratio in the entire group was 1: 1.08. The minimum – maximum age range was 21.0 years – 72.0 years and the mean \pm SD of age of the entire group was 55.4 ± 10 years.

Of 48 cases studied, 32 cases (66.6%) had cancer of esophagus, 13 cases (27.0%) had cancer of lung, 1 case (2.08%) had cancer of ovary, 1 case (2.08%) had cancer of thyroid, and 1 case (2.08%) had cancer of pyriform fossa diagnosis. Of 48 cases of malignancy studied (n=48), 35 cases (72.91%) had normal Bronchoscopic findings and 13 cases (27.08%) had abnormal Bronchoscopic findings.

In nonpulmonary malignancies abnormal bronchoscopic findings are 14.28% (n=35)

Conclusion:

1. All patients diagnosed of non-pulmonary malignancies should be evaluated for Pulmonary and endobronchial metastases.
2. All patients diagnosed of esophageal malignancy should be evaluated for tracheobroncheal involvement.

Keywords: Fiberoptic bronchoscopy, Endobronchial metastases, Pulmonary and Nonpulmonary Malignancies

Introduction

Flexible Fiberoptic bronchoscopy is a reliable, safe technique in the evaluation of lung diseases, assessment of staging of lung cancer and pre-surgical evaluation of malignancies.

Bronchoscopy provides a visual assessment of endobronchial tumor. Metastatic spread of malignant tumors to central airways is often seen.

Both primary and metastatic malignancies affect endobronchial tree. The spectrum of bronchoscopic abnormalities vary from subtle mucosal edema, erythema and irregularity of overtly obvious mucosal masses.^[1]

Vocal cord paralysis, widened carina, tracheobronchial endoluminal metastases are also bronchoscopic findings in cases of malignancy. Possibility of malignancy should be excluded before marking idiopathic reason to vocal cord paralysis.^[2] Vocal cord paralysis can be originated from malignant invasion to vagus nerve or recurrent laryngeal nerve. Invasion by malignant neoplasms can be generated by the thyroid neoplasms, lung cancer, esophagus carcinoma and mediastinal metastasis.^{[3],[4]} Left laryngeal nerve is more vulnerable than the right because travels a longer route in thoracic cavity. Immobility of vocal cord may indicate involvement of recurrent laryngeal nerve with tumor, which is a sign of inoperability (T4).

Widening of carina is highly suggestive of involved subcarinal lymphnode. Endobronchial lesions that involve

the trachea or carina are considered to be stage T4 and tumors within 2cm of carina are defined as T3.^{[5],[6]}

However reports of the incidence of endobronchial metastases are inconsistent, ranging from 2% to 28%.^{[7],[8]}

Materials and Methods

This is a prospective study done at tertiary care centre from 18th May 2015 to 31st May 2015. Fiberoptic Flexible Bronchoscopy was performed in patients referred from various departments with consent. Observations of bronchoscopy were noted. Cases of pneumonia underwent bronchoscopy excluded from study.

Statistical Methods:

Table 1: Age and sex distribution of cases studied.

Age Group (years)	Male (n=23)		Female (n=25)		Total (n=48)	
	n	%	n	%	n	%
Less than 40.0	2	4.1	2	4.1	4	8.2
40.0 – 49.0	3	6.2	6	12.5	9	18.7
50.0 – 59.0	7	14.5	9	18.7	16	33.2
60.0 – 69.0	10	20.8	7	14.5	17	34.3
More than 70	1	2.08	1	2.08	2	4.1
Total	23	100.0	25	100.0	48	100.0

Values are n (% of cases).

Of 48 cases studied, 23 cases (47.9%) were males and 25 cases (52.08%) were females. The male to female sex ratio in the entire group was 1: 1.08. Of 48 cases studied, majority of cases (33 cases, 68.7%) had their age between 50.0 – 69.0 years. The minimum – maximum age range was 21.0 years – 72.0 years and the mean \pm SD of age of the entire group was 55.4 ± 10 years..

The data on categorical variables is shown as n (% of cases). The inter-group comparison of categorical variables is done using Chi-square test. The entire data was entered and cleaned in MS Excel before its statistical analysis. All the results are shown in tabular as well as graphical format to visualize the statistically significant difference more clearly.

In the entire study, the p-values less than 0.05 are considered to be statistically significant. All the hypotheses were formulated using two tailed alternatives against each null hypothesis (hypothesis of no difference). The entire data is statistically analyzed using Statistical Package for Social Sciences (SPSS version 21.0, IBM Corporation, USA) for MS Windows.

Results

Of 23 male cases studied, majority of cases (17 cases, 35.41%) had their age between 50.0 – 69.0 years and the mean \pm SD of age of males was 55.7 ± 11.2 years.

Of 25 female cases studied, majority of cases (16 cases, 33.3%) had their age between 50.0 – 69.0 years and the mean \pm SD of age of females was 54.8 ± 9.0 years.

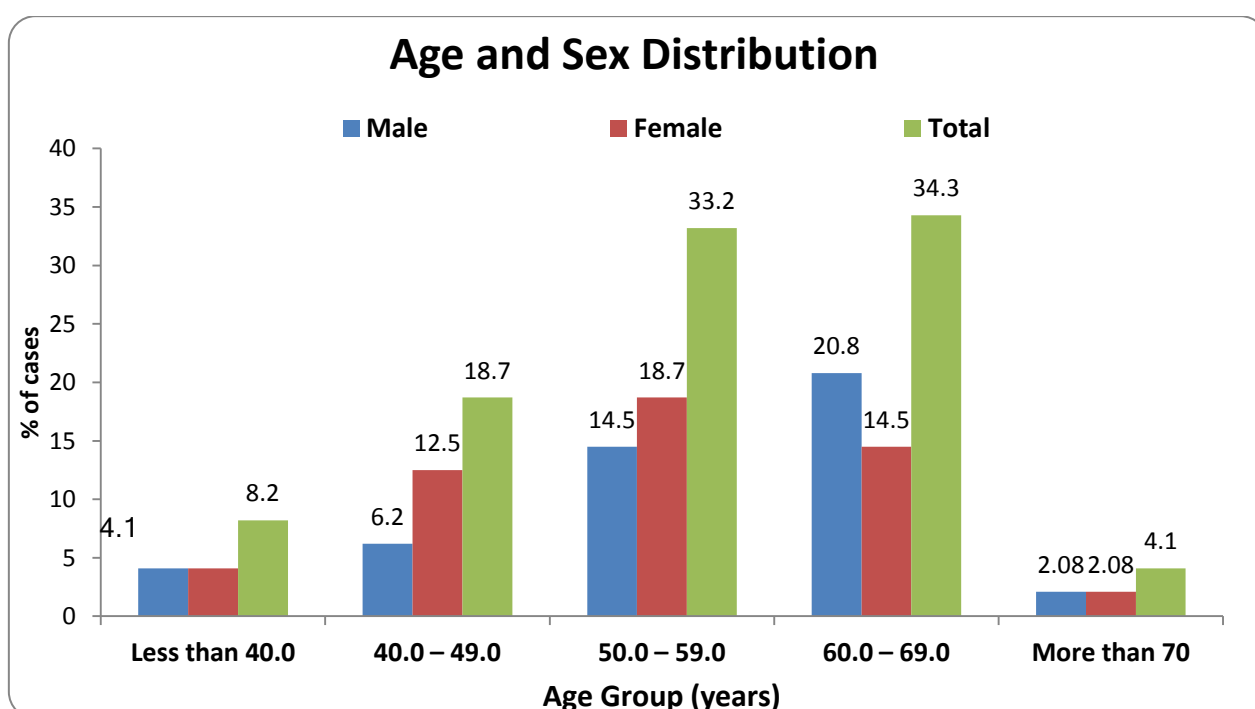


Figure 1: Age and sex distribution of cases studied.

Table 2: The distribution of diagnosis of the cases studied

Diagnosis	No. of cases	% of cases
Cancer of Esophagus	32	66.6
Cancer of Lung	13	27
Cancer of Ovary	1	2.08
Cancer of Thyroid	1	2.08
Pyriform Fossa	1	2.08
Total	48	100.0

Values are n (% of cases).

Of 48 cases studied, 32 cases (66.6%) had cancer of esophagus, 13 cases (27.0%) had cancer of lung, 1 case (2.08%) had cancer of ovary, 1 case (2.08%) had cancer of

thyroid and 1 case (2.08%) had cancer of pyriform fossa diagnosis.

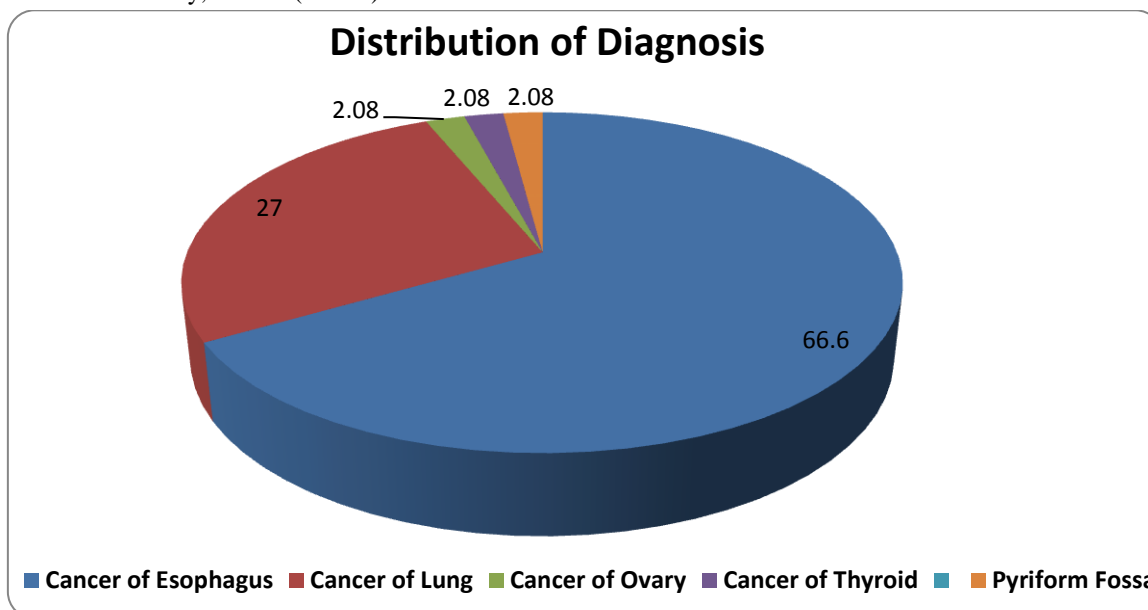


Figure 2: The distribution of diagnosis of the cases studied.

Table 3: The distribution of vocal cord status

Vocal cord	No. of cases	% of cases
Mobile	45	93.75
Fixed	3	6.25
Total	48	100.0

Values are n (% of cases).

Of 48 cases studied, 45 cases (93.75%) had mobile vocal cord and 3 cases (6.25%) had fixed vocal cord.

Table 4: The distribution of type of carina

Carina	No. of cases	% of cases
Sharp	45	93.75
Wide	3	6.25
Total	48	100.0

Values are n (% of cases).

Of 48 cases studied, 45 cases (93.75%) had sharp carina and 3 cases (6.25%) had wide carina.

Table 5: The distribution of bronchoscopic findings

Bronchoscopic Findings	No. of cases	% of cases
Normal	35	72.91
Abnormal	13	27.08
Total	48	100.0

Of 48 cases of malignancy studied (n=48), 35 cases (72.91%) had normal Bronchoscopic findings and 13 cases (27.08%) had abnormal Bronchoscopic findings.

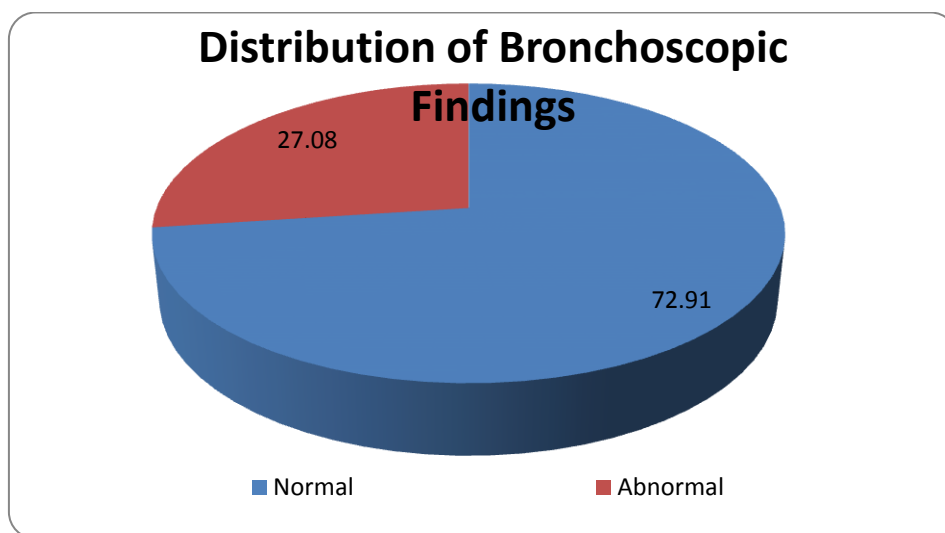


Figure 4: The distribution of bronchoscopic findings.

Table 6: The distribution of Bronchoscopic findings according to the diagnosis

Diagnosis	Bronchoscopic findings						P-value
	Normal		Abnormal		Total		
	n	%	n	%	n	%	
Cancer of Esophagus	29	90.6	3	9.4	32	100.0	0.001***
Cancer of Lung	5	38.4	8	61.5	13	100.0	
Cancer of Ovary	0	0.0	1	100.0	1	100.0	
Cancer of Thyroid	0	0.0	1	100.0	1	100.0	
Pyriiform Fossa	1	100.0	0	0.0	1	100.0	
Total	35	72.91	13	27.08	48	100.0	

Values are n (% of cases). P-value by Chi-Square test. P-value less than 0.05 is considered to be statistically significant. ***P-value<0.001. Of 32 cases with cancer of esophagus, 3 cases (9.4%) had abnormal bronchoscopic findings and 29 cases (90.6%) had normal findings.

Of 13 cases with cancer of lung, 8 cases (61.5%) had abnormal bronchoscopic findings and 5 cases (38.4%) had normal findings.

Of 35 cases with nonpulmonary malignancies, 5 (14.2%) had abnormal bronchoscopic findings.

One case each who had cancer of ovary, cancer of thyroid, all of them had abnormal bronchoscopic findings and one case who had Pyriiform Fossa malignancy had normal bronchoscopic findings.

The distribution of bronchoscopic findings differs significantly across various groups of diagnosis (P-value<0.001).

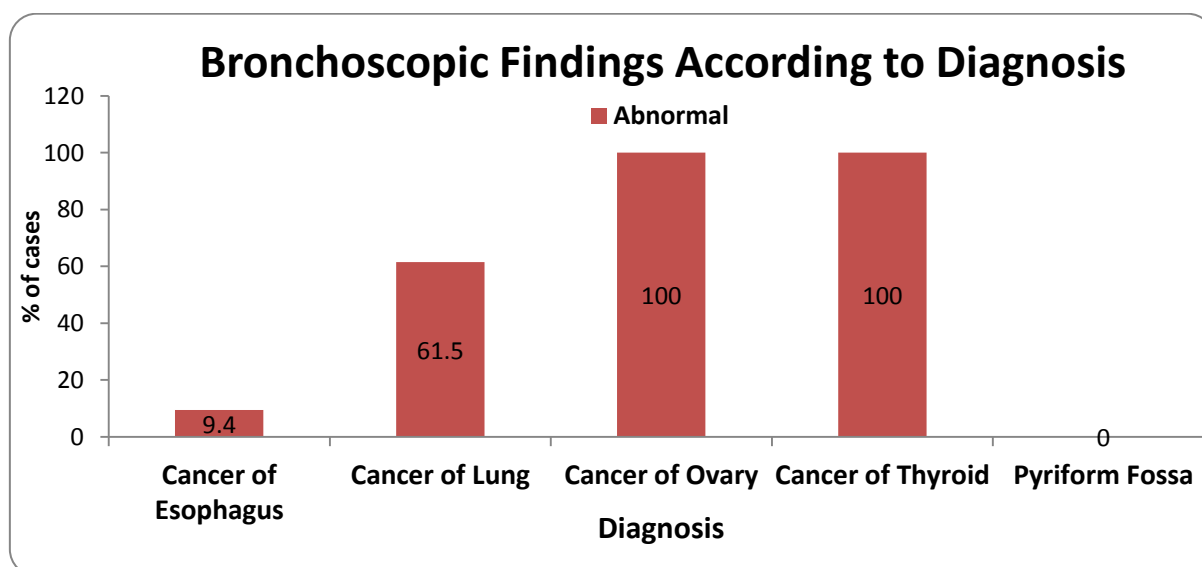


Figure 5: The distribution of Bronchoscopic findings according to the diagnosis.

Discussion

Extrapulmonary malignant tumors can spread to the bronchial tree through the blood or the lymphatic system or from adjacent parenchymal or mediastinal tissues.^[9]

Shephard found endobronchial metastases in 28% of 90 patients with pulmonary metastases who underwent bronchoscopy.^[8] He defined endobronchial metastases as those readily visible bronchoscopically.

Endobronchial metastases can originate from variety of tumors. These include melanoma, soft tissue sarcoma, carcinomas of breast, tongue, penis, testis, kidney, larynx, pharynx, prostate, ovary, uterus, urethra, pancreas, thyroid gland, adrenal gland, colon and rectum. Although reported relative frequency at which the various primary extrapulmonary tumors lead varies. The most common extrathoracic tumor associated with metastatic involvement of central airway are renal and colorectal carcinomas.^[10]

In the present study endotracheal and endobronchial metastases including vocal cord paralysis were seen in cancer of esophagus, thyroid carcinoma, primary malignancy of lung, and ovarian cancer. Among 32 cases of esophageal cancer 3 cases (9.4%, n=32) showed endotracheal, endobronchial involvement and vocal cord paralysis. In study done by Argyros GJ et al 20 cases were identified in which FB was performed to evaluate pulmonary involvement in patients with newly diagnosed esophageal carcinoma. 17 of 20 had no pulmonary symptoms and had normal chest radiograph, findings were normal in nine, showed extensive compression of trachea and/or bronchi in seven and submucosal tumor nodule in one.^[11]

In this study, of 13 cases with cancer of lung, 8 cases (61.5%) had abnormal bronchoscopic findings and 5 cases (38.4%) had normal findings. One case of 13 lung cancer was carcinoid lung. Carcinoid tumors account for less than 1% of all lung tumors. 75% of carcinoid tumors result in atelectasis owing to bronchial obstruction.^[12] One case of carcinoma thyroid showed endotracheal growth and one case of ovarian cancer showed tracheo-esophageal fistula.

Thyroid malignancy with endotracheal spread has rarely reported in literature. This finding is a result of vascular spread or lymphatic in absence of continuity of mass with thyroid nodule in imaging studies.^[13]

Endobronchial metastasis of ovarian cancer is extremely rare. Ovarian cancers metastasize to the pleura and lung parenchyma.^{[14],[15]} Tracheo-esophageal fistula in ovarian cancer is not reported in literature.

Conclusion

1. All patients diagnosed of non-pulmonary malignancies should be evaluated for Pulmonary and endobronchial metastases.
2. All patients diagnosed of esophageal malignancy should be evaluated for tracheobronchial involvement.

References

- [1] Udaya B. S. and Sergio Cavaliere. Bronchoscopy. Atlas of Bronchoscopy, Chapter 32, pg494
- [2] Seyed Javad Seyed Toutouchi, Mahmood Eydi et al. Vocal Cord Paralysis and its Etiologies: A Prospective Study. J Cardiovasc Thorac Res. 2014; 6(1):47-50.
- [3] Evans JM, Schucany WG. Hoarseness and cough in 67-year old woman. Proc (Bayl Univ Med Cent) 2004 Oct;17(4):469-72
- [4] Chen HC, Jen YM, Wang CH, Lee JC, Lin YS. Etiology of vocal cord paralysis. ORL J Otorhinolaryngol Relat Spec. 2007; 69:167-71.
- [5] Titche LL. Causes of recurrent laryngeal nerve paralysis. Arch Otolaryngol. 1976; 102:259-61.
- [6] Purandare NC, Rangarajan V. Imaging of Lung Cancer: Implications on staging and management. Indian Journal of Radiology and Imaging. 2015; 25(2):109-120.
- [7] Terri Aminah Matin and Melvyn Goldberg. Surgical Staging of Lung Cancer. Oncology. 1999; 13(5):679-685
- [8] MP Shepherd. Endobronchial metastatic disease. Thorax 1982; 37:362-365.
- [9] Katsuhisa Oshikawa, Shoji Ohno et al. Evaluation of Bronchoscopic Findings in Patients with Metastatic Pulmonary Tumor. Internal Medicine 1998; 37:349-3
- [10] Sidney S. Braman, Michael E. Whitcomb. Endobronchial Metastasis. Arch Intern Med. 1975; 135(4):543-547.
- [11] Argyros GJ, et al. Fiberoptic bronchoscopy in the evaluation of newly diagnosed esophageal carcinoma. Chest 1995; 107(5):1447-1449.
- [12] Jussuf T Kaiffi, Gian Kayser et al. The Diagnosis and Treatment of Bronchopulmonary Carcinoid. Dtsch Arztebl Int. 2015 Jul; 112(27-28): 479-485.
- [13] Bitoti Chattopadhyay, Biswamit Bhattacharya and et al. Whistle from Afar: A Case of Endotracheal Metastasis in Papillary Thyroid Cancer. Case Reports in Oncological Medicine 2012; 2012: Article ID 235062, 3 pages. CrossRef(<http://dx.doi.org/10.1155/2012/235062>)
- [14] Mateo F, Serur E, Smith PR. Bronchial metastases from ovarian carcinoma. Report of a case and review of the literature. Gynecol Oncol. 1992 Aug; 46(2):235-8. [PubMed]

[15]Upadhyay A, Goel V et al.Two cases of ovarian carcinoma with endobronchial metastases: Rare presentation. Southasian Journal Cancer.2015 July-Sept; 4(3):149.

Interest of conflicts: None

Funding: This reasearch is not funded by any private or public funding agency.

Open Access This article is licensed under a Creative Commons Attribution 4.0 International License, which permits use, sharing, adaptation, distribution and reproduction in any medium or format, as long as you give appropriate credit to the original author(s) and the source, provide a link to the Creative Commons license, and indicate if changes were made. The images or other third party material in this article are included in the article's Creative Commons license, unless indicated otherwise in a credit line to the material. If material is not included in the article's Creative Commons license and your intended use is not permitted by statutory regulation or exceeds the permitted use, you will need to obtain permission directly from the copyright holder. To view a copy of this license, visit: <http://creativecommons.org/licenses/by/4.0/>.

© The Author(s) 2018