

# Tragal Cartilage Versus Polytetrafluoroethylene (TEFLON) Partial Ossicular Replacement Prosthesis (PORP): A Comparative Study of Outcomes of Ossiculoplasty

F.Pathan<sup>\*1</sup>, S.Satpathy<sup>2</sup>, S. Bhalekar<sup>3</sup>, K Sudarshan<sup>4</sup>

<sup>\*1</sup>Assistant Professor, Department of ENT, Terna Medical College, Nerul, Navi Mumbai, Maharashtra, India

<sup>2</sup>Professor & Head, Department of ENT, Terna Medical College, Nerul, Navi Mumbai, Maharashtra, India

<sup>3</sup>Associate Professor, Department of ENT, D.Y. Patil Medical College, Nerul, Navi Mumbai, Maharashtra, India

<sup>4</sup>Assistant Professor, Department of ENT, Terna Medical College, Nerul, Navi Mumbai, Maharashtra, India

**Abstract:** Reconstruction of the conductive mechanism of the middle ear is one of the most intriguing topics in middle ear surgery. An implant in middle ear should be safe, biocompatible, stable, easily insertable and capable of yielding optimal sound transmission. A comparative prospective study of 50 patients each of ossiculoplasty between tragal cartilage, and polytetrafluoroethylene (teflon) partial ossicular replacement prosthesis (PORP) to analyse the hearing gain at the end of six months between cartilage ossiculoplasty and Teflon PORP (Partial Ossicular Replacement Prosthesis). In our study it was observed that the degree of post-operative hearing improvement when cartilage was used as a ossiculoplasty material was consistently more than when PORP was used which was statistically significant.

**Keywords -** Ossiculoplasty, cartilage ossiculoplasty, PORP, TEFLON, Tragal cartilage

## Introduction:

Reconstruction of the conductive mechanism of the middle ear is one of the most intriguing topics in middle ear surgery. The earliest recorded attempt to re-establish a connection between the tympanic membrane and the oval window was by Matte in 1901.<sup>1</sup> Since then plethora of prostheses have been used for ossicular reconstruction including both biological materials like autograft or homograft ossicles, cortical bone, teeth, cartilage and alloplastic materials like teflon, proplast, silastic, stainless steel, titanium & gold.<sup>2,3</sup> The ideal prosthesis for ossicular reconstruction should be biocompatible, stable, safe, and easily insertable and capable of yielding optimal sound transmission. We present a comparative prospective study of outcomes of ossiculoplasty between tragal cartilage, and polytetrafluoroethylene (teflon) partial ossicular replacement prosthesis (PORP) to analyse the hearing gain at the end of six months between cartilage ossiculoplasty and Teflon PORP (Partial Ossicular Replacement Prosthesis)

## Materials and Methods:

This is a prospective study of 100 patients who underwent ossiculoplasty at a tertiary health care facility with adequate outpatient, inpatient, and

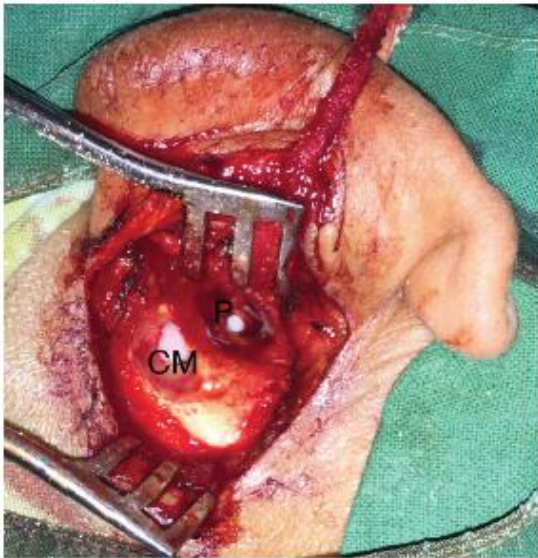
diagnostic capabilities during the period from July 2012 to August 2015. Patients aged 15–55 years with chronic suppurative otitis media (CSOM) with a air bone gap (ABG) of >25 dB and ossicular involvement were included in the study. Patients with sensorineural hearing loss, complicated CSOM, normal tympanic membrane, revision surgery, eroded supra-structure of stapes or a fixed stapes footplate were excluded from the study. The 100 patients were categorised intraoperatively in to two groups of 50 patients where one group underwent ossiculoplasty with tragal cartilage and the other with polytetrafluoroethylene (teflon) partial ossicular reconstruction prosthesis (PORP). After control of the infection and obtaining an anesthetic fitness the patients underwent the operative procedure.

All patients were asked to return for follow-up on Days 7, 15, and 45 after surgery, as well as after 3 and 6 months.

In cartilage group, tragal cartilage was harvested, carved into a rectangular piece such that the breadth of which was placed over the stapes head and the other end at the annulus of the tympanic membrane. The perforation was then covered by placing a temporalis fascia in a full cuff technique. In POLYTETRAFLUOROETHYLENE (TEFLON)

PORP group, the prosthesis was placed over the stapes head which was then covered by a piece of sliced tragal cartilage graft. (Fig. 1) The perforation was repaired by using temporalis fascia in a full cuff technique.

Fig.1



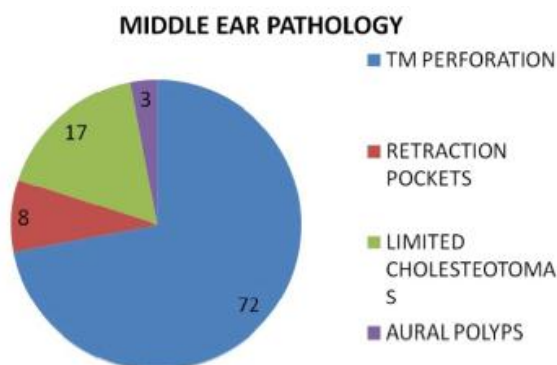
P – PORP, CM - Cortical Mastoidectomy

All our patients underwent post operative pure tone audiometry at the end of six months. The average air bone gap in the frequencies (500 Hz, 2000Hz and 4000Hz) were again noted.

**Results:**

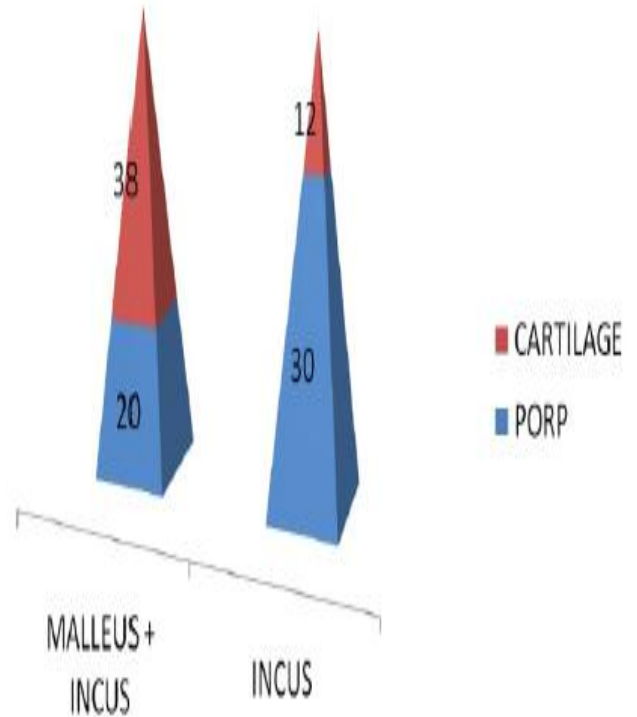
In our study of 100 patients of chronic otitis media, 62 patients were male and 38 patients were female. Out of 100 patients, 72 patients presented to us with a perforated tympanic membrane, 8 with retraction pockets, 17 with limited cholesteatoma disease and 3 with aural polyp. (Fig. 2)

Fig. 2



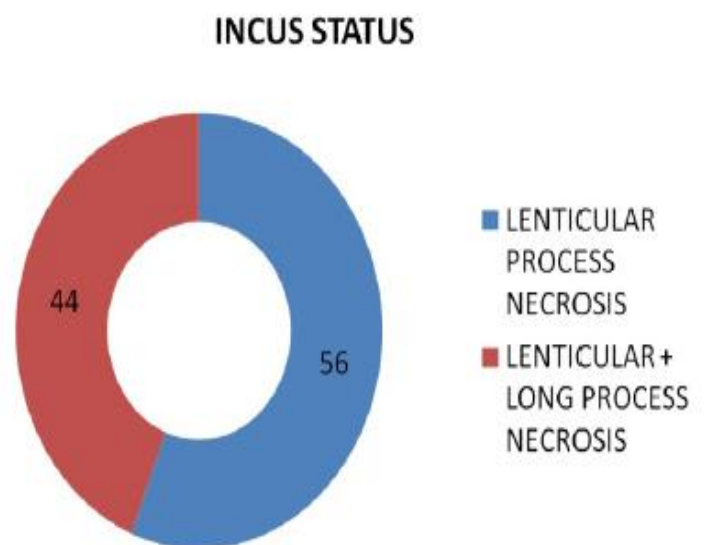
Malleus and incus either partially or completely necrosis was seen in 58 cases. 42 cases showed either partial or complete necrosis of only the incus. (Fig. 3)

Fig. 3



Intraoperatively, necrosis of lenticular process was seen in 56 cases & long process along with lenticular process was necrosed in 44 cases. (Fig. 4).

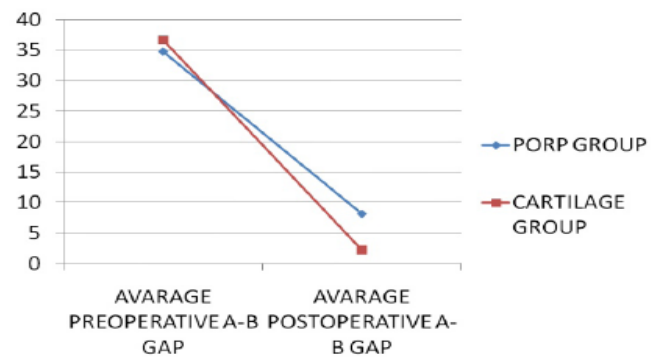
Fig. 4



**Discussion:**

In our study of 100 patients of Chronic Otitis Media, 62 patients were male and 38 patients were female. A comparison between the pre-operative conductive hearing loss and the post-operative gain in hearing was made when pure tone audiometry was repeated after six months. In our study it was observed that the amount of post-operative hearing improvement when cartilage was used as a ossiculoplasty material was consistently more than when PORP was used which was statistically significant (Fig. 5, table 1,2,3).

**Fig. 5**



**Table - 1:**

Material Used ( Cartilage )	N	Mean	SD	Paired T Test	P – value	Significant at 5% level
PRE OP AB GAP	50	36.66	6.86	31.597*	0.000	YES
POST OP AB GAP	50	2.264	3.55			

\*Statistically Significant at 5% level i.e P<0.05 .

**Table – 2:**

Material Used ( PORP )	N	Mean	SD	Paired T Test	P –value	Significant at 5% level
PRE OP AB GAP	50	34.77	8.46	24.151*	0.000	YES
POST OP AB GAP	50	8.21	5.46			

\*Statistically Significant at 5% level i.e P<0.05

**Table – 3:**

PRE OP AB GAP	N	Mean	SD	Paired T Test	P –value	Significant at 5% level
Cartilage	50	36.66	6.86	1.228	0.222	NO
PORP	50	34.77	8.46			
POST OP AB GAP						
Cartilage	50	2.26	3.55	6.458*	0.000	YES
PORP	50	8.21	5.46			

\*Statistically Significant at 5% level i.e P<0.05.

In a study conducted by Mahanty S, hearing results were measured by PTA-air bone gap (PTA-ABG) after 6 months of operation. In their study the criteria of <20 dB air bone gap was termed as successful. Thus they concluded 60% success rate, for ossiculoplasty using

cartilage and 56.25% for PORP. Extrusion rate for PORP was 25%, whereas cartilage was 20%. In yet another study by Chavan S which used the Teflon TORP(Total Ossicular Replacement Prosthesis) and PORP the success was defined as an ABG <25 dB on

postoperative day 90. Out of 80 cases, 64 patients had an ABG <25 dB, accounting for an overall success rate of 80.0%.<sup>4</sup> Naragund A in his study found that of the 24 patients with ossicular chain defect, 12 patients underwent ossiculoplasty with autograft incus and 12 with titanium prosthesis. Postoperative hearing evaluation by pure tone audiogram was done after 3 months, which showed successful hearing improvement in 58% of cases with autologous incus as compared to 33% cases with titanium prosthesis.<sup>5</sup>

Multiple factors impact successful reconstruction of the middle ear's sound conduction mechanism. Prosthesis design, surgical technique, and the underlying disease process are the most obvious variables. The mass and stiffness of prosthesis may influence sound conduction in a frequency-dependent manner. Studies by Meister et al<sup>6</sup> and Kelly et al<sup>7</sup> have suggested that mass is the most important variable and have recommended, therefore, that a prosthesis be as light as possible to optimize transmission of frequencies above 1000 Hz.

### Conclusion:

The ideal middle ear prosthesis for ossiculoplasty should be compatible, stable, safe, readily available, easily insertable, and capable of yielding optimal sound transmission which is still an enigma. In our study of 100 cases we found cartilage ossiculoplasty to yield us better results in terms of hearing. A larger prospective study is required to ascertain the advantage of naturally available tragal cartilage over the Polytetrafluoroethylene (teflon) partial ossicular replacement prosthesis (PORP).

### References:

- [1] Treace HT. Biomaterials in ossiculoplasty and history of development of prostheses for ossiculoplasty. *Otolaryngol Clin North Am* 1994; 27:655-62.
- [2] Battista RA, Meyers AD, editors. *Ossiculoplasty*. Medscape. Available from: <http://emedicine.medscape.com/article/859889-overview>[Last updated on 2014 Dec 16].
- [3] Frootko NJ. Reconstruction of the middle ear. In: Kerr AG, editor. *Scott Brown's Otolaryngology*. 6<sup>th</sup> ed., Vol. 3. Great Britain: Hodder Arnold; 1997. p. 8-26.

- [4] Chavan, S. S., Jain, P. V., Vedi, J. N., Rai, D. kumar, & Kadri, H. (2014). Ossiculoplasty: A Prospective Study of 80 Cases. *Iranian Journal of Otorhinolaryngology*, 26(76), 143–150.
- [5] Naragund AI, Mudhol R S, Harugop A S, Patil P H. Ossiculoplasty with autologous incus versus titanium prosthesis: A comparison of anatomical and functional results. *Indian J Otol* 2011; 17:75-9
- [6] Meister H, Walger M, Michenhagen A, von Wedel H, Stennert E. Standardized measurements of the sound transmission of middle ear implants using a mechanical middle ear model. *Eur Arch Otorhinolaryngol* 1999; 256:122-7.
- [7] Kelly DJ, Prendergast PJ, Blayney AW. The effect of prosthesis design on vibration of the reconstructed ossicular chain: A comparative finite element analysis of four prostheses. *Otol Neurotol* 2003; 24:11-9.

Conflict of interest : None  
No source of funding