

Conventional Dacryocystorhinostomy Versus Pawar's Implant Dacryocystorhinostomy - A Prospective Study



Shivcharan Lal Chandravanshi¹, Sunil Kumar Shrivastava², Devendra Kkumar Shakya³, Uma Saran Tiwari³

¹Associate Professor, Department of Ophthalmology, Shyam Shah Medical College, Rewa, M.P., India

²Resident, Associate Professor, Shyam Shah Medical College, Rewa, M.P., India

³Professor, Department of Ophthalmology, G.R. Medical College, Gwalior, M.P., India

Abstract

Purpose: To compare conventional dacryocystorhinostomy (DCR) with Pawar's intracystic implant dacryocystorhinostomy in terms of surgical technique, complications and success rate for primary acquired nasolacrimal duct obstruction (NLDO). **Materials and Methods:** This is a prospective comparative, nonrandomized, clinical study. It is carried out on 50 cases of primary acquired NLDO. The 50 cases were divided into two groups; Group A consisting of 30 cases that underwent Pawar's intracystic implant DCR whereas Group B consisting of 20 cases those operated by conventional DCR technique. Data regarding demographic profile of patients, mode of presentation, diagnosis, intraoperative variables such as surgical duration, intra- and post-operative complications, hospital stay and causes of failure and final surgical outcome, were analyzed. Clinical success was defined as patent lacrimal system on irrigation (objective) and absence of symptoms (subjective). **Results:** Out of 50 cases 40 (80%) were female and 10 cases (20%) were males. In this study, 39 (78%) cases had chronic dacryocystitis, followed by pyoceles/mucoceles 5 (10%), chronic dacryocystitis with lacrimal fistula 3 (6%), and previous failed DCR surgery 3 (6%). Hemorrhage from nasal mucosa was observed in 9 cases (45%) during conventional DCR surgery and one case (3.33%) in implant DCR. Hemorrhage from angular vein occurred in 1 case (5%) during conventional DCR. Nasal mucosa was disrupted/damaged in 8 cases (40%) during conventional DCR. The average operating time in conventional DCR is 110.50 minutes while for Pawar's implant DCR is 27.33 minutes. The commonest post-operative complication of Pawar's intracystic implant DCR was obstruction of passage found in 4 cases (13.33%). Hypertrophic scar was the most common postoperative complication in 8 cases (40%) in conventional DCR. Success rate of implant DCR at 2 months follow up was 83.33% and at the end of 3 months after management of failed cases of implant DCR was 96.66%. Success rate of conventional DCR at 2 months follow up was 80% and at the end of 3 months after management of failed cases of conventional DCR was 85%. **Conclusion:** The success rate of Pawar's intracystic implant DCR is comparable with conventional DCR with additional advantages such as easy, quick, minimal intra- and post operative complication and possibility of conventional DCR in future in failed Pawar's implant DCR.

Keywords: Pawar's intracystic implant, chronic dacryocystitis, Conventional dacryocystorhinostomy, Implant dacryocystorhinostomy, Nasolacrimal duct obstructions, Epiphora

Introduction

Dacryocystitis is inflammation of the lacrimal sac and nasolacrimal duct.^[1] It is a common clinical entity causing troublesome and conspicuous symptoms. It has tendency to recur and persist until definitive surgical treatment in form of dacryocystectomy (DCT) or dacryocystorhinostomy (DCR) is performed. Basic pathology is obstruction of nasolacrimal drainage system. Dacryocystorhinostomy is the gold standard surgical treatment of nasolacrimal duct (NLD) obstruction that aims at anastomosis of the nasal mucosal flaps with flaps from the lacrimal sac in the region of middle meatus of the nose. For the first time, the method of dacryocystorhinostomy was described by Toti in the year of 1904.^[2] Later on by various authors modification in original surgery were done according to site of obstruction in nasolacrimal passage and status of lacrimal sac.^[3] The major issues concerning DCR include prolonged operative time, intraoperative & postoperative hemorrhage and patient discomfort.

The above mentioned issues call for the development of a new method wherein all these problems can easily be tackled.

One such newer technique has been introduced in 1985 by Dr. M.D. Pawar, Nagpur (India) which is popularly known as IMPLANT DCR.^[4-6] The aim of this study is to compare the conventional DCR with Pawar's intracystic implant DCR in terms of the surgical technique, complications and the success rate.

Materials and Methods

A prospective study of 50 cases was carried out in the Department of Ophthalmology, G. R. Medical College and associated J.A. group of Hospitals, Gwalior (M.P.) during the period of January 2003 to January 2004. A pre-operative evaluation of all the patients including ENT check up was carried out prior to surgery. The NLD obstruction was confirmed using a syringing procedure. Patients having obstruction of upper and/ or lower canaliculus or the common canaliculus, patients with nasal pathology causing obstruction of the NLD, and patients with bleeding disorders, were

excluded from the study. Informed consent was obtained after explaining the surgical procedure and its consequences. Base line investigation like hemogram, coagulation profile, blood sugar, X-ray para nasal sinuses were done in all patients. Physician fitness was obtained prior to the surgery. All operations were performed under local anesthesia. The 50 cases were divide into two groups; Group A consisting of 30 cases those were underwent Pawar's implant DCR where as Group B consisting of 20 cases which underwent conventional DCR technique. The study was approved by the Institutional board and adhered to the tenets of Declaration of Helsinki. Written consent was taken from all participants prior to study. Results were expressed in percentage and p value less than 0.05 was considered as statistically significant.

Pawar's intracystic implant

It is made up of medical grade silicone elastomer providing maximum tissue compatibility and minimum thrombogenicity. The length of implant varies from 12 mm to 17 mm with an external diameter 3 mm and an internal diameter of 2.5 mm (figure 1A). The implant has a collar of size 8 mm vertically and 5 mm horizontally, which rest on the lacrimal sac cavity. Implants are provided with 4 holes at the upper end near collar and 6 holes at the lower ends 5 mm prior to distal end. They act as extra drainage channel having 1 mm diameter. This Pawar's implant is supplied as gamma rays sterilized packet containing single piece.

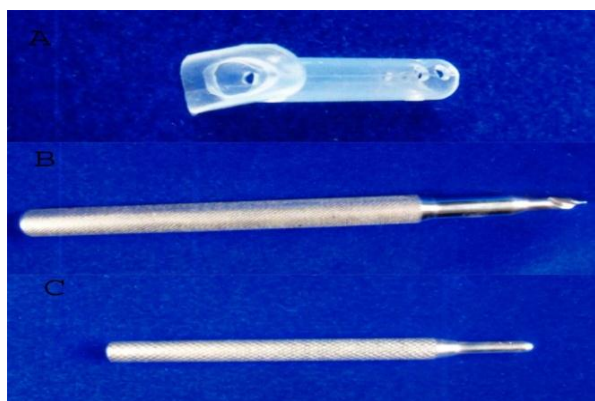


Figure 1A: Pawar's intracystic implant; 1B. Special perforator; 1C. Pawar's intracystic implant introducer

Special perforator

It is specially made for the purpose of making an ostium in the lacrimal fossa during implant DCR surgery (figure 1B). It made up of stainless steel, having sturdy and stout handle and shaft having sharp tip for making 3 mm perforation in the lacrimal fossa.

Implant introducer

It is specially designed for introducing implant into either newly fashioned nasal ostium or in NLD (figure 1C). It has handle and blunt shaft where implant is mounted for placement. Both special perforator and implant introduced are made by G Surgiwear limited, Uttar Pradesh, India.

Surgical techniques

Conventional DCR

A 12-14 mm long curved skin incision was made 3 mm medial to the inner canthus. Blunt dissection was done to separate the orbicularis muscle fibers. Medial canthal ligament was cut. After exposing the anterior lacrimal crest, the periosteum was incised with periosteal elevator.

With a blunt dissection, the sac was separated from the lacrimal fossa and reflected on the lateral side. The lacrimal bone was fractured with the small end of blunt dissector. Then avoiding the nasal mucosal damage, the bone was punched out and 12x14 mm bony opening was made. Sac was opened to create anterior and posterior flaps. Nasal mucosal flaps were designed in similar fashion. The posterior flaps of the nasal mucosa and the lacrimal sac were sutured using 6-0 chromic catgut and so were the anterior flaps. Wound was closed in layers with interrupted sutures by same chromic catgut suture.

Pawar's intracystic implant DCR

A 5-6 mm long curved incision was made 3 mm medial to the inner canthus. Exposure of the sac was done without cutting medial canthal ligament. A full thickness 4 mm long incision was made on anterolateral wall of sac using 11 number surgical blades. Sac cavity was irrigated with saline and 5% Providone solution. An ostium was created, using a special perforator, in the lower part of lacrimal fossa. The perforator is passed through posteromedial wall of sac, lacrimal bone and nasal mucosa to make a passage in the middle meatus of nose. The tip of special perforator points towards posteromedial and lower direction in relation to the sac. A sterilized Pawar's intracystic implant was introduced through this newly fashioned ostium with a special introducer (Figure 2). The wider portion (collar) lies on the sac cavity and other end in the middle meatus of the nose. The introduced implant is irrigated with normal saline and 5% Providone iodine solution. Syringing was done to confirm patency. The wound was closed in layers using 6-0 chromic catgut suture.

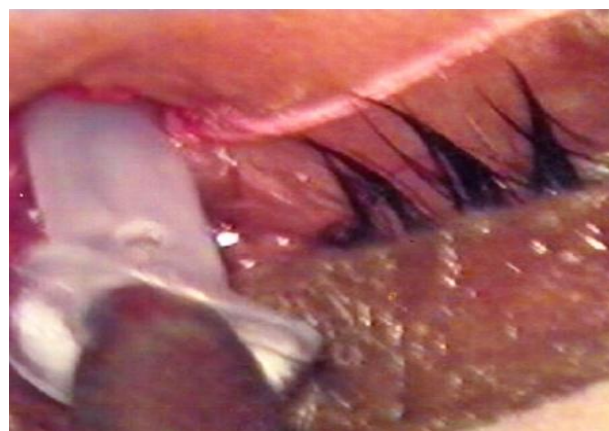

Figure 2: Placement of implant inside newly formed lacrimal bony ostium

Intra-operative bleeding was graded as: Grade I upto 5 ml, Grade II 6-10 ml, and Grade III more than 10 ml. Failed case of Pawar's implant DCR (of Group A) counted as a new case in Group B if conventional DCR was performed.

All the patients were received oral Amoxicillin and Cloxacillin 500 mg four times a day and non-steroidal anti-inflammatory drugs like Diclofenac 50 mg plus Serratiopeptidase 10 mg thrice a day for five days. Patients also prescribed Ciprofloxacin 0.3% four times a day in conjunctival cul-de sac and nasal drops Zylometazoline 0.1% twice a day for a period of one month. Postoperative syringing by normal saline was done on post operative day 3, 7 and 15 and then every month for 3 months then and every 3 months to assess anatomical outcome. During follow-up visits patients were specifically asked about epiphora to assess functional outcome.

Clinical success was defined as patent lacrimal system on irrigation with normal saline mixed with antibiotics (objective) and absence of symptoms (subjective).

Results

Age distribution

In present study, the youngest patient was 9 year and oldest was 75 year old. The maximum no (30%) of cases belongs to 4th decade of life.

Gender

Out of 50 cases 40 (80%) were female and 10 cases (20%) were males.

Laterality

Out of 50 cases, the right eye was operated in 22 cases (44%) and the left eye was operated in 28 cases (56%).

Socio-economic status

In our study we found that maximum number of cases reported from lower socio-economic status e.g. 41 cases (82%).

Mode of presentation

Majority of patients, 31 cases (62%) presented to us with complaints of epiphora alone or epiphora with fistula and swelling in sac area in 19 cases (38%).

Diagnosis

In this study, 39 (78%) cases had chronic dacryocystitis, 5 (10%) had pyoceles/mucocele, 3 (6%) had chronic dacryocystitis with lacrimal fistula and 3 (6%) had previous failed DCR surgery.

Intraoperative complications

We found that hemorrhage from nasal mucosa was observed in 9 cases (45%) during conventional DCR surgery and one case (3.33%) in implant DCR. Hemorrhage from angular vein occurred in one case (5%) during conventional DCR. Nasal mucosa was disrupted/damage in 8 cases (40%) during conventional DCR. None of patient experienced disruption of nasal mucosa and hemorrhage from angular during implant DCR surgery.

Operating time

The average operating time in convention DCR surgery is 110.50 minutes while for implant DCR is 27.33 minutes (Table No. 1).

Table 1: Showing comparison of intra-operative variables

Group	Nasal packing	Length of skin incision	Bleeding	M.C.L.	Size of ostium	Operative time
A	Not done	5-6 mm	+1	Not cut	3x3 mm	27.33 minutes
B	Done	12-14 mm	+2 to +3	Cut	12x14 mm	110.50 minutes

Hospital stay

Total hospital stay was 2-3 days in conventional DCR group and 1 day in Pawar's implant DCR group.

The commonest post-operative complication of implant DCR was obstruction of passage found in 4 cases (13.33%). On other hand, hypertrophic scar was the most common postoperative complication found in 8 cases (40%) in conventional DCR surgery (Table No 2).

Postoperative complications

Table 2: Postoperative complications in DCR surgery

S. No	Postoperative complication	Group A (Conventional DCR)		Group B (Implant DCR)	
		No of cases	%	No of cases	%
1	Lid odema	0	0	4	20
2	Incisional odema	2	6.66	6	30
3	Hemorrhage from nasal mucosa	0	0	2	10
4	Sac infection	1	1.33	0	0
5	Wound gape	0	0	1	5
6	Obstruction of passage	4	13.33	4	20
7	Hypertrophic scar	1	3.33	8	40
8	Extrusion of implant	1	3.33	0	0

Causes of failure of surgery

Out of 20 cases in conventional DCR surgeries 4 cases are failed due to various reasons (Table No. 3). Granulation tissue formation and scarring within rhinostomy accounted for 50% of cases (2 cases) of failure of conventional DCR. The remaining 50% were attributed to pseudo flap formation with lacrimal fascia (1 case)

and inadequate nasal ostium formation (1 case). Out of 30 case of Pawar's implant DCR surgery 5 cases (16.66%) failed due to mucoid plug formation 2 cases (40%), sac infection 1 case (20%), crust formation around the lower end of implant 1 case (20%), and extrusion of implant 1 case (20%).

Table 3: Showing causes of failure and Management of failed DCR cases

Group	No of failed cases	Cause of failure	Management failed cases	Outcome
A	2 (40%)	Mucous plug formation	Acetyl cysteine 2% eye drops+ modified syringing + lacrimal massage	Patent on syringing
	1 (20%)	Post operative sac infection and obstruction of implant	Local and systemic antibiotics and anti inflammatory drugs	Patent on syringing
	1 (20%)	Crust formation around lower end of implant	Diagnostics nasal endoscopy and crust removal + nasal decongestant drops	Patent on syringing
	1 (20%)	Extrusion of implant through skin opening	Re-implantation in NLD	Later on blocked & Dacryocystectomy done

B	2 (50%)	Granulation tissue formation	Implant DCR Done	Cases treated as Group A case
	1 (25%)	Inadequate nasal ostium	Implant DCR Done	Case treated as Group A case
	1 (25%)	Pseudo flap formation with lacrimal fascia	Re-fashioning of flaps	Patent on syringing

Success rate

In Group A, success rate at 2 months follow up was 83.33 % and at 3 month after management of failed cases of implant DCR was

96.66%. In Group B, success rate at 2 months was 80% and at the end of 3 months after management of failed cases of conventional DCR was 85% (Table No. 4).

Table 4: Showing Success Rate

Group	Success rate		'P' Value
	At two month before management of failed cases	At 3 months after management of failed cases	
A	83.33%	96.66%	>0.05
B	80%	85%	<0.05

Discussion

In this study, youngest patient was of 9 year old and eldest was 75 years old. The maximum no of cases belongs to 4th decade of life. Incidence of chronic dacryocystitis increases after 30 years of age.^[7] Duggal *et al* reported maximum incidence of chronic dacryocystitis in 5th to 6th decade of life.^[8] Saxena and Garg observed maximum age incidence in 4th decade of life.^[9] In our study maximum incidence of chronic dacryocystitis was found in females that is in 40 (80%) patients while 10 (20%) were males. Duggal *et al* found 88% chronic dacryocystitis incidence in females in their study.^[8] Duke-Elder mentioned 75% to 80% dacryocystitis incidence in females.^[10] It is said that this predilection for females is due to narrower lumen of bony lacrimal canal and high nasal index.

Out of 50 cases, right eye was affected in 22 cases (44%) and left eye was in 28 cases (56%). In our study there was no significant difference in side of affection. Dagleish reported that there was no significant differences in side of affection while incidence of bilaterality increases with age.^[11] Chronic dacryocystitis mainly affects poor socio-economic group. Duggal *et al* noted the majority of cases belong to poor socioeconomic status.^[8] In our study we found that maximum number (82%) of cases belongs to lower socio-economic status. Predilection of chronic dacryocystitis for lower socio-economic group seems to be due to poor personal hygiene and less access to the medical care. In present series 31 patients (62%) were having complaint of epiphora only. Complain of epiphora with purulent discharge was found in 8 (16%) cases, epiphora with painless sac swelling was noted in 5 (10%) cases and epiphora with previous DCR surgery was noted in 3 (6%) cases. Epiphora alone was the chief complaints in 60% of cases in Chaudhari A *et al* study.^[12]

Conventional DCR is relatively contraindicated in nasal problems like atrophic rhinitis, grossly deviated nasal septum and hypertrophied middle meatus, however implant DCR did not have such relative contraindications.^[13] Both conventional DCR and Pawar's implant DCR can be performed in local anesthesia.^[14]

In our study, nasal packing was done prior to surgery in all cases operated by conventional DCR technique but cases operated by Pawar's implant DCR were not received nasal packing. Nasal packing is essential for preventing intraoperative and postoperative nasal bleeding in conventional DCR because of larger ostium size.^[15] In Pawar's implant DCR, ostium size is comparatively small hence it doesn't requires nasal packing.^[14] In conventional DCR incision is 12-14 mm long and runs along the anterior

lacrimal creast. Long incision is necessary for better exposure to performed 10x12 mm osteotomy.^[16] In Pawar's implant DCR 5-6 mm incision is sufficient because size of ostium is 3 mm.^[5,17-18] In our series, medial palpebral ligament was not cut in Pawar's implant DCR so there was no anatomical disturbance, while in conventional DCR it was cut to get wider exposure to make large nasal ostium. To minimized anatomical disturbances, medial palpebral ligament was sutured in all cases during closure of the wound. Medial palpebral ligament disinsertion or cutting is not necessary in implant DCR while in conventional DCR if divided, it must be sutured to make intact lacrimal pump.^[14,15,19]

In conventional DCR, bleeding was grade 2 and grade 3. In Pawar's implant DCR, amount of bleeding was grade 1 is most of the cases. Amount of intraoperative bleeding is significantly less in Pawar's implant DCR in comparison to conventional DCR.^[6,18]

Mean operating time for Pawar's implant DCR was 27.33 minutes while 110.50 minutes in conventional DCR. Operating time for implant DCR is less because of less manipulation of structures, smaller bony ostium reconstruction, no suturing of mucosal flaps and less bleeding to handle.^[12] Conventional DCR is time consuming because of making large nasal ostium and handling severe bleeding during preparation and suturing of mucosal flaps. Chaudhari A *et al* reported operating time for conventional DCR 3 fold more than Pawar's implant DCR.^[12] The cases operated by Pawar's implant DCR have 1 day duration of hospitalization while cases operated by conventional DCR, were hospitalized for 2-3 days because of more chances of post operative bleeding.

Hemorrhage from nasal mucosa and disruption/damage of nasal mucosa are common intraoperative complications in conventional DCR. These intraoperative complication are minimal in Pawar's implant DCR because of minimal invasive nature of surgery.^[5,17] The commonest post-operative complication of Pawar's implant DCR was obstruction of passage of implant. Mucous plug formation inside the implant is the major cause of obstruction of Pawar's Implant. This complication can be managed easily with topical Acetylcysteine 5% eye drops instillation in conjunctival sac.^[20] Hypertrophic scar was the most common postoperative complication found in conventional DCR surgery. This is probably due to larger incision in comparison to Pawar's implant.^[4]

The most common cause of failure of Pawar's implant DCR was mucoid plug formation 2 cases (40%), followed by sac infection 1 case (20%), crust formation at lower end of implant 1 case (20%) and extrusion of implant through skin wound 1 case (20%) in our study. Similar observations have been made by Chaudhari A *et al*

and Pawar *et al* where mucoid plug formation was main cause of failure of implant DCR.^[12,20,21] We found granulation tissue formation and scarring within rhinostomy accounted for 2 cases (50%) of failure of conventional DCR. The remaining 50% were attributed to pseudoflap formation with lacrimal fascia and inadequate nasal ostium 1 case each. Granulation tissue formation and scarring within rhinostomy, and pseudoflap formation are major causes of failure of conventional DCR.^[22-25]

Success rate of Pawar's implant DCR at 2 months follow up was 83.33% and at the end of 3 months after management of failed cases of implant DCR was 96.66%. Success rate of conventional DCR at 2 months follow up was 80% and at the end of 3 months after management of failed cases of conventional DCR was 85%. Reported success rate of implant DCR is 80%-96%.^[4-6,12] There was no change in success rate during 1 year follow up.

Limitations of study

Small sample size and less follow-up is limitation of present study. There was longer surgical times in conventional DCR because of all surgeries were performed by post graduate student.

Conclusion

In this study we found advantage of implant DCR over conventional DCR as following- (1) nasal packing is not necessary, (2) It is a small incision lacrimal bypass surgery, (3) No need to cut medial palpebral ligament, (4) No need of creating sac and nasal mucosal flaps and anastomosis, (5) Easy and less time consuming, (6) Minimal intra- and post operative bleeding complication, (7) success rate is better than conventional DCR surgery.

References

- [1] Parson's Diseases of the Eye: Diseases of the Adnexa: 20th Ed. pp. 446-447
- [2] Harish V, Bengner RS. Origins of lacrimal surgery, and evolution of dacryocystorhinostomy to the present. Clin Exp Ophthalmol. 2014;42 (3):284-7.
- [3] Toti A. Nuovometodoconservatore di cura radical dellesuppurazioniconroniche. Clin Med 1904; 10:385
- [4] Reddy YM, Gupta VP, Redy SC. Silicone Implant Dacryocystorhinostomy- Study conducted at Kurnool Medical College and Regional Eye Hospital, Andhara Pradesh. Asian J Ophthalmol 2005;7(2):34-37
- [5] Pawar MD, Sutaria SN. Intracystic tubal implantation in DCR. Proceedings of Xth Congress of Asia Pacific Academy of Ophthalmology. New Delhi.1985. pp. 190-191.
- [6] Bhatt N, Trivedi N, Agarwal A. Comparison between conventional DCR surgery and Pawar's implant DCR. Proceedings of the 60th All India Ophthalmic Conference; 2002 January; Ahmdabad, New Delhi.
- [7] KATAVISTO M. On dacryostomies. Acta Ophthalmol (Copenh). 1957;35(5):491-504.
- [8] Duggal P, Chakravorty S, Azad RK, Mohan C. An epidemiological study on patients undergoing dacryocystorhinostomy. Indian J Otolaryngol Head Neck Surg. 2006;58(4):349-51.
- [9] Saxena RC, Garg KC. Scope of dacryocystorhinostomy. J All India Ophthalmol Soc. 1969;17(2):55-8.
- [10] DUKE-ELDER, S. (1952). "Text-book of Ophthalmology", vol. 5, p. 5300. Kimpton, London.
- [11] Dalgleish R. Incidence of idiopathic acquired obstructions in the lacrimal drainage apparatus. Br J Ophthalmol. 1964;48:373-6
- [12] Chaudhari A, Chaudhari P, Ahir HD. Study of comparison between dacryocystorhinostomy surgery with Pawar's implant and conventional dacryocystorhinostomy surgery. Natl J Med Res. 2012; 2(4):508-11
- [13] Gupta S, Mengi RK. Outcome of dacryocystorhinostomy with silicone intracystic implant in patients with chronic dacryocystitis. JK science 2013;15(4):181-184
- [14] Lele SS, Pawar MD, Sune PG. A comparative study between stent DCR and conventional DCR in the cases of blockage of nasolacrimal duct. Proceedings of the 60th All India Ophthalmic Conference; January 2002; Ahmadabad, Page no. 508-510.
- [15] Picó G. A modified technique of external dacryocystorhinostomy. Am J Ophthalmol. 1971;72 (4):679-90.
- [16] Cassady JR. A simplified dacryocystorhinostomy technique. Ophthalmic Surg. 1980;11 (5):319-22.
- [17] Pawar MD, Sutaria SN. Intra-cystic tube stentation in dacryocystorhinostomy. Proceedings of the Xth Congress of the Asia Pacific Academy of Ophthalmology; New Delhi: Asia Pacific academy of Ophthalmology; 1985.
- [18] Pawar MD, Patil SN. A new approach to stent dacryocystorhinostomy in cases with blockage of the lacrimal drainage system. Proceedings of the XXVth International Congress of Ophthalmology; May 1986; Milan, Italy: Kugler & Ghedini; 1987; 1882-1892.
- [19] Jawaheer L, MacEwen CJ, Anijeet D. Endonasal versus external dacryocystorhinostomy for nasolacrimal duct obstruction. Cochrane Database Syst Rev. 2017 Feb 24;2:CD007097
- [20] Pawar MD, Sune PG, Lele SS, Nagpure S, Dulani M, Gondhale M. Complications of stent DCR and its management. Proceedings of the 61st All India Ophthalmic Conference; January 2003; Ahmadabad, New Delhi: All India Ophthalmological Society; 2003; 547-549.
- [21] Pawar MD. Implant Dacryocystorhinostomy (DCR) using Modified Pawar Implant. J. Med. Sci. Clin. Res. 2015;3(2):4008-18
- [22] Welham RA, Henderson PH. Results of dacryocystorhinostomy Analysis of causes for failure. Trans Ophthalmol Soc U K. 1973;93:601-609
- [23] Malhotra R, Wright M, Olver JM. A consideration of the time taken to do dacryo-cystorhinostomy (DCR) surgery. Eye (Lond). 2003;17 (6):691-6.
- [24] Lin GC, Brook CD, Hatton MP, Metson R. Causes of dacryocystorhinostomy failure: External versus endoscopic approach. Am J Rhinol Allergy. 2017;31 (3):181-185.
- [25] Sullivan L, Fearnley T, Al-Maskari A, El-Hindy N, Kalantzis G, Chang BY. External dacryocystorhinostomy in consultants and fellows- a comparison of the causes of failure. Hippokratia. 2015;19 (3):216-8.

Address for Correspondence

Dr. S.C.L. Chandravanshi

Assistant professor

Department of Ophthalmology, Shyam Sah Medical College,
Rewa, M.P., India Pin 486001