

# Expression of Mesothelial Marker Calretinin in Breast Cancer

Dr. Kalathingal Kamarunisha Aboobacker<sup>\*1</sup>, Dr Prema Saldanha<sup>2</sup>



<sup>1</sup>Resident, <sup>2</sup>Professor,

Department of Pathology, Yenepoya Medical College, Mangalore, 575018, Karnataka, India

\*Address of Correspondence - [dr.nisha.k@gmail.com](mailto:dr.nisha.k@gmail.com)

## Abstract

Calretinin (CR) is a calcium binding protein of calmodulin superfamily, a widely used marker for mesothelial differentiation. It is also found to be expressed in breast carcinoma. Breast carcinoma is the leading cause of cancer death in women and despite new approaches and advances, it is still difficult to predict the behaviour of the tumour and its prognosis. So there is a need and struggle to identify new markers for prognosis of breast cancer. The study is aimed at evaluating the frequency of Calretinin expression in breast carcinoma and assessing the characteristics of Calretinin positive tumours. Thirty mastectomy specimen of invasive breast carcinoma were analysed histopathologically and for immunohistochemical expression of ER, PR, HER2/neu and Calretinin. In this study 93.33% (28 cases) were of invasive carcinoma, NST and 6.67% were of other subtypes. Patients less than 40 years of age showed low CR expression and patients over 40 showed high CR expression ( $p = 0.22$ ). Grade 3 tumours showed high CR, grades 1 and 2 showed low CR expression. Lymph node positive cases showed high CR and lymph node negative cases showed low CR. Tumours less than 5cms in size show low CR expression and those over 5cms showed high CR expression ( $p = 0.38$ ). Negative ER, PR and HER2/neu showed high CR expression. CR expression was high in 54.5% of basal-like subtype and 66.7% of HER2-enriched. CR expression was low in 50% of luminal cases. High Calretinin expression was seen in grade 3, HER2-enriched and basal-like subtypes of breast cancer which may be of considerable prognostic significance.

**Keywords:** Carcinoma breast, prognostic markers, Calretinin.

## Introduction

Breast cancer is found to be one of the leading cause of malignancy in females worldwide.<sup>[1]</sup> It is the most common malignant tumour and the leading cause of carcinoma death in women.<sup>[2]</sup> Globally the incidence of breast malignancy is more than 1million cases occurring annually.<sup>[3]</sup> Breast malignancy constitute one fourth of all cancers in females worldwide.<sup>[4]</sup>

It is a heterogenous disease with distinct entities, diverse clinical behaviour, presentation and separate clinical course and reaction to treatment. Several subtypes exist which are defined by means of genetic array testing or immunohistochemical analysis.<sup>[5]</sup> It is divided immunohistochemically in to distinct subtypes, luminal A, luminal B, HER2/neu, basal-like and "normal breast-like" by using a combination of oestrogen receptor (ER) and progesterone receptor (PR) markers and HER2/neu with or without the use of basal cytokeratins (CKs). Treatment of breast malignancy is based chiefly on clinicopathological characters such as tumour size, tumour grade, lymphnode status and ER, PR and HER2/neu hormone receptor expression

Inspite of these advances there is a continuous struggle to identify tumour characteristics that will better define diagnostic, predictive and prognostic factors.<sup>[6]</sup> New markers are required to substantiate

the origin of breast malignancy in case of metastasis and to plan contemporary therapies.<sup>[7]</sup>

Calretinin (CR), 29kd a cytosolic calcium binding protein of calmodulin super family is widely expressed in central and peripheral nervous system tissue, tendon fibroblasts, germinal epithelium of ovary, adrenal glands, leydig cells and thymus.<sup>[8]</sup> It acts as a diagnostic marker for malignant mesothelioma and Hirschsprung disease.<sup>[9,10]</sup> It is a known mesothelial marker expressed in both epithelial and mesenchymal malignancies including breast cancer.

The aim of this study is to evaluate the clinicopathological features and frequency of ER, PR HER2 and Calretinin expression in primary breast Carcinoma.

## Materials and Methods

This retrospective study was done on 30 paraffin embedded specimens of mastectomy confirmed to be breast carcinoma. Cases treated with Neoadjuvant therapy, no residual tumour on biopsy, male patients were excluded from the study.

The 30 cases were assessed according to age, location, size, multiplicity, histological type, histological grade according to the Nottingham modification of the Bloom-Richardson scoring system,

lymphovascular invasion, necrosis, metaplastic component, number of lymphnode metastases (N), distant metastasis (M), and TNM staging. Samples were retrieved from Pathology Department. Relevant patient history, findings and age was taken in to consideration. The specimens were fixed for 16 to 24 hrs in 10% formalin and grossed according to College of American Pathologist.

The tissue bits were processed using Leica TP1020 Semi-Enclosed Benchtop tissue Processor (Leica Biosystems, Wetzlar, Germany). The processed tissue was embedded in Surgipath Paraplast Paraffin (Leica Biosystems, Wetzlar, Germany). The blocks were cooled on a Histocore Arcadia C- cold Plate and thin sections 4µm were cut using Leica RM2245 Semi- Automated Rotary Microtome (Leica Biosystems, Wetzlar, Germany). These thin sections were stained with hematoxylin and Eosin on a Leica ST5010 Autostainer XL and mounted using DPX Mountant for histology. The histological typing of the tumour was done according to the current classification proposed by the World Health Organization (WHO) and grading of the tumour was assessed according to Nottingham modification which includes Bloom-Richardson scoring system which included tubular formation (1-3), nuclear atypia (1-3) and mitoses (1-3).

All 30 paraffin embedded tissue sections were subjected to immunohistochemistry using ER, PR, HER2/neu and Calretinin. ER (Estrogen Receptor- EP1 Rabbit Monoclonal Antibody Cat# PR042, Pathinsitu), PR (Progesterone Receptor- EP2 Rabbit Monoclonal Antibody Cat# PR068, Pathinsitu), HER2/erb2 (HER2/erb2 - EP3 Rabbit Monoclonal Antibody Cat# PR047, Pathinsitu) and Calretinin (Polyclonal, Pathinsitu) was used following the manufactures instructions. For IHC marker detection system polyexcel HRP (non-biotin, micro-polymer based) DAB detection system was used with adequate positive and negative controls.

Staining was assessed by two pathologists in a blinded fashion.

ER and PR stains were considered positive if expression was present in more than 1% of tumour nuclei according to American Society of Clinical Oncology (ASCO)/College of American Pathologists (CAP) guidelines and <1% were considered negative. Based on the immunohistochemical expression tumours were stratified into luminal, HER2-enriched and Basal-like.

HER2/neu staining was treated as negative with a score of 0 and +1 while it was treated positive with a score of +3 with complete membranous staining seen in at least 10% of neoplastic cells. Score of 2+ needed fluorescence in situ hybridization assay to prove HER2 amplification and they were thus eliminated from the study.

For Calretinin both nuclear staining and cytoplasmic staining were required to be considered positive staining. The combined score was used to assess the degree of immunoreactivity. The combined score consisted of percentage or distribution of positive tumour cells and intensity of staining. The percentage of positive tumour cells and intensity of staining are as described in Table 1. The complete overall score is secured by multiplying the percentage positive tumour cells and intensity of staining by Calretinin.

**Table 1: Showing percentage of positive tumour cells and intensity of staining by Calretinin**

Percentage of positive tumour cells	
0	0%
1	<25%
2	25-50%
3	>50%

Intensity of staining	
0	0
1	1+
2	2+
3	3+

**Table 2: Showing overall Calretinin score**

Overall Calretinin score	
Score 0	Negative
Score 1-2	Weak staining
Score 3-6	Moderate staining
Score 7-9	Strong staining

The overall staining was considered negative and positive as described in Table 2. The weak staining and negative staining was contemplated as low expression of Calretinin while strong and moderate staining were treated as high expression of Calretinin.

Depending on the immunohistochemical expression of ER, PR and HER2/neu tumours were classified as luminal, HER2-enriched (ER-,PR- and HER2/neu+) and Basal- like(ER-,PR-,HER2/neu-).

## Statistics

The data was entered into Microsoft Excel 2016 worksheets and then further statistical analysis was performed on IBM SPSS version 23. The data were statistically assessed using Chi square test of significance. The P- value <0.05 was considered statistically significant.

## Results

In the present study tumour characteristics were summarised as 93.33% (28 cases) of invasive carcinoma NST and 1 case of medullary carcinoma and 1 case of mucinous carcinoma. As regard to age the range was from 32 to 78years with mean age of 50. Most of the cases belonged to ≥40 years age group(n=26, 86.67%). High Calretinin expression were seen in 16cases and low calretinin expression were seen in 14 cases (p value = 0.22).

Out of the 28 cases of invasive breast carcinoma 53.6% cases had high Calretinin value while 46.4% of cases had low CR value( p value = 0.1).

Depending to the size of the tumour and extension the tumours were stratified in to four groups according to TNM staging. T1 group (≤ 2cm), T2 group (2-5cms), T3 group (≥5cms) and T4 group (tumours of any size with direct extension to chest wall and/or to skin). T1 and T2 were put in one group and T3 and T4 were clubbed in other group. T1 and T2 had 47.4% high CR and 52.6% low CR expression, while T3 and T4 had 36.4% low CR expression and 63.6% high CR expression (p value= 0.389).

Lymphnodes were positive in 19 cases of which 57.9% showed high CR value while 42.1% showed low CR value (p value= 0.51).

Tumours were graded into three groups. Group I consisted of grade I tumours which were 6 cases, group II consisted of grade 2 tumours 12 cases and group III consisted of grade 3 which were 12 cases. Grade 1 had 3 low CR and 3 high CR values. Grade 2 had 6 high CR and 6 low CR and grade 3 had 7 high CR (58.3%) and 5 low CR (41.7%) values (p value = 0.9).

As regards to ER, PR 16 cases (53.3%) were positive (table 3). Out of the 53.3% positive cases low CR and high CR were 50% each. While negative cases 57.1% showed high CR and 42.9% showed low CR (p value = 0.69).

As regards to HER2/neu 7 cases were positive for HER2 and rest 23 were negative. HER2/neu positive cases showed low CR (57.1%) and high CR (42.9%). While in case of negative HER2/neu 56.5% showed high CR value and 43.5% showed low CR value (p value = 0.52)

Luminal cases were 16 out of which 8 (50%) showed low CR and 8(50%) showed high CR (p value = 0.8).

HER2- enriched cases 66.7% showed high CR value and 33.3% showed low CR value (p value = 0.8).

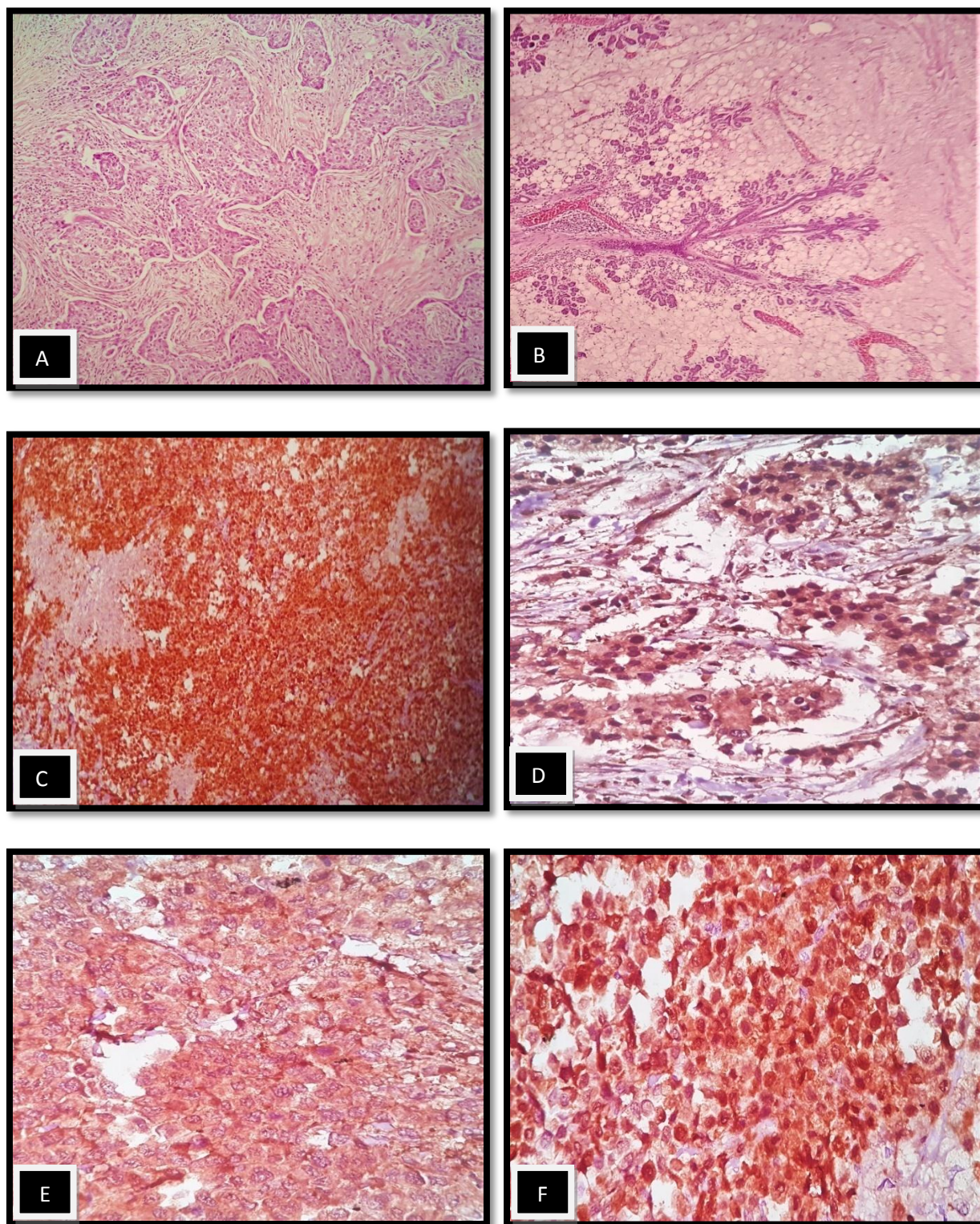
Triple negative or basal-like cases were 11 out of which 45.5% showed low CR and 54.5% showed high CR.

**Table 3: Correlation of clinicopathological, histological and immunohistochemical parameters and Calretinin expression**

Clinical and Histopathological Parameters	Calretinin Expression		Chi Square Test	P Value
	Low CR	High CR		
<b>AGE</b>				
<40	3 (75%)	1(25%)	1.489	0.22
≥40	11(42.3%)	15(57.7%)		
<b>TUMOUR SIZE</b>				
T1,T2	10(52.6%)	9(47.4%)	0.741	0.389
T3,T4	4(36.4%)	7(63.6%)		
<b>LYMPH NODE</b>				
Positive	8(42.1%)	11(57.9%)	0.433	0.510
Negative	6(54.5%)	5(45.5%)		
<b>HISTOLOGICAL TYPE</b>				
Invasive NST	13(46.4%)	15(53.6%)	0.01	0.92
Others	1(50%)	1(50%)		
<b>HISTOLOGIC GRADE</b>				
Grade I	3(50%)	3(50%)	0.201	0.904
Grade II	6(50%)	6(50%)		
Grade III	5(41.7%)	7(58.3%)		
<b>ER</b>				
Negative	6(42.9%)	8(57.1%)	0.153	0.69
Positive	8(50%)	8(50%)		
<b>PR</b>				
Positive	8(50%)	8(50%)	0.153	0.69
Negative	6(42.9%)	8(57.1%)		
<b>HER2/neu</b>				
Positive	4(57.1%)	3(42.9%)	0.4	0.526
Negative	10(43.5%)	13(56.5%)		

**Table 4: Calretinin expression in molecular subtypes of breast carcinoma**

Molecular Subtype	Calretinin Expression		Total Cases	Chi Square	P Value
	Low CR	High CR			
Luminal	8(50%)	8(50%)	16	0.292	0.864
HER2-enriched	1(33.3%)	2(66.67%)	3		
Basal-like	5(45.5%)	6(54.5%)	11		



**Figure 1:** Calretinin expression in carcinoma breast. A. Invasive ductal carcinoma of NST (X400). B. Negative CR staining in nonneoplastic breast tissue (X400). C Strong intensity of CR staining seen in breast Carcinoma (X400). D. Showing CR Nuclear staining (X400). E. Showing CR cytoplasmic staining (X400). F. Nuclear and cytoplasmic CR staining (X400).

## Discussion

Calretinin is a useful marker for the diagnosis of malignant mesothelioma and it is found to be a robust marker to make a distinction between malignant mesothelioma and adenocarcinoma.<sup>[11,12,13]</sup> Multiple functional roles of Calretinin include intracellular calcium buffering and message targeting. Management of breast cancer is based on clinicopathologic features such as

tumour morphology, lymph node status and assessment of expression of hormone receptors (ER, PR, human epidermal growth factor receptor - 2 (HER2)).

Few studies have been conducted on the non lung adenocarcinoma<sup>[13,14]</sup> and more so on the expression of Calretinin in breast cancer. The present study determined the expression of Calretinin in invasive breast carcinoma. High CR expression was

seen in 53.6% (15) cases and low CR was seen in 46.4% (13) cases. This is comparable to study done by Duhig et al<sup>[15]</sup> which showed high CR in 73% of cases. While studies conducted by Farrag et al<sup>[7]</sup>, and Taliano et al<sup>[6]</sup> reported showed low CR in 65.2% and 69% respectively. Figure 1 shows calretinin staining pattern in malignant breast tissue.

High CR expression was seen in grade 3 tumours (58.3%, 7cases) which was similar to studies conducted by Farrag et al<sup>[7]</sup>, Duhig et al<sup>[12]</sup> and Taliano et al<sup>[6]</sup> which noted high CR of 77.3%, 52.8% and 53% respectively.

In the present study Luminal tumours showed high CR expression (50%). Studies by Farrag et al<sup>[7]</sup> and Taliano et al<sup>[6]</sup> showed luminal A with low CR of 90.5%, and 88.9% respectively and Luminal B tumours showed low CR 66.7% and 87.3% respectively.

Triple negative tumours showed high CR (54.5%) in the present study very much like the studies done by Farrag et al<sup>[7]</sup> (70%), Duhig et al<sup>[15]</sup> (73.9%), Powel et al<sup>[16]</sup> (80%) and Taliano et al<sup>[6]</sup> (54.3%).

HER2-enriched cases showed high CR (66.7%) in the present study which was similar to study conducted by Farrag et al<sup>[7]</sup> While study done by Taliano et al<sup>[6]</sup> showed low CR (66.7%).

Calretinin expression was not recognised in normal breast tissue.

Molecular classification of breast carcinomas in this study included luminal (53%) 16 cases, HER2-enriched (10%) 3 cases and triple negative (37%) 11 cases (Table 4). These findings were comparable to studies done by Faraag et al<sup>[7]</sup> and El-Hawary.<sup>[17]</sup> Study conducted by Faraag et al<sup>[7]</sup> reported luminal A (37.7%), Luminal B (20%), HER2-enriched (12%), basal-like subtype (17.8%) and triple negative (30.7%). Similar findings were revealed in study done by El-Hawary et al<sup>[17]</sup> with luminal A (41.2%), Luminal B (13.9%), HER2-enriched (19.4%) and triple negative (28.5%).

Calretinin expression was analysed with respect to the molecular subtype of breast cancers with high CR expression was seen in luminal (50%), HER2 enriched (66.67%) and Basal like type (54.5%). Study conducted by Faraag et al<sup>[7]</sup> showed high CR expression in HER2-enriched (59.3%) and basal like type (70%). Low CR expression was reported in Luminal A (90.5%) and Luminal B (66.67%) types according to the study. In the present study high CR expression was seen in Basal like type of breast cancer which was similar to studies conducted by Faraag et al<sup>[7]</sup> (70%) and Taliano et al<sup>[6]</sup> (53%).

## Conclusion

In our study Calretinin was expressed in different molecular subtypes of breast carcinoma. High CR was seen in grade 3, HER2-enriched and basal like subtypes of breast carcinoma. Tumours less than 5cms in size show low CR expression and those over 5cms showed high CR expression. Negative ER, PR showed high CR expression, positive HER2/neu showed 57% low CR. Thus high percentage of breast carcinomas show Calretinin expression with high CR was seen in grade 3, HER2-enriched and

basal like subtypes of breast cancer which may be of considerable prognostic significance.

## References

- [1] Jemal A, Bray F, Center MM, Ferlay J, Ward E, Forman D. Global cancer statistics. *CA Cancer J Clin* 2011; 61: 69-90.
- [2] Weigelt B, Geyer FC, Reis-Filho J S. Histological types of breast cancer: How special are they? *Mol Cell* 2010; 4: 192-208.
- [3] Makki J. Diversity of Breast Carcinoma: Histological Subtypes and Clinical Relevance. *Clin Med Insights Pathol* 2015; 8: 23-31.
- [4] Lakhani SR, Ellis IO, Schnitt SJ, Tan PH, Van de Vijver MJ. WHO Classification of Tumours of the Breast. Fourth ed. IARC; Lyon: 2012.
- [5] Inwald E C, Schalke M K, Hofstadler F. Ki-67 is a prognostic parameter in breast cancer patients. Results of a large population based cohort of a cancer registry. *Breast Cancer Res Treat* 2013; 139:539-52.
- [6] Taliano RJ, Lu S, Singh K, Mangray S, Tavares R, Noble L et al. Calretinin [expression in high-grade invasive ductal carcinoma of the breast is associated with basal-like subtype and unfavorable prognosis. *Hum Pathol* 2013; 44: 2743-50.
- [7] Farrag MS, El-karef AA, Amin MM, Helal NM, Ali OF, Farrag NS. Calretinin expression as a reliable prognostic marker in different molecular subtypes of breast carcinoma. *Indian J Pathol Microbiol* 2017;60:8-14
- [8] Lugli A, Forster Y, Haas P, Nocito A, Bucher C, Bissig H et al. Calretinin Expression in Human Normal and Neoplastic Tissues: A Tissue Microarray Analysis on 5233 Tissue Samples. *Hum Pathol* 2003;34:994-1000
- [9] Kiraly E, Gotzos V, Celio MR. In vitro detection of Calretinin immunoreactivity in chicken embryo dorsal root ganglion neurons: a possible developmental marker. *Brain Res Dev Brain Res* 1993; 76:260-3.
- [10] Alexandrescu S, Rosenberg H, Tatevian N. Role of calretinin immunohistochemical stain in evaluation of Hirschsprung disease: an institutional experience. *International Journal of Clinical and Experimental Pathology* 2013; 6: 2955-61.
- [11] Gotzos V, Vogt P, Celio, M. R. The calcium binding protein calretinin is a selective marker for malignant pleural mesotheliomas of the epithelial type. *Pathology, Research and Practice* 1996; 192: 137-47.
- [12] Doglioni C, Deitos AP, Laurino L, Luzzolno P, Charelli C, Celio MR. Calretinin: a novel immunocytochemical marker for mesothelioma. *Am J Surg Pathol* 1996; 20: 1037-46
- [13] Ordonez NG. Value of Calretinin immunostaining in differentiating epithelial mesothelioma from lung adenocarcinoma. *Mod Pathol* 1998; 11: 929-33.
- [14] Cathro HP, Stoler MH. The utility of Calretinin, inhibin and WT1 immunohistochemical staining in the differential diagnosis of ovarian tumours. *Hum Pathol* 2005;36:195-201.
- [15] Duhig EE, Kalpakos L, Yang IA, Clarke BE. Mesothelial markers in high grade breast carcinoma. *Histopathology* 2011;59: 957-64.

[16] Powell G, Roche H, Roche WR. Expression of Calretinin by breast carcinoma and the potential for misdiagnosis of mesothelioma .Histopathology 2011;59: 950-6

[17] El-Hawary AK, Abbas AS, Elsayed AA, Zalata KR. Molecular subtypes of breast carcinoma in Egyptian women: Clinicopathological features. Pathol Res Pract 2012; 208: 382-6