



27 Weeks Abdominal Pregnancy With Misdiagnosed at the First Center: A Case Report

Recep ERİN¹, Kadri TEZEL¹, Ahmed ISAK¹, Samira AHMED¹, Mustafa KUŞAK²

¹Mogadishu Somali-Turkey Recep Tayyip Erdoğan Education and Research Hospital, Department of Obstetrics and Gynecology

²Mogadishu Somali-Turkey Recep Tayyip Erdoğan Education and Research Hospital, Department of General Surgery

Address for Correspondence: Recep Erin, M.D.

University of Healthy Sciences, Trabzon Education and Research Hospital, Obstetrics and Gynecology 61040 TRABZON, TURKEY; Email: erinrecep@gmail.com

Received 06 August 2019;

Accepted 04 September 2019;

Published 26 September 2019

Abstract

Abdominal pregnancy is a potentially life threatening form of ectopic gestation and is seen in 1% of all ectopic pregnancies. It's a major cause of maternal morbidity and mortality and the potential mortality can be reduced seriously with early diagnosis and treatment. It is rarely seen in advanced pregnancy weeks due to detectability on ultrasonography in early weeks. We aimed to present a rare, misdiagnosed, abdominal pregnancy. We present a case of 20 years old primigravida with 27 weeks abdominal pregnancy who presented at the emergency room with abdominal pain and minimal vaginal bleeding. She was referred from another hospital after 2 days failed induction for incorrect diagnosis of intrauterine dead fetus. The ultrasonography was performed and seen a normal uterus with no intrauterine pregnancy but seen a single extra uterine fetus with 27 weeks gestational age lying in the peritoneal cavity on the right side. We managed successfully with laparotomy. Abdominal pregnancy is rare, and successful management depends on a high index of suspicion. Ultrasonography and serial human chorionic gonadotrophin may help in the diagnosis. Teamwork, a multidisciplinary approach and expert opinion cannot be overemphasised to ensure successful management of these cases.

Keywords: *Abdominal ectopic pregnancy, human chorionic gonadotropin, ultrasonography, surgical treatment*

Introduction

Abdominal (peritoneal) ectopic pregnancy, defined as ectopic pregnancy occurring within the peritoneal cavity outside genital organs (uterus, tubes, ovaries), represents a very rare form of ectopic pregnancy. Of note, abdominal ectopic pregnancy is the only form of ectopic pregnancy that can result in a delivery of a healthy full-term baby. The incidence of abdominal pregnancy differs in various publications and ranges between 1:10.000 and 1:30.000 pregnancies. It was first reported in 1708 as an autopsy finding and a number of cases have been reported worldwide with varying presentations^[1]. Abdominal pregnancy has a maternal mortality rate between 0.5 and 18% and a perinatal mortality rate between 40 and 95%^[2,3]. We present a case report of a 20-year-old primigravida with 27 weeks of ectopic abdominal pregnancy managed successfully with operation.

Case report

A 20 year-old primigravida with a history of 27 weeks amenorrhea presented with pain in the abdomen and little vaginal bleeding

since 2 days. There was no surgical history and her consciousness was normal. The patient who lived rural area had not been followed during pregnancy. She was referred from another hospital to our hospital. On examination abdomen was unusually tense and tender. There was pain on the left side of the abdomen and severe tenderness on the right side of the abdomen. The patient's vital signs were normal. It was measured that human chorionic gonadotropin (hCG) was 4705 IU the other laboratory values were normal. The transvaginal ultrasonography (USG) was performed and seen a normal uterus with no intrauterine pregnancy but seen a single extra uterine fetus with 27 weeks gestational age lying in the peritoneal cavity on the right side (Image A). Fetal cardiac activity was not seen. Doppler USG showed blood flow in the upper part of the placenta and in the parts filling the pelvis. Uneffaced, undilated nulliparous cervix was revealed on pelvic examination. The same findings in CT (computerized tomography) were observed in laparotomy. Exploratory midline incision laparotomy was performed with the diagnosis of abdominal ectopic pregnancy. After opening the peritoneum, a dead fetus was seen lying on the right iliac fossa and placenta was seen in the left iliac fossa, it was adherent to upper uterine fundus, parts of omentum, sigmoid colon

and to the pelvic wall (Image B). Placenta was visualized in the left iliac fossa in computerized tomography (CT) (Image C). First the dead baby who estimated week was 26-27 weeks and weight was 780 grams was removed outside the abdomen (Image D) and then placenta was separated from all its attachments using electrosurgical instrument with general surgery doctor. Estimated blood loss was 750 cc. After bleeding control and homeostasis layers were closed anatomically. The patient was discharged from the hospital on preoperative 2nd day and she was clinically stable and the value of beta hCG was 51 IU.

Discussion

Abdominal pregnancies are those in which implantation occurs within the peritoneal cavity excluding tubal, ovarian or intraligamentous sites of implantation. Abdominal pregnancies are potentially life threatening with maternal mortality 7.7 times higher than that associated with intrauterine pregnancy. Viable, advanced abdominal pregnancies are very rare and only a few sporadic cases have been reported in the past 10 to 15 years^[6,7]. The incidence of abdominal pregnancy now appears to be increasing. In the developed countries due to increasing use of assisted reproductive technology^[8] and in the developing countries, particularly in rural areas presumably due to the restriction of human resources and diagnostic facilities and poor utilization of medical care by pregnant women. Our case lived in the rural area and she did not come to hospital regular.

This case was referred to our hospital after failed induction of labour for 2 days for wrong diagnosis of intrauterine dead fetus. As the diagnosis of abdominal pregnancy is often missed even with routine ultrasonography examination, every clinician should have a high index of suspicion for this condition. The reported diagnostic error rates in different series have ranged from 50 to 90%^[9]. The criteria used to diagnose a primary abdominal pregnancy were initially described by Studdiford^[10] in 1944. He stated the following criteria had to be met to classify a pregnancy as abdominal: (1) normal tubes and ovaries, (2) no evidence of uteroperitoneal fistula, (3) pregnancy related solely to the peritoneal surface, and (4) no evidence of secondary implantation following initial primary tubal nidation. Our case was primary abdominal pregnancy according to Studdiford criteria.

In a study of Worley KC et al including 10 case series, it included between 18 and 35 weeks of abdominal pregnancy, most of the diagnosis was made by emergency or elective laparotomy, most of the presented cases were ruptured tubal ectopic pregnancies and only 3 cases were consistent with primary

abdominal pregnancy definition^[11]. Hepatic localized pregnancies that complicated by acute hemoperitoneum that was treated with a laparoscopic approach have been reported in the literature^[12]. In a patient with amenorrhea, signs and symptoms such as abdominal pain, gastrointestinal disturbances, painful fetal movements, abnormal presentations, an effaced cervix, vaginal bleeding, and syncope should arouse suspicion of ectopic pregnancy especially abdominal.

A magnetic resonance and computerized tomography imaging scan can also be used to confirm the diagnosis of abdominal pregnancy. Laboratory tests, such as abnormally increasing human chorionic gonadotropin, are not sufficiently reliable on their own to make a diagnosis, nor are signs and symptoms such as abdominal pain and tenderness, persistent transverse or oblique lie, or palpable fetal parts. In our case, the only evidence of abdominal ectopic pregnancy was the findings of abdominal ultrasonography, abdominal pain and minimal vaginal bleeding. The most important factors that influence survival and management modality include maternal haemodynamic status and gestational age at time of presentation.

As with all types of ectopic pregnancy, medical management of abdominal pregnancy has been reported. Nonsurgical adjuvant or primary therapy included intramuscular methotrexate, intralesional methotrexate, intracardiac KCl, and artery embolization^[13]. Medical management is commonly used where potential life-threatening bleeding is anticipated, such as abdominal pregnancy of the liver, spleen and renal^[14].

Managing abdominal pregnancy surgically requires a great deal of surgical expertise and in most cases a multidisciplinary approach in anticipation of possible life-threatening bleeding during the operation. Historically, abdominal pregnancies were universally managed by laparotomy, however, Laparoscopy is feasible in selected cases and reported by more authors^[12,15]. Expectant management of second trimester abdominal pregnancy carries a risk of sudden life-threatening intra-abdominal bleeding and a generally poor fetal prognosis. Thus when recognised, immediate termination of pregnancy is recommended.

Whether the fetus is dead or alive, surgical intervention is generally advocated; there is a particular risk of infection and disseminated intravascular coagulation if the fetus is dead. Abdominal pregnancy is rare, and successful management depends on a high index of suspicion. While ultrasound and serial human chorionic gonadotrophin may help in the diagnosis, teamwork, a multidisciplinary approach and expert opinion ensure successful management of these cases.

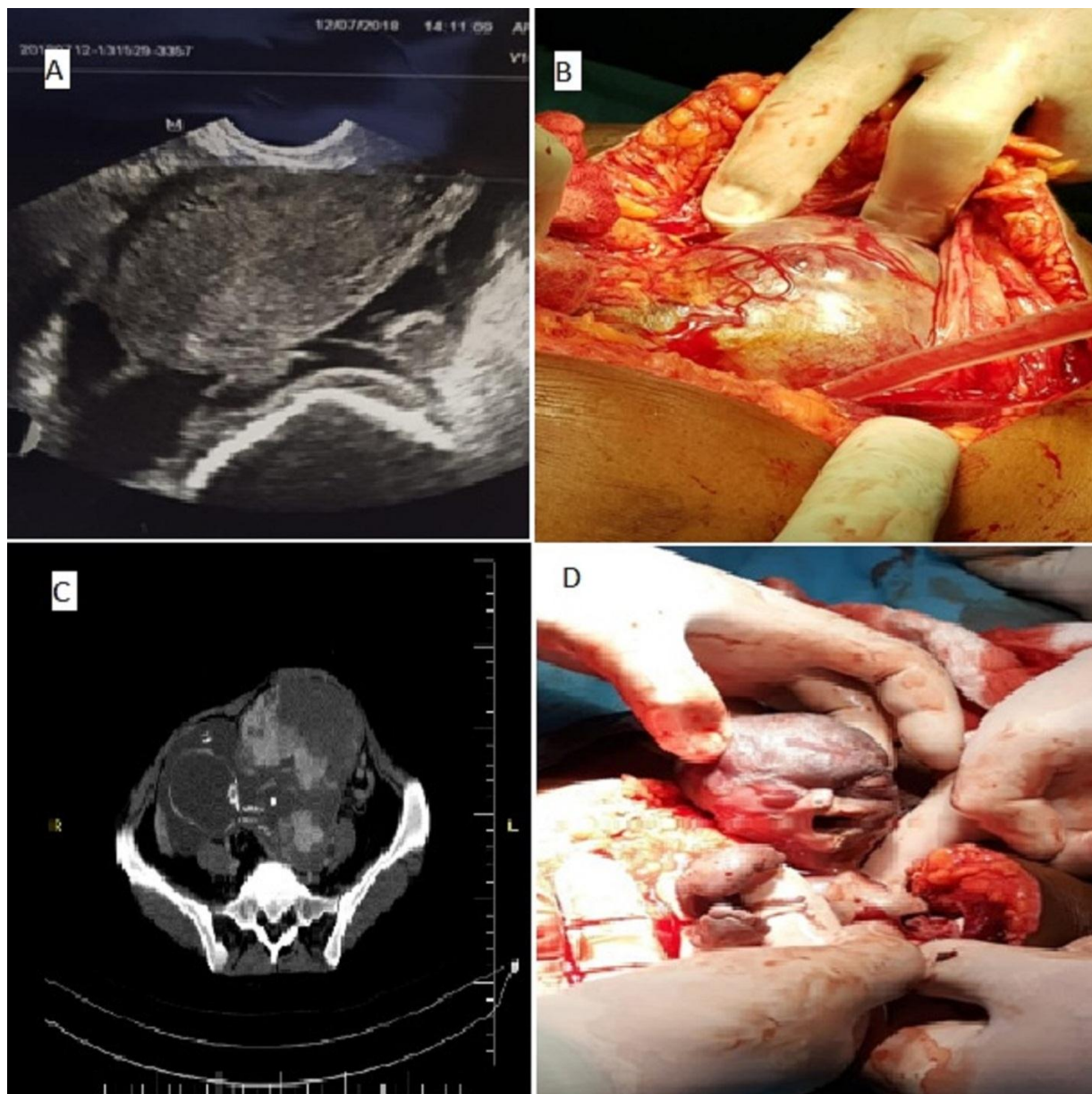


Figure 1: Image A shows the transvaginal ultrasound and the empty uterus in addition to ectopic pregnancy. Ultrasound, CT, and the two images of laparotomy

Declaration of patient consent

The authors certify that they have obtained patient consent form. In the form the patient has given her consent for her images and other clinical information to be reported in the journal. The patient understand that her name and initial will not be published and due efforts will be made to conceal her identity, but anonymity cannot be guaranteed.

Acknowledgment

Recep Erin; Manuscript writing and final revised manuscript, Kadri Tezel; Surgeon of the operation, Ahmed İsak; Manuscript writing, Samira Ahmed; Data collection, Mustafa Kuşak; Surgeon of the operation. All authors read and approved the final manuscript. No author has any financial conflict of interest to declare.

Financial support and sponsorship

There is no financial support and sponsorship

Conflicts of interest

www.ijirms.in

The authors have no any financial or commercial interests for this paper.

References

1. Baffoe P, Fofie C, Gandau BN. Term abdominal pregnancy with healthy new born: a case report. *Ghana Med J.* 2011;46(2):81–3. (PMID: 21857726)
2. Zhang J, Li F, Sheng Q. Full-term abdominal pregnancy: a case report and review of the literature. *Gynecol Obstet Invest.* 2008;65(2):139–41. (DOI: 10.1159/000110015).
3. Adesiyun AG, Audu AI. Term extrauterine pregnancy in a Nigerian mother: a complication of uterine dehiscence. *Arch Gynecol Obstet.* 2008;279(1):75–7. (DOI: 10.1007/s00404-008-0641-4)
4. Anderson PM, Opfer EK, Busch JM, Magann EF. An early abdominal wallectopic pregnancy successfully treated with ultrasound guided intralesiona methotrexate: a case report. *Obstetrics and Gynecology International. Obstet Gynecol Int.* 2009;2009:247452 (DOI: 10.1155/2009/247452)

5. Maas DA, Slabber CF. Diagnosis and treatment of advanced extra-uterin pregnancy. *S Afr Med J* 1975;49:2007–10.(PMID: 1198234)
6. Atrash HK, Friede A, Hogue CJ: Abdominal pregnancy in the United States: frequency and maternal mortality. *Obstet Gynecol* 1987; 69: 333–337. (PMID: 3822281)
7. Pannu D, Bharti R, Anand HP, Sharma M. Term Live Secondary Abdominal Pregnancy: A Case Report. *Malays J Med Sci.* 2016 Sep;23(5):96-99. PMID:27904431
8. Yanaihara A, Ohgi S, Motomura K, Hagiwara Y, Mogami T, Saito K et al. An abdominal ectopic pregnancy following a frozen-thawed ART cycle: a case report and review of the literature. *BMC Pregnancy Childbirth.* 2017 Apr 7;17(1):108. doi: 10.1186/s12884-017-1294-8.
9. Allibone GW, Fagan CJ, Porter SC: The sonographic features of intra-abdominal pregnancy. *J Clin Ultrasound* 1981; 9: 383–387. (PMID:6792237)
10. Studdiford WE: Primary peritoneal pregnancy. *Am J Obstet Gynecol* 1942; 44: 487– 491. (DOI: [https://doi.org/10.1016/S0002-9378\(42\)90488-5](https://doi.org/10.1016/S0002-9378(42)90488-5))
11. Worley KC, Hnat MD, Cunningham FG. Advanced extrauterine pregnancy: diagnostic and therapeutic challenges. *Am J Obstet Gynecol.* 2008 Mar;198(3):297. PMID: 18313451
12. Garzon S, Raffaelli R, Montin U, Ghezzi F. Primary hepatic pregnancy: report of a case treated with laparoscopic approach and review of the literature. *Fertil Steril.* 2018 Oct;110(5):925-931.(PMID: 30316439)
13. Poole A, Haas D, Magann EF. *Gynecol Obstet Invest.* Early abdominal ectopic pregnancies: a systematic review of the literature. 2012;74(4):249-60. PMID: 23108297
14. Tse KY, Cheung VYT, Lam C, Lee EYP, Khong PL, Ngan HYS. Successful treatment of a pararenal pregnancy using high-dose methotrexate regimen: A case report. *J Reprod Med.* 2016 Nov-Dec;61(11-12):592-4.
15. Balmaceda JP, Bernardini L, Asch RH, Stone SC. Early primary abdominal pregnancy after in vitro fertilization and embryo transfer. *J Assist Reprod Genet.* 1993 May;10(4):317-20. (PMID: 8130441)