

Color Doppler Imaging and Glaucoma: Comparison of Doppler Waveform of Retrobulbar Vessels between a Glaucomatous Patient and a Healthy Subject

Alice Chandra Verticchio Vercellin^{*1}, Sara Lombardo¹, Carlo Alberto Cutolo², Carmine Tinelli³, Giovanni Milano¹

¹University Eye Clinic, Fondazione IRCCS Policlinico San Matteo, Pavia

²University Eye Clinic, DINO GMI, Genoa

³Clinical Epidemiology and Biometric Unit, Fondazione IRCCS Policlinico San Matteo, Pavia

Abstract:

Ocular blood flow abnormalities are believed to play an important role in the pathogenesis of primary open angle glaucoma (POAG). For this reason the Colour Doppler Imaging (CDI) evaluation of the retrobulbar vessels is used for research purposes to investigate the degree of these abnormalities and their role in the pathogenesis of PAOG. The most widely measured variables are peak systolic velocity (PSV), end-diastolic velocity (EDV) and resistivity index (RI) of the ophthalmic artery, central retinal artery, and short posterior ciliary arteries. According to a recent study that has found statistically significant differences in two variables measured in the ophthalmic artery, the early systolic acceleration (ESA) and the ratio between the mean velocities of the systolic and diastolic components (Sm/Dm), we present the CDI evaluation of a case of normal tension glaucoma (NTG) compared to a healthy subject. The values obtained are in agreement with the literature and all the measured velocities, except for the PSV and the RIs in the ophthalmic artery that were respectively reduced and increased as compared to the healthy volunteer. Moreover, ESA is reduced and Sm/Dm increased. Further studies are needed to evaluate the degree of the pathological alterations and their role in the progression of the optic nerve injury.

Keywords: - Normal tension Glaucoma, Color Doppler imaging, vascular alteration, retrobulbar vessels, velocity, resistivity.

Introduction

Primary open-angle glaucoma (PAOG) is one of the most prevalent causes of irreversible blindness in the industrialized world¹. The mainstay of current therapies has been to decrease the main modifiable risk factor: intra-ocular pressure (IOP). However, and despite significant decreases in IOP, there are significant number of patients that show signs of disease progression^{2,3}. The search for other risk factors has led to the identification of a number of vascular alterations in patients with glaucoma, especially the ones with an otherwise normal IOP (normal tension glaucoma or NTG). Patients with glaucoma have been found to have an increased incidence of peripheral vasospasms⁴, migraine⁵, systemic hypotension⁶ and silent organ ischemia⁷, in what has been suggested to be signals of a systemic vascular dysfunction.

As concern the ocular circulation, the colour Doppler imaging (CDI) is a non-invasive technique which allows a selective evaluation of the ophthalmic artery (OA), the central retinal artery (CRA) and short posterior ciliary arteries (SPCA). It does not require a pharmacological mydriasis and it can also be used if the dioptric media of the eyeball are not transparent. CDI evaluates the blood flow velocities of the retrobulbar vessels in terms of peak systolic

velocity (PSV), end-diastolic velocity (EDV) and resistivity index (RI). A lot of studies showed a decrease of PSV and of EDV and an increase of RI in glaucomatous patients compared to healthy volunteers⁸. However, as published in a more recent article, a statistically significant difference between glaucomatous patients and healthy volunteers results from the analysis of the waveform of OA (p-value <0.05)⁹. In particular the parameters evaluated were the early systolic acceleration (ESA) (i.e the slope of the fastest – moving portion of the systolic component) and the ratio between the mean velocities of the systolic and diastolic components (Sm/Dm) (Figure 1).

Materials and methods

CDI examination of retrobulbar vessels was performed on the right eye of two age-matched subjects: a patient with normal tension glaucoma (NTG) and a healthy subject, respectively.

The two subjects were interviewed to obtain the history of ophthalmic and systemic diseases and systemic medications. They underwent a complete eye examination which included uncorrected and best corrected visual acuity testing with Early Treatment Diabetic Retinopathy Study (ETDRS) charts, slit-lamp biomicroscopy, applanation tonometry,

gonioscopy and non-dilated fundus examination at the University Eye Clinic of the IRCCS Policlinico San Matteo, Pavia, Italy.

CDI evaluation of the OA, CRA and SPCA were then realized at the Radiology Institute of the same hospital, in both subjects by the same examiner using the CDI device Siemens Antares Stellar Plus (probe VFX 9-4 Mhz vascular linear array).

The CRA and its vein lie close together in the center of the optic nerve and cannot be measured separately with CDI. Correct identification of the CRA was suggested by a double waveform with a distinct pulsatile arterial waveform above the zero line and a gentle sinusoidal venous variation below the zero line. The nasal and temporal short posterior ciliary arteries (NSPCA and TSPCA) were located on both sides of the optic nerve and were measured at a position close to the optic nerve and as anterior as possible without receiving interference from the choroid. The measured waveforms represent the mass effect produced by a bundle of vessels, rather than from individual ciliary vessels as the individual

short posterior ciliary vessels cannot be distinguished by CDI. These arteries produce a more uniform arterial pulse without a detectable venous wave. The OA is located deeper in the orbit and by convention is measured on the nasal side immediately after it crosses the optic nerve. The Doppler waveform of all the retrobulbar vessels was analysed in order to obtain PSV, EDV, IR, ESA and Sm/Dm ratio. ImageJ v.1.46a software (National Institutes of Health, USA) has been used to obtain ESA and Sm/Dm ratio. Each subject was asked to refrain from smoking and caffeine intake for at least thirty minutes prior to CDI examination to minimize the influence of these substances on blood flow and CDI measurements were performed with the subject in the supine position after a resting period of at least 5 minutes.

Results

All the measured velocities, except for the PSV in OA, are reduced and the RIs are increased in the glaucomatous patient compared to the healthy subject. Moreover, ESA is reduced and Sm/Dm increased if compared to the healthy volunteer (Table 1).

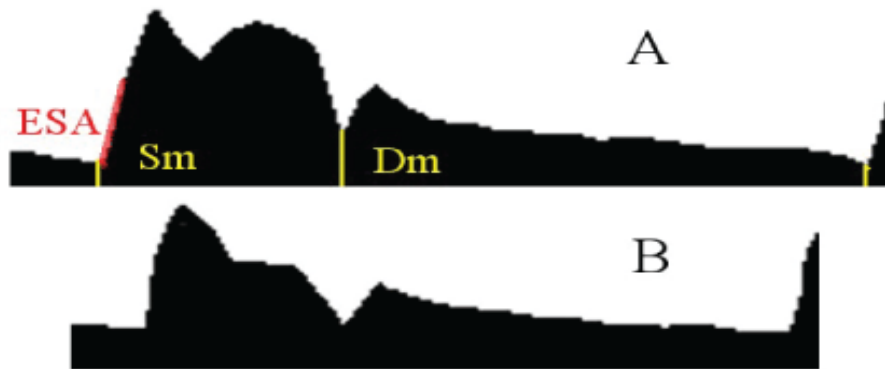


Figure 1 Comparison between the Doppler velocity spectral waveform in NTG patient (A) and in healthy volunteer (B)

Table 1. All the parameters of Doppler waveform in NTG patient and in healthy volunteer

Arameter	NTG patient	Healthy volunteer
OA PSV (cm/s)	31.1	28.6
OA EDV (cm/s)	6.2	9.6
OA RI	0.79	0.66
OA ESA	5.32	8.14
OA Sm/Dm	2.86	1.82
CRA PSV (cm/s)	9.6	11.7
CRA EDV (cm/s)	2.0	4.4
CRA RI	0.80	0.61
SPCA PSV (cm/s)	12.9	10.2
SPCA EDV (cm/s)	3.6	4.7
SPCA RI	0.73	0.53

Discussion

CDI is a technique widely used for the evaluation of ocular haemodynamic. A lot of studies have shown a statistically significant difference in the flow parameters in glaucomatous patients compared with healthy subjects. In particular, a decrease of the PSV and EDV and an increase in the RI in the retrobulbar vessels (OA; CRA; SPCA) in glaucomatous patients compared with healthy subjects have been demonstrated in all the studies. A more recently published article has analysed in details the waveform of the Doppler velocities and has shown a decrease of the ESA and an increase in the ratio Sm/Dm in glaucomatous patients. Vascular alterations have been demonstrated to be more important in the pathogenesis of NTG compared to the high-tension glaucoma where the causative role of a high IOP is predominant in the damage the optic nerve damage. All these observations have been confirmed in the NTG patient evaluated in this case report. The unique data in contrast with the literature is the PSV of OA, which is increased in the glaucomatous patient compared to the healthy one. Further studies with the aim to analyse the difference in the waveform of the retrobulbar vessels in patient with different types of glaucoma (NTG, High tension Glaucoma) and with ocular hypertension compared with healthy subject would be helpful to better understand the proportion of the vascular alterations and the importance of their role in the progression of the disease.

References

- [1] Kingman S. Glaucoma is the second leading cause of blindness globally. *Bull World Health Organ.* 2004; 82: 887-888.
- [2] Anderson DR. Normal Tension Glaucoma Study. Collaborative normal tension glaucoma study. *Curr Opin Ophthalmol.* 2003; 14: 86-90.
- [3] Leske MC, Heijl A, Hyman L, Bengtsson B, Komaroff E. Factors for progression and glaucoma treatment: the Early Manifest Glaucoma Trial. *Curr Opin Ophthalmol.* 2004; 15: 102-106.
- [4] Broadway DC, Drance SM. Glaucoma and vasospasm. *Br J Ophthalmol.* 1998; 82: 862-870.
- [5] Wang JJ, Mitchell P, Smith W. Is there an association between migraine headache and open angle glaucoma? Findings from the Blue Mountains Eye Study. *Ophthalmology.* 1997; 104: 1714-1719.
- [6] Hayreh SS, Podhajsky P, Zimmerman MB. Role of nocturnal arterial hypotension in optic nerve head ischemic disorders. *Ophthalmologica.* 1992; 2013: 76-96.
- [7] Stroman GA, Stewart WC, Golnik KC, Curé JK, Olinger RE. Magnetic resonance imaging in patients with low tension glaucoma. *Arch Ophthalmol.* 1995; 113: 168-172.
- [8] Stalmans I, Vandewalle E, Anderson DR et al. Use of colour doppler imaging in ocular blood flow research. *Acta Ophthalmol* 2011; 89:609-630.
- [9] Abegão Pinto L, Vandewalle F, De Clerck E et al. Ophthalmic artery doppler waveform changes associated with increased damage in glaucoma patients. *Invest Ophthalmol Vis Sci* 2012; 53:2448-2453.