



# Diaphragm Disease: A Paradox in the Intestine

Dr Ali Zaid Anwar, Dr Hemant M Jawale, Dr Akshat Mishra, Dr Rahul Mishra, Dr Shrinivas Ram

General Surgery Department, Grant Medical College and Sir JJ Group of Hospital, Mumbai

Corresponding author: Dr Hemant Jawale; [hjaware02@gmail.com](mailto:hjawale02@gmail.com)

Mailing address-room no 609, 300pg Hostel, Grant Medical College and SIR JJ Group of Hospital, MUMBAI 400008

Received 22 November 2019;

Accepted 05 December 2019;

Published 20 December 2019

## Abstract

Diaphragm disease is a paradoxical disease entity related entirely to the bowel and not having involvement of diaphragm muscles.

It is the formation of strictures in the bowel secondary to submucosal fibrosis which looks like the diaphragm and hence the term “Diaphragm disease”. It is seen in chronic NSAIDS (Non-steroidal anti-inflammatory drugs) users.

It is a rare entity, leading to intestinal obstruction as a severe complication. Diagnosis of diaphragm disease is a diagnosis of exclusion and mostly done intraoperatively in patients presenting with subacute intestinal obstruction because the symptoms are non-specific and no gold standard investigation is available to diagnose it. Grossly diaphragm disease is formation of strictures in the intestinal wall, leading to obstruction due to narrowing of the wall lumen.

Serendipitously stasis of food in the stricturous segment leads to formation of an enterolith, thus leading to subacute intestinal obstruction. A chance finding seen in chronic NSAIDS user’s is formation of enterolith secondary to stricture formation due to diaphragm disease leading to subacute intestinal obstruction.

**Keyword:** NSAIDS, Diaphragm Disease, small bowel segment

## Introduction

Non-steroidal anti-inflammatory drugs or NSAIDs are one of the most prescribed medication worldwide with Diclofenac sodium forming a major bulk of almost 21.5%.<sup>[1]</sup> Its mechanism of action is via a decrease in prostaglandin synthesis through inhibition of cyclooxygenase (COX).<sup>[2]</sup> But its effect on GI mucosa is due to direct toxicity rather than systemic COX inhibition<sup>[3]</sup>, leading to inflammatory changes related to bowel wall membrane damage through its effect on phospholipids along with generation of reactive oxygen species<sup>[4]</sup>. This results in chronic chain of insult and repair leading to circumferential strictures ala a diaphragm.<sup>[5]</sup>

Very rarely the formation of stricture leads to proximal stasis of intestinal content leading to formation of enterolith, which may lead to acute intestinal obstruction. Enterolith are of two types, true and false. True enterolith are formed by precipitation of alimentary chyme and false enterolith from indigestible material agglutination.<sup>[19]</sup>

It is a rare and chronic complication after prolonged use of NSAIDS, with non-specific complaints. Patient presents with chronic abdominal pain ranging from mild discomfort to severe obstruction necessitating operative management.

## Case History

Presenting here is a patient, a 60-year-old female with complaints of chronic pain abdomen, intermittent in nature with mild

discomfort affecting daily chores. The pain was non referred and non-radiating in nature and occurring diffusely over the entire abdomen. The pain was mildly relieved after over the counter usage of prescription pain killers.

There was no documented history of weight loss, hemoptysis, hematuria or hematochezia, icterus or a any discomfort in bowel movements.

The symptoms were intermittently present since 6 months and had aggravated since a week prior to admission.

The patient gave history of laparoscopic appendectomy done 1 year back.

She had history of chronic drug use of ibuprofen for bilateral knee joint pain intermittent in frequency since the last 6 years.

Patient had no other medical history of any chronic illness.

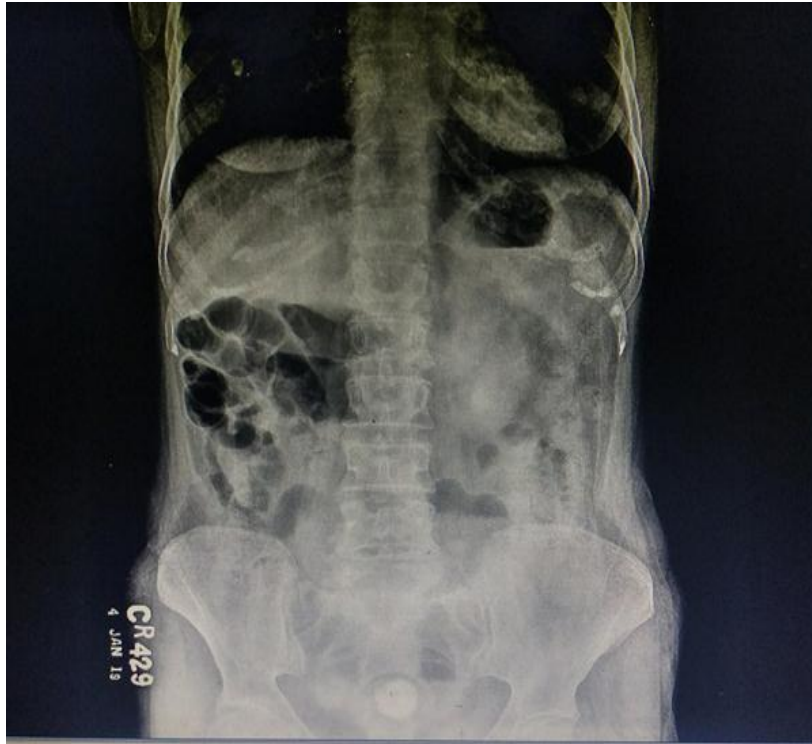Family history was unremarkable.

Clinically patient was vitally stable, on systemic examination, well healed scars of laparoscopic appendectomy were present; on palpation, tenderness was present over left iliac fossa and umbilical region but remaining abdomen was soft and there was no evidence of guarding or rigidity.

All routine investigations done.

Hb-8.4, WBC-7700 with normal renal and liver function with normal urine routine microscopy.

X-ray abdomen done-suggestive of coin shaped opacity in pelvis raising the suspicion of a bladder calculus.

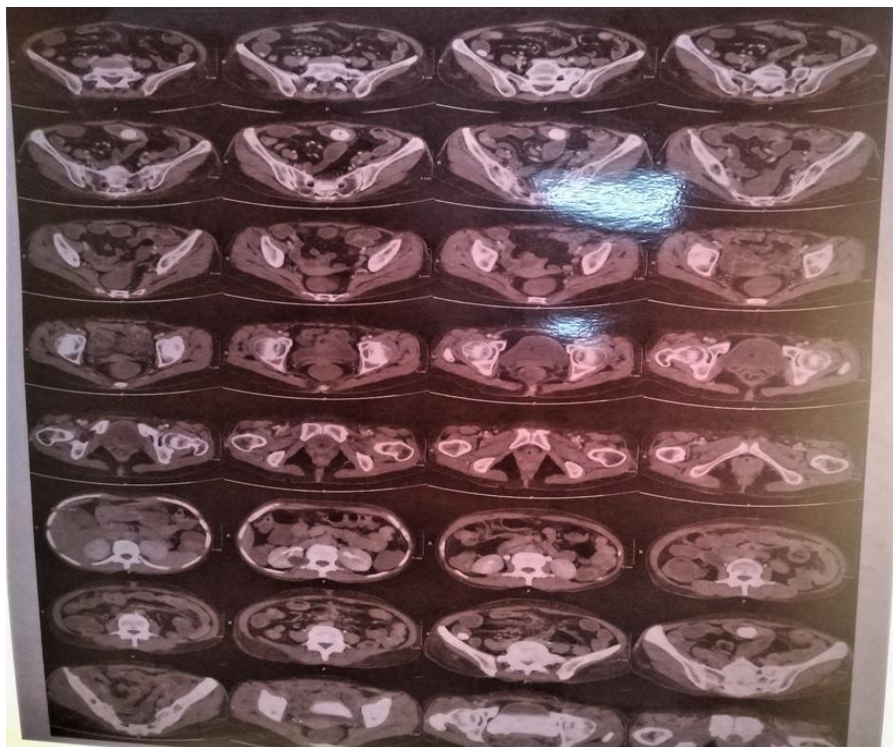


**Figure 1: X-ray abdomen erect showing coin shaped opacity in pelvis**

Ultrasonography of the abdomen and pelvis was done and remarkably there was no calculus in the bladder. Instead the radiologist remarked to rule out Koch's abdomen with suspicion of post-operative adhesions.

Erythrocyte sedimentation rate was 40mm after 1 hour and Mantoux test was negative.

Due to disparity between radiographic and sonographic finding and in view of persistent symptoms a contrast enhanced computed tomography of the abdomen and pelvis was done which was suggestive of Enterolith in ileum.

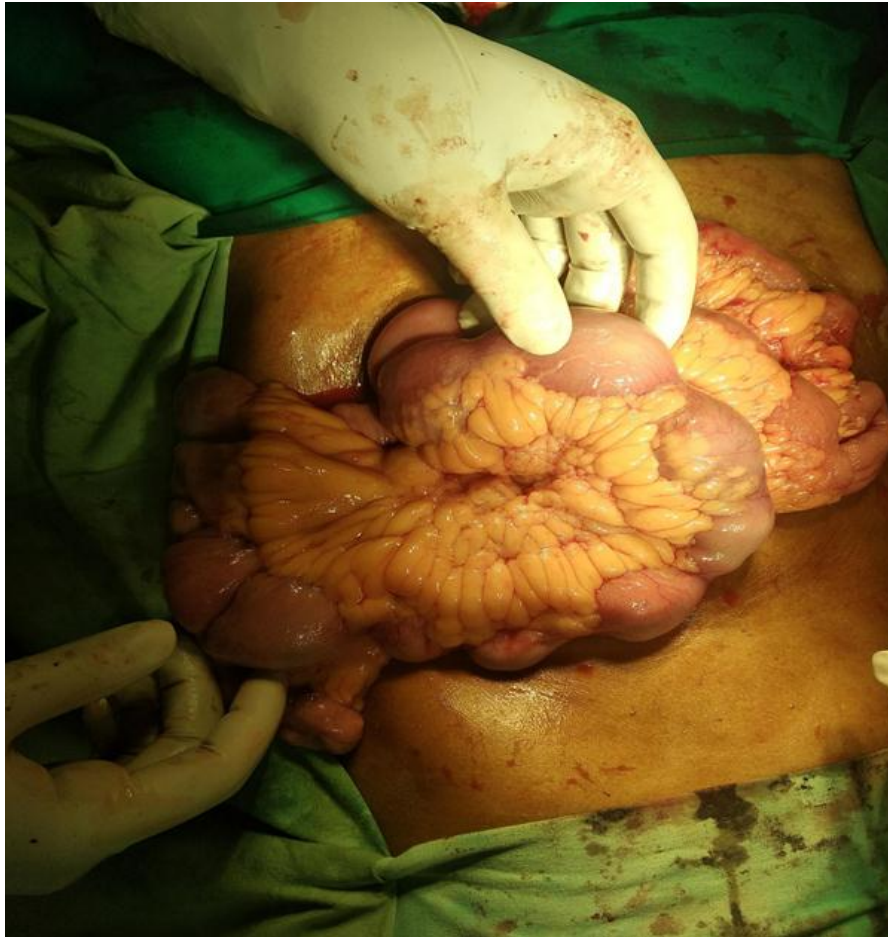

**Figure 2: Computed tomography film of abdomen showing calculi in small intestine (enterolith).**

Due to non-resolution of symptoms a diagnostic laparoscopy was decided to be performed on the patient.

As the diagnostic laparoscopy was suggestive of a large stricturous segment with proximal dilated bowel loops, exploratory

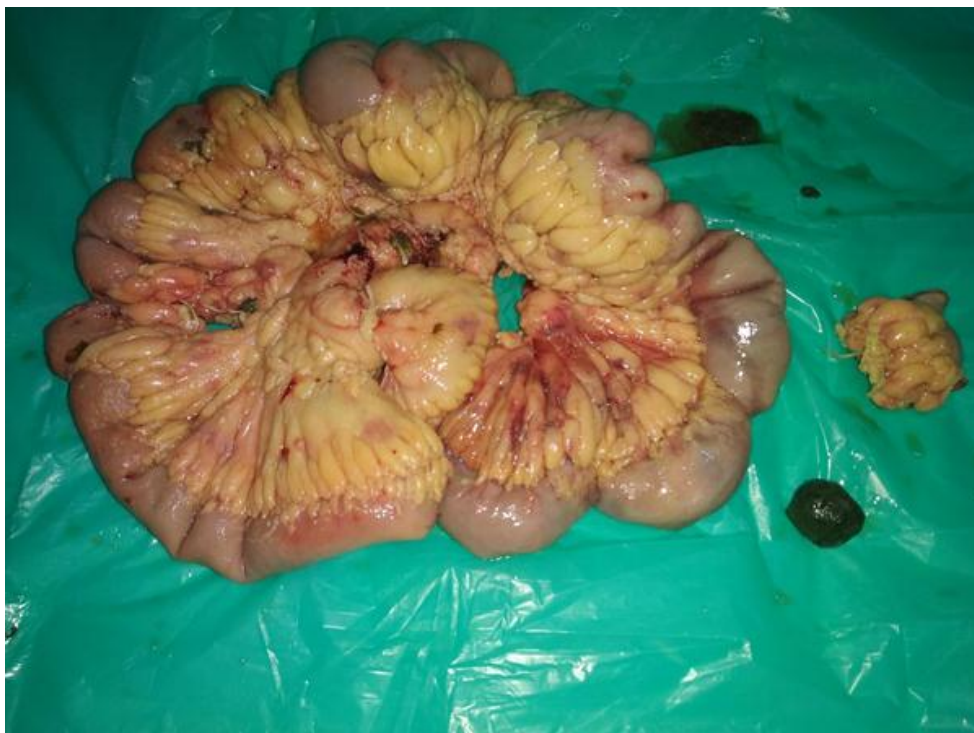laparotomy was done after an on-table decision. Intraoperative, multiple stenosing circumferential strictures were seen in mid ileum similar to those in diaphragm disease.



**Figure 3: Intraoperative strictures small bowel segment.**

Resection anastomosis of mid ileal segment was done and sample was sent for histopathology. One of the constricted segments had

an enterolith of 3.2cmx2.5cmx3 cm which was hard in consistency.

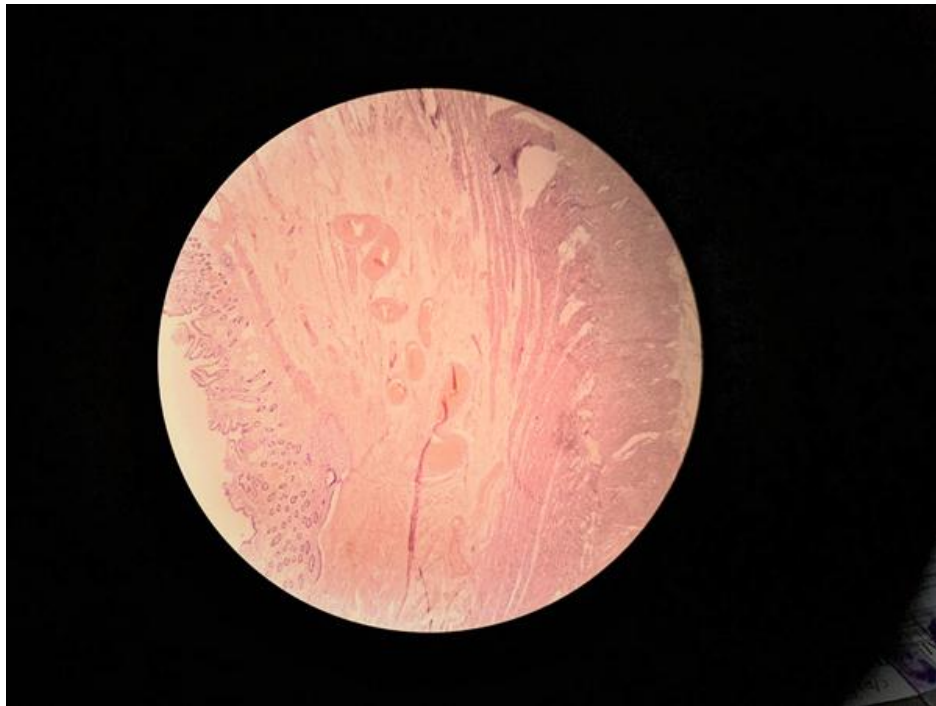

**Figure 4: Showing resected strictures small bowel segment with 3.2cm\*2.5cm\*3cm dimension grey coloured enterolith.**

Histopathology report was suggestive of inflammatory infiltrations present in the layers of intestine, mucosa ulcerated at some places, submucosa shows edema, congestion and haemorrhages and

transmural chronic inflammatory infiltrates up to muscularis propria and the serosa.





**Figure 6: Histopathology side of stricture segment showing inflammatory infiltrates in the mucosa, submucosa with oedema, congestion and haemorrhages.**

## Discussion

Diaphragm disease, first described by Lang et al. in 1988<sup>[6]</sup>, is a rare but an important cause of small bowel obstruction due to formation of multiple, thin, concentric diaphragms leading to narrowing of small bowel lumen.

In 1996 Debenham was the first person who demonstrated that Diaphragm disease was directly related to NSAIDs.<sup>[7]</sup>

Diaphragm disease has more female predilection and a large number of cases are seen in people of seventh decade.<sup>[8]</sup> The majority of these patients present with chronic symptoms of anaemia and abdominal pain.

NSAIDs are the most commonly used and prescribed drug world over with varying gastrointestinal side effects. The adverse effects of NSAIDs in the small bowel are the results of multiple mechanisms (microvascular injury, cyclooxygenase [COX] 1 and/or 2 inhibition, products of inflammatory cell infiltration, and expression of inducible nitric oxide synthase).<sup>[9]</sup>

Injuries are the result of local/direct contact and systemic effects. The current hypothesis states that NSAIDs cause initial reduction in villous microcirculation combined with inhibitory action on the cellular oxidative processes of the epithelial cells. These combine to induce increased permeability of the small intestinal mucosa. The injury is aggravated by prolonged exposure to the drug due to enterohepatic recirculation of at least some of the NSAIDs. Increased permeability allows luminal aggressors (indigenous enteric bacteria, their products, and bile) to gain access to the mucosa and cause inflammation with expression of inducible nitric oxide synthase.<sup>[10]</sup> Reactive oxygen species formation due to infiltration by neutrophils and production by injured endothelial cells is likely to bring about tissue injury. The NSAID COX-2 inhibitors have substantially reduced the propensity for injury of the small intestine, although they retain a component of side effects, including diaphragm formation.<sup>[11]</sup> The reason for the reduced toxic effects in the small bowel is not completely clear, although there is evidence to suggest that COX-1 products have a predominant role in the maintenance of the epithelial barrier integrity.<sup>[12]</sup> Diaphragm disease is an extremely rare occurrence in

NSAID users i.e. 2% of patients taking NSAIDs and COX-2 inhibitors long-term show this pathology. The route of ingestion of NSAIDs does not preclude the formation of diaphragms: It has been reported in a bypassed bowel segment, suggesting systemic effect of NSAIDs.<sup>[13]</sup> It is possible that the formation of diaphragms is a nonspecific response to various insults to the intestine.

Most cases are asymptomatic until they present with acute intestinal obstruction. Other presenting features are iron deficiency anemia, change in bowel habit or an acute abdomen secondary to perforation.

Subclinical degrees of small bowel injury can be detected using Indium111-labelled leukocyte scanning. Barium studies are inadequate as these lesions can easily be missed.<sup>[14]</sup>

The definitive diagnosis is usually made intra operatively, after an exhaustive work-up has failed to diagnose the condition. The concentric serosal bands which are present due to the appearance, makes the diagnosis more difficult. A gentle and careful palpation of the bowel segment can aid in diagnosing this entity and sometimes enteroscopy can be helpful.

Radiological diagnosis is difficult as diaphragms tend to be thin and do not distort the bowel wall. Small bowel studies with luminal contrast are neither sensitive nor specific for detecting intestinal diaphragms<sup>[15]</sup>. Capsule endoscopy can be helpful to know and compare the adverse effects of chronic NSAIDs use leading to damage of the small bowel mucosa but its use is limited in cases where there is a stricture formation limiting its movement.<sup>[16]</sup>

Due to extreme difficulty and feasibility in diagnosing the condition clinically or radiographically, the need for operative diagnostic laparoscopy or an open laparotomy, acting as both diagnostic and curative strategy is ideal if this diagnosis is suspected.<sup>[17]</sup>

On histopathology, the findings in this case are consistent with that of chronic inflammation extending to all layers of the gut with additional but not exclusive changes such as villous atrophy, eosinophilic enteritis and inflammatory fibroid polyp.<sup>[18]</sup>

## Conclusion

Small bowel diaphragm disease may be considered as a differential diagnosis in patients of chronic abdominal pain with history of NSAIDs use for a long time and radiological evidence of intestinal obstruction. This may be superadded by the fact that an enterolith may be the possible reason for the ongoing obstruction. This condition is ameliorated by a need for surgical intervention as the presenting complaints and potential investigations to diagnose it are neither reliable nor confirmatory.

## Conflict of interest

No financial and non-financial

## References

- [1] Prescribing patterns of non-steroidal anti-inflammatory drugs (NSAIDs) at outpatient departments of four hospitals. *Biomedical Research* (2018) Volume 29, Issue 19. Mohammed A Alshakka, Wafa F Badullah, Sultan O Alolayan and Mansour A. Mahmoud.
- [2] Mechanism of Action of Nonsteroidal Anti-Inflammatory Drugs by Newman Osafo, Christian Agyare, David Darko Obiri and Aaron Opoku Antwi.
- [3] Peptic ulcerations are related to systemic rather than local effects of low-dose aspirin. *Clin Gastroenterol Hepatol.* 2008 Mar;6(3):309-13. doi: 10.1016/j.cgh.2007.12.018. Epub 2008 Jan 31. van Oijen MG, Dieleman JP, Laheij RJ, Sturkenboom MC, Jansen JB, Verheugt FW.
- [4] Mechanisms, prevention and clinical implications of nonsteroidal anti-inflammatory drug-enteropathy. *World J Gastroenterol.* 2013 Mar 28; 19(12):1861-76. doi: 10.3748/wjg.v19.i12.1861. Wallace JL.
- [5] Diaphragm Disease: NSAID-Induced Small Bowel Stricture. Bruce J. Grattan Jr.,a, Tracy Bennett,b and Michael R. Starksb.
- [6] Diaphragm disease: pathology of disease of the small intestine induced by non-steroidal anti-inflammatory drugs. Lang J, Price AB, Levi AJ, Burke M, Gumpel JM, Bjarnason I.
- [7] Ulcer of the cecum during oxyphenbutazone (tandearil) therapy. Debenham GP.
- [8] Diaphragm Disease: NSAID-Induced Small Bowel Stricture. Grattan Jr. B.J.a • Bennett T.b • Starks M.R.b.
- [9] Mechanism of Action of Nonsteroidal Anti-Inflammatory Drugs. By Newman Osafo, Christian Agyare, David Darko Obiri and Aaron Opoku Antwi.
- [10] Whittle BJR. Mechanisms underlying intestinal injury induced by anti-inflammatory COX inhibitors. *Eur J Pharmacol.* 2004; 500:427-439.
- [11] Nonsteroidal anti-inflammatory drugs and inflammatory bowel disease: current perspectives. Cipolla G, Crema F, Sacco S, Moro E, de Ponti F, Frigo G.
- [12] Diaphragm like strictures of the small bowel associated with use of nonsteroidal antiinflammatory drugs. Scholz FJ, Heiss FW, Roberts PL, Thomas C.
- [13] Nonsteroidal anti-inflammatory drug-induced enteropathy: case discussion and review of the literature. Kwo PY, Tremaine WJ.
- [14] Detection and prevention of NSAID-induced enteropathy. Davies NM1, Saleh JY, Skjodt NM.
- [15] Diaphragm Disease of the Small Bowel: A Retrospective Review of CT Findings. Kristina T. Flicek, Amy K. Hara, Giovanni De Petris, Shabana F. Pasha, Anitha D. Yadav and C. Daniel Johnson.
- [16] Diaphragm Disease of the Small Bowel: A Retrospective Review of CT Findings. Kristina T. Flicek, Amy K. Hara, Giovanni De Petris, Shabana F. Pasha, Anitha D. Yadav and C. Daniel Johnson.
- [17] Systematic review of small bowel diaphragm disease requiring surgery. Slessor AA, Wharton R, Smith GV, Buchanan GN.
- [18] Histopathology of Diaphragm Disease of the Small Intestine A Study of 10 Cases from a Single Institution. Giovanni De Petris, MD, and José I. López, MD
- [19] Recurrent Enterolithiasis Small Bowel Obstruction: A Case Seldom Described. Ashish Lal Shrestha and Pradita Shrestha.