

Rare Case of Post Traumatic Carotico-Juglar-Vertebral Fistula with Pseudo Aneurysm

Saurabh kumar¹, Pallavi Aga², P.K. Srivatstav³, Durgesh k. dwivedi⁴, Anit parihar⁵, Neera kohli⁶

Department of Radiodiagnosis, KGMU, Uttar Pradesh, India

Email id: [1mbbs.saurabh@gmail.com](mailto:mbbs.saurabh@gmail.com)

Email id: [2agapallavi.pa@gmail.com](mailto:agapallavi.pa@gmail.com)

Affiliation: Study was approved by ethical committee of medical university, K.G.M.U., Lucknow

Abstract: *Arteriovenous fistula (AVF) is usually seen after acute vascular injuries. An AVF with pseudo aneurysm may present soon after the vascular injury or later. Since the AVF are associated with direct shunting of blood between artery and vein thus bypassing the capillaries, they are usually associated with significant haemodynamic instability. Uncorrected large AVF lead to significant morbidity and may finally land up in high output cardiac failure in rare cases. Proper diagnosis of AVF needs careful clinical examination and imaging modalities like ultrasound and CT angiography.*

Key words: *Arteriovenous fistulas (AVFs), color Doppler, CT angiography (CTA).*

Introduction:

Arteriovenous fistulas (AVFs) are direct abnormal communication between arterial and venous channel thereby bypassing the capillary bed. They can be either congenital or acquired. Congenital AVFs are less common and frequently have numerous small arteriovenous connections, while acquired fistulas consist of a single larger connection, and they are most frequently the result of penetrating trauma or iatrogenic action like internal jugular vein (IJV) catheter placements. Acquired AVFs often have a traumatic origin and war and after-war periods have offered the major contribution to their knowledge^[1-6]. These lesions can involve all the body districts arteries with prevalence in lower extremities (49%). Acquired AVFs involving major vessels in the head and neck are most frequently caused by penetrating trauma (gunshot injury and stab wounds) or by internal jugular vein catheterization for central venous pressure monitoring, parenteral nutrition or vascular access for hemodialysis and are nowadays increasing in the developing countries^[7].

AVF presents with varying signs and symptoms which include pulsatile neck swelling, systolic murmur, palpable thrill, and compression over adjacent vessels leading to dilatation of superficial veins. The arteriovenous shunt results in sudden increase of venous return, pressure, and volume, with simultaneous fall in total peripheral resistance so it may cause increased heart rate, stroke volume, cardiac output and if untreated finally lead to irreversible high output cardiac failure. Catheter angiography is the gold standard investigation for diagnosis by demonstrating early visualization of the draining jugular vein in the arterial phase with the added advantage of the possibility of concurrent endovascular treatment. Ultrasonography (USG) is a sensitive and noninvasive modality for detecting AVFs. Color and duplex US findings include turbulent IJV flow with increased velocity and high pulsatility, increased velocity and low pulsatility carotid flow and change in calibre of the carotid around the AVF with focal IJV dilation caudal to the AVF. Color Doppler USG is very sensitive for visualizing AVFs and may be used as the

reference standard, however tends to overestimate the diameter of the tract. Other modalities include CT angiography (CTA) and MR angiography (MRA). CTA provides the best spatial resolution of catheter angiography and offers the best three-dimensional localization of the AVF within the

tissues if surgical repair is planned. MRA offers flow information via dynamic sequences and phase velocity mapping, though hemodynamic information is inferior to US and the spatial resolution is inferior to CTA.

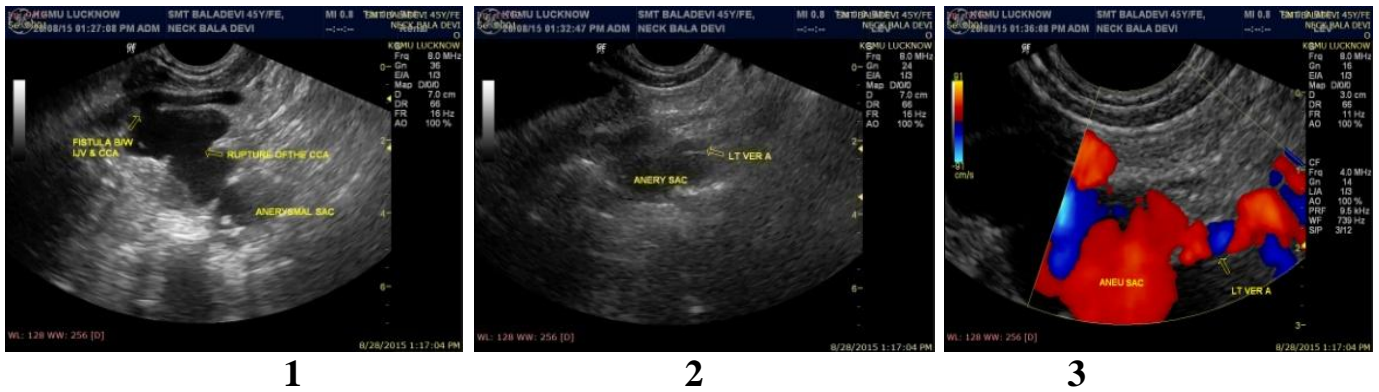

Figure (1,2,3):USG shows well defined anechoic lesion showing communication with common carotid artery ,internal juglar vein and vertebral artery.

Case report:

We report a case of 40 year female who presented to emergency trauma centre with a history of gunshot injury in left side of neck. At the time of presentation patient was unconscious, tachypnoeic and had tachycardia with low GCS score. Peripheral pulses were found to be normovolemic and regular. Urgent packing of the wound site was done and she was put on ICU care without any active intervention. On the 7th day of hospitalization patient she developed a swelling in left side of neck. On examination an ill defined

pulsatile swelling was noted at wound site showing fluid thrill, bruit and continuous murmur leading to a clinical suspicion of aneurysm. Urgent USG with Doppler was done which revealed a well defined sac on the left side of neck continuing with adjacent common carotid artery, vertebral artery and internal jugular vein. (Figure 1, 2, 3). On Doppler study swelling shows color filling with mixing of color (figure 4) and waveform shows typical ying yang pattern thus strengthening our diagnosis of fistula with aneurysm formation (Figure 5).

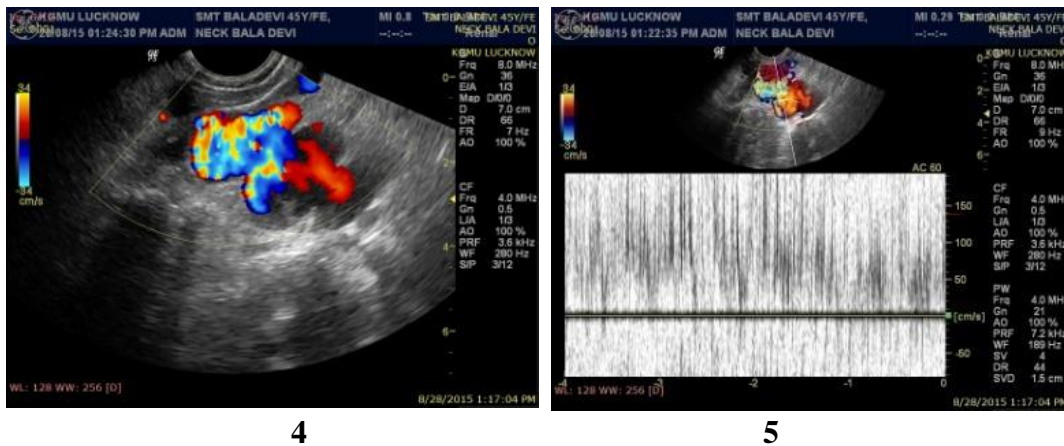
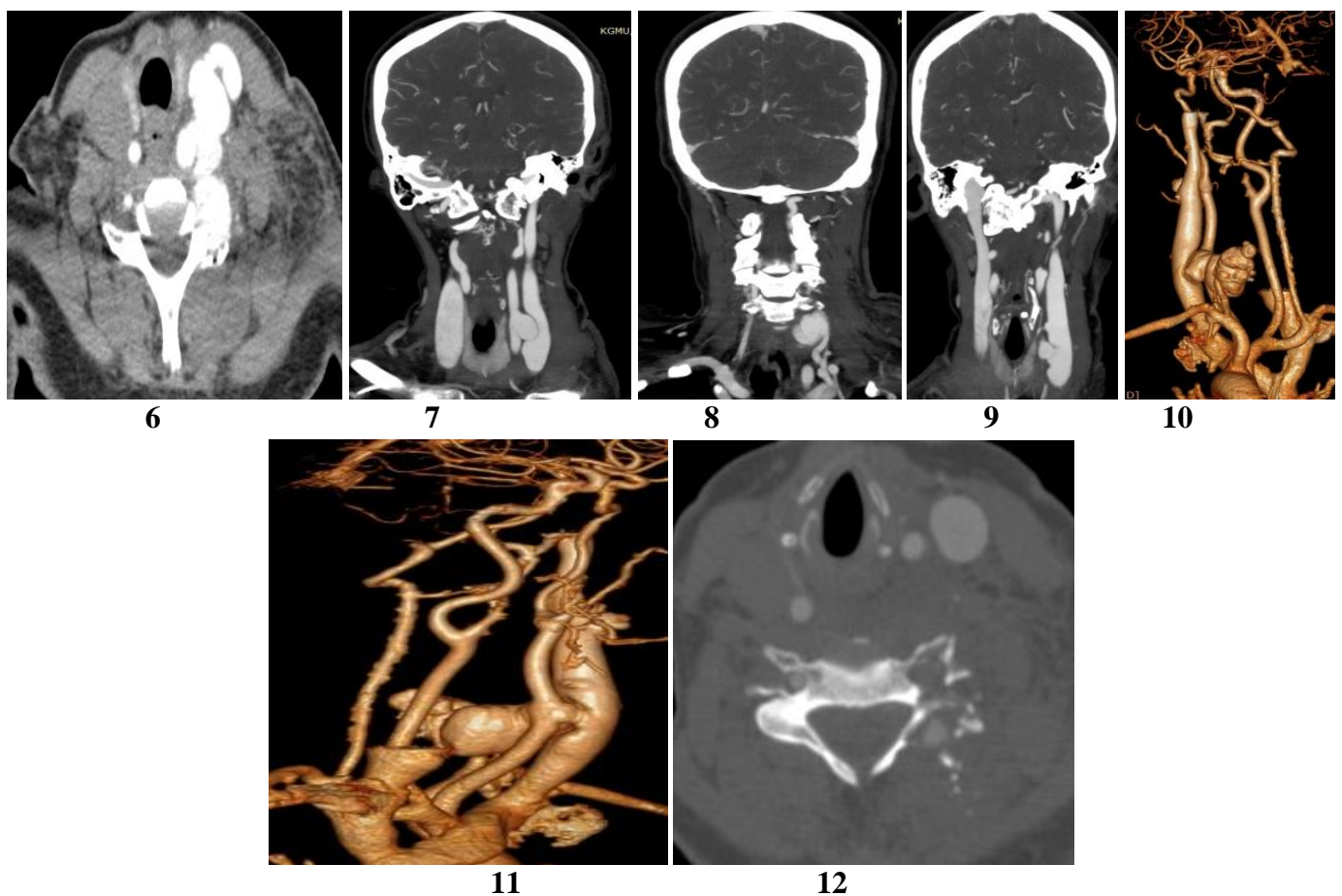


Figure (4): Shows colour filling in the aneurysmal sac.

Figure (5): Doppler waveform shows ying yang pattern strenthening the diagnosis of aneurysm.

To confirm our diagnosis CT angiography of neck was done which showed a well defined lobulated soft tissue lesion in left side of neck with pooling of contrast was noted within it (Figure 6). Contrast was noted in left IJV in arterial phase documenting the fistulous communication between arterial and venous system. The aneurysmal sac was seen communicating with left common carotid artery anteriorly, vertebral artery posteriorly and internal jugular vein through its narrow neck. (Figure 7,8,9). Volume rendered images gave an optimal road map of the lobulated

pseudo aneurysm with the fistulous communication between carotid artery, vertebral artery and internal jugular vein. (Figure 10, 11). Common carotid artery and left vertebral artery was not visualized just before its bifurcation due to compression by swelling. Left internal jugular vein is seen dilated. Comminuted fracture of transverse process of C6 and C7 vertebral body with involvement of vertebral canal was also noted (Figure 12). Adjacent soft tissue appears heterogenous with multiple fractured segments.



Figure(6): Well defined dilated sac with pooling of contrast.

Figure(7,8,9): Well defined lobulated soft tissue lesion in with fistulous communication with common carotids artery, internal jugular vein, and vertebral artery.

Figure(10,11): VRT images shows well defined aneurysmal sac with fistulous communication with vertebral artery, internal jugular vein, and common carotid artery.

Figure(12): Comminuted fracture of transverse process of adjacent vertebra(C7).

Discussion:

Acquired carotico-jugular-vertebral fistula (CJCFs) is extremely rare and has yet not been reported in any of the described literature to our best knowledge. Acquired common carotid-jugular fistulas (CJFs) are uncommon in the head and neck region, accounting only for 4 to 7% of all the traumatic AVFs encountered throughout the body^[8]. In a study done from 1994- 2000 out of the 30 cases of CJFs, only 9 were acquired^[9], 7 were situated between the CCA and the IJV, and only 2 were between the ICA and the IJV. Apart from 7 cases of CJFs due to gunshot or stab wounds, 3 presented after attempts at jugular catheter insertion^[10] or after a long-term catheter indwelling in the jugular vein. If the presence of an AVF is suspected, proper investigation such as duplex scanning and angiography need to be performed to confirm the diagnosis and acquire further data. Although invasive, conventional arteriography offers the most accurate information on the exact site and size of the fistula and is associated with a relatively low risk of thromboembolic neurological complications. Alternatively, noninvasive methods for detecting AV fistulas include Ultrasonography (USG) with color Doppler and magnetic resonance angiography (MRA).

Treatment approach for AVFs should be either via open surgery, or endovascular is still a matter of debate^[8]. To date, direct repair of AVFs between the common or internal carotid artery and the internal jugular vein seems to be preferred in large sized fistulas consequent to a gunshot or stab wound, or when AVFs are associated with false aneurysms or other vessel wall lesions. Endovascular treatment by stent-graft insertion is preferred in small diameter fistulas.

References:

- [1] S. F. Seeley, C. W. Hughes, F. N. Cook, and D. C. Elkin, "Traumatic arteriovenous fistulas and aneurysms in war wounded. A study of 101 cases," *The American Journal of Surgery*, vol. 83, no. 3, pp. 471–479, 1952.
- [2] C. W. Hughes and E. J. Jahnke Jr., "The surgery of traumatic arteriovenous fistulas and aneurysms: a five-year follow up study of 215 lesions," *Annals of Surgery*, vol. 148, no. 5, pp. 790–797, 1958.
- [3] A. C. Beall, O. B. Harrington, E. S. Crawford, and M. E. Debaquey, "Surgical management of traumatic arteriovenous aneurysms," *The American Journal of Surgery*, vol. 106, no. 4, pp. 610–618, 1963.
- [4] T. J. Whelan, W. E. Burkhalter, and A. Gomez, "Management of war wounds," *Advances in Surgery*, vol. 3, p. 327, 1968.
- [5] R. L. Hewitt and D. J. Collins, "Acute arteriovenous fistulas in war injuries," *Annals of Surgery*, vol. 169, no. 3, pp. 447–449, 1969.
- [6] N. M. Rich, R. W. Hobson, and G. J. Collins, "Traumatic arteriovenous fistulas and false aneurysms: a review of 558 lesions," *Surgery*, vol. 78, no. 6, pp. 817–828, 1975.
- [7] Y. Gong, H. X. Xu, M. Lin, and Y. Gu, "An iatrogenic complication of internal jugular vein catheterization for hemodialysis," *Irish Journal of Medical Sciences*, vol. 181, pp. 135–137, 2012.
- [8] M. Vera, L. Quintana, J. Blasco, M. Real, and J. M. Macho, "Treatment with the placement of carotid stent of jugular-carotid fistula after the insertion of hemodialysis catheter," *Nefrologia*, vol. 25, no. 5, pp. 568–571, 2005.
- [9] F. Gobeil, P. Couture, D. Girard, and R. Plante, "Carotid artery-internal jugular fistula: another complication following pulmonary artery catheterization via the internal jugular venous route,"

Anesthesiology, vol. 80, no. 1, pp. 230–232, 1994.

- [10] S. M. Hazinedaroglu, V. Genc, A. Y. Aksoy, C. Köksoy, A. Tüzüner, and E.

Atahan, “A late onset carotido-jugular fistula following shotgun injury,” *Vasa*, vol. 33, no. 1, pp. 46–48, 2004.