



# A Case of Spontaneous Rupture of the Spleen

Yasser El Brahmi, Mohammed El Fahssi, Anajjar Mohamed, Prosper Nsengiyumva, Ehirchiou Abdelkader, Abdelmounaim Ait Ali

Visceral surgery II, Military Hospital Mohammed V Rabat, Rabat, Morocco

Corresponding Author: Yasser El Brahmi; [yasserebrahim@gmail.com](mailto:yasserebrahim@gmail.com)

Received 24 April 2020;

Accepted 26 May 2020;

Published 25 June 2020

## Summary

We report a case of non traumatic spontaneous rupture of the spleen unknown aetiology, attended to emergency with feature of acute abdomen.

**Keywords:** *spleen, spontaneous rupture, splenectomy*

## Introduction

We report a case of a man who presented with a spontaneous splenic rupture unknown etiology.

## Observation

A 30-year-old man, with no past medical history, and no history of trauma, referred to emergency department with progressive pain in the left hypochondrium. On examination, patient was pale, fever 39.7 C, with guarding in left hypochondrium.

The blood test shows a leukocytosis at 23,000 / mm<sup>3</sup>, platelet level at 450,000 / mm<sup>3</sup> and hemoglobin level at 8 g / dl.

A abdominal CT scan was done and revealed a ruptured spleen with mild (Figure 1).

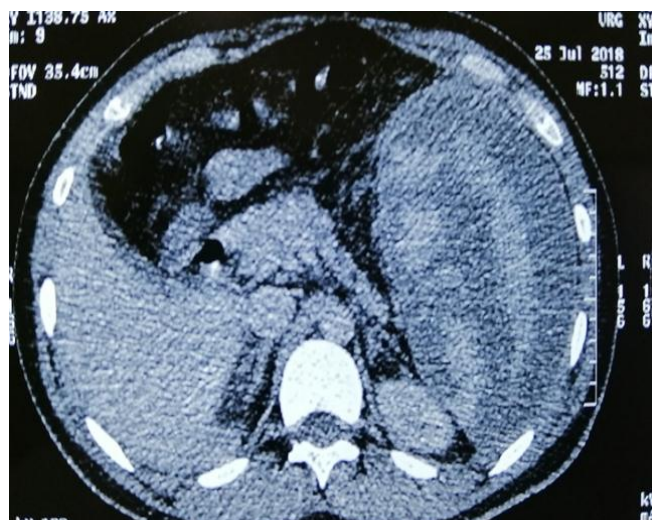


Figure no 1: CT image

Due to serious condition of the patient, an emergency median laparotomy performed, left peri-phrenic clots removed (Figure 2).

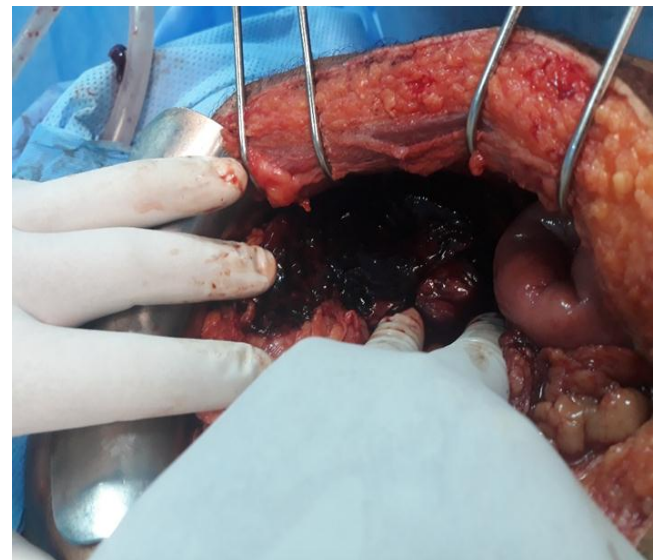


Figure no 2: intraoperative image of the splenic compartment.

The spleen was enlarged with multiple rupture and mild bleeding (Figure 3), A splenectomy was carried out following by wash out and suction of the splenic lodge.

The histopathological examination and the etiological investigation in our patient were not conclusive. The post-operative was uneventful, mild left pleural effusion noted. The patient discharged on the 8 th day post-operative.

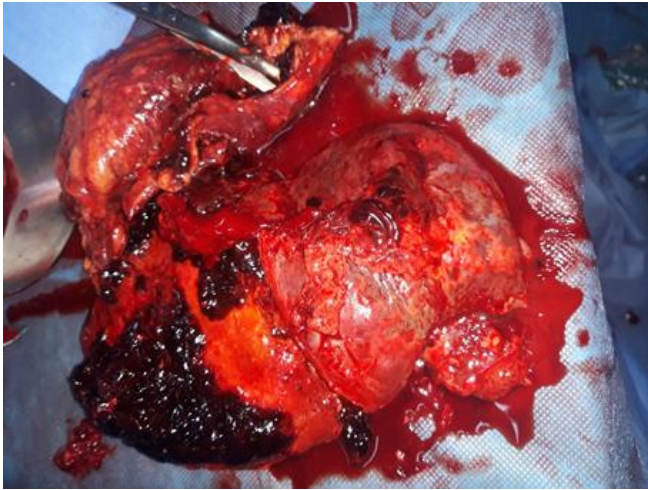


Figure no 3: operating room

## Discussion

Spontaneous rupture of the spleen, remains a rare phenomenon. The Causes of this non-traumatic rupture are multiple, infections represent 30% of the causes, especially malaria and infectious mononucleosis <sup>[1]</sup>.

The other causes are represented by Conditions associated with abnormalities of red cells such as spherocytosis and sickle cell anemia, Immune diseases, with changes in hemodynamics, and also infiltrative disorders of the spleen, whether benign (Amyloidosis, Gaucher disease...) or malignant (lymphomas Leukemia, metastases...) <sup>[2]</sup>.

The clinical presentation is not very specific, most often diffuse or localized abdominal pain in the left hypochondrium, sometimes with picture of hypovolemic shock.

Abdominal ultrasound usually done to confirm diagnosis. It is a reliable test and easily done at the patient's bed. <sup>[3]</sup>.

However, the abdominal scanner remain the gold standard to assess the lesion of course if the patient stable.

Laparoscopy is a complementary means of investigation, the place of which remains to be determined <sup>[4]</sup>.

The standard treatment for spontaneous rupture of the spleen is splenectomy,

Nevertheless, the hematological interest of the spleen and the morbidities linked to splenectomy, allow us to propose a conservative treatment in selected cases <sup>[5]</sup>.

## Conclusion

Spontaneous ruptures of the spleen constitute a diagnostic and therapeutic emergency, they are difficult to diagnose in the absence of abdominal imaging examination and are certainly a very rare cause of spontaneous hemoperitoneum.

## Conflicts of interest

The authors declare no conflict of interest.

## Author contributions

All the authors contributed to the conduct of this work. All authors also declare that they have read and approved the final version of the manuscript.

## References

- [1] Kianmanesh R, Aguirre HI, Enjaumb F, Valverdec A, Brugièred O, Vacher B, Bleichner G. Ruptures non traumatiques de la rate : trois nouveaux cas et revue de la littérature. *Annales de Chirurgie*. Juin 2003; 128(5):303-309.
- [2] Kianmanesh R, Aguirre HI, Enjaume F, Valverde A, Brugièrè O, Vacher B, et al. Ruptures non traumatiques de la rate : trois nouveaux cas et revue de la littérature. *Ann Chir* 2003; 128:303–9.
- [3] Holt. S.: Spontaneous rupture of a normal spleen diagnosed as ruptured ectopic pregnancy. Two case reports. *British journal of obstetrics and gynecology*. Dec 1982, Vol 89, pp 1002–1003.
- [4] Patz-Parlow, Ivatury RR, Simon RJ, Stahl WM. A critical evaluation of laparoscopy in penetrating abdominal trauma. *J Trauma*. 1991;161:332-5 I6.
- [5] Orioff MJ, Peskin GW. Spontaneous Rupture of the Normal Spleen, A Surgical Enigma. *Int. Abstr. Surg.* 1958; 106: 90.