



# Unusual Adverse Effects of Immune Checkpoint Inhibitors: Autonomic Neuropathy, Palmoplantar Keratoderma, Reiter Syndrome & Myasthenia Gravis: A Case Series and Review of the Literature

Walid Shalata <sup>\*a</sup>, Alexander Yakobson <sup>\*a</sup>, Ismaell Massalha <sup>a</sup>, Aharon Y. Cohen <sup>a</sup>, Iris M. Goldstein <sup>b</sup>, Rachel Gibbs <sup>c</sup>, Abu Saleh Omar <sup>d</sup>, Mohnnad Asla <sup>b</sup>, Yulia Dudnik <sup>a</sup>, Ali Abu-Juma'a <sup>e</sup>, Nir Peled <sup>a</sup>, Keren Rouvinov <sup>a</sup>

<sup>a</sup> The Legacy Heritage Oncology Center & Dr. Larry Norton Institute, Soroka Medical Center & Ben-Gurion University, Beer-Sheva, Israel.

<sup>b</sup> Department of Neurology, Soroka University Medical Center, Faculty of Health Sciences, Ben Gurion University, Beer Sheva, Israel.

<sup>c</sup> Medical School for International Health and Sciences, Ben-Gurion University, Beer Sheva, Israel.

<sup>d</sup> Department of Dermatology and Venereology, the Emek Medical Centre, Afula, Israel.

<sup>e</sup> Department of Internal Medicine, Soroka University Medical Center, Faculty of Health Sciences, Ben Gurion University, Beer Sheva, Israel.

\*These two authors contributed equally to this work.

\*Corresponding Author: Dr. Walid Shalata, MD, Resident Physician in Oncology, The Legacy Heritage Oncology Center & Dr. Larry Norton Institute, Soroka Medical Center & Ben-Gurion University, Beer-Sheva, Israel; [walid.shalata@gmail.com](mailto:walid.shalata@gmail.com)

Received: 11 October 2020;

Accepted: 12 November 2020;

Published: 23 November 2020

## Abstract

The immune checkpoint inhibitors (ICIs) have transformed the standards of care in cancer treatment and has dramatically improved patient prognoses. As a result of the introduction of these novel treatments several types of adverse events related to ICIs (immune related adverse events ((irAEs)) have been observed and reported. In this case series we describe the clinical course of four patients, with unusual ICI induced toxicities. The first patient was a 59 year-old female who received chemo-immunotherapy (pembrolizumab) for stage 4- lung adenocarcinoma, and developed autonomic neuropathy (AN). The second and third patients were both 63 year-old males who also received chemo-immunotherapy (pembrolizumab) for stage 4-A lung adenocarcinoma. One of those patients developed palmoplantar keratoderma and one developed conjunctivitis, urethritis and arthritis (Reiter syndrome). The fourth patient was an 80 year-old male who received chemo-immunotherapy (pembrolizumab) for stage 3-A squamous cell carcinoma of the lung and developed myasthenia gravis.

**Keywords:** *Pembrolizumab – Reiter Syndrome – Palmoplantar Keratoderma – Autonomic Neuropathy – Myasthenia Gravis – Immune Checkpoint Inhibitors (ICIs) – Immune Related Adverse Events (irAEs)*

## Introduction

Immune checkpoint inhibitors (ICIs) have transformed the prognosis of several malignancies establishing new standards of care in adjuvant, neo-adjuvant and metastatic settings. Pembrolizumab, for example, is an ICI that has been approved for the treatment of a wide range of malignancies including melanoma, renal cell cancer, colon cancer, and non-small cell lung cancer (NSCLC). However, the use of ICIs is associated with a wide

spectrum of side effects known as immune-related adverse events (irAEs) <sup>[1]</sup>. Pembrolizumab is a humanized IgG4 monoclonal antibody targeted against a major immune checkpoint receptor regulating T-cell response. Pembrolizumab and nivolumab are directed against the programmed cell death receptor 1 (PD-1). By blocking PD-1 activity these ICI's enhance anti-tumor T-cell activity. However, improved T-cell proliferation may also lead to irAEs <sup>[2]</sup>.

An analysis of 3953 patients from multiple clinical trials revealed that the most frequent irAEs include rash, diarrhea,

nausea, myalgia, arthralgia, and pneumonitis. Aside from rash, cutaneous adverse effects included pruritus and less commonly vitiligo [3]. Neurologic adverse events from immune checkpoint inhibition have also been increasingly recognized despite the presenting symptoms and signs often being sub-acute and highly variable [4]. Neurologic irAEs may be relatively less common than other irAEs, though the potential for long-term morbidity and even mortality is substantial [5]. Autonomic neuropathy is an exceedingly rare complication of ICI therapy. Serious immune-related central nervous system toxicities account for 0.4% of the overall incidence of irAEs [6]. Palmoplantar keratoderma (PPK) is a dermatosis defined as a persistent thickening of the epidermis of the palms and soles. PPK can be acquired or related to genetic etiologies. The manifestations of PPK may be consistent with a paraneoplastic syndrome of an internal malignancy presenting with dermatosis at a remote location [7]. Paraneoplastic PPK can be associated with visceral malignancies such as esophageal, gastric, pulmonary, and urinary or bladder carcinomas [8]. Reiter syndrome or reactive arthritis (also known as autoimmune disorder) is a classic triad of urethritis, arthritis and conjunctivitis which is related to infections of the gastrointestinal or urogenital tract, and may also involve sacroiliac the joints [9].

To the best of our knowledge, Reiter syndrome and PPK have not been previously reported in association with anti PD-1 treatment for lung cancer. In addition, we present two rare cases of autonomic neuropathy and myasthenia gravis, respectively, as secondary to ICIs treatment for lung cancer.

### Case No .1

A 59 year-old female with a history of malignant melanoma (stage 1) resected from the right upper extremity (30 years ago), papillary thyroid cancer treated with thyroidectomy (7 years ago) and a history of tobacco-use (30 pack years (PY)) but stopped smoking 20 years ago) presented to Soroka Medical Center with pneumonia in January 2019. She was treated with antibiotics and follow-up chest radiography after one month revealed a right upper lung (RUL) ground-glass opacity. For further investigation patient underwent a chest computerized tomography (CT) scan that

showed a RUL 2.9 cm ground-glass opacity, right hilar lymph node enlargement to 1.3cm and right middle lung (RML) space occupying lesion (SOL) with a diameter of 1.3cm.

The patient was referred to our oncology center for further investigation. A positron emission tomography (PET)-CT showed hyper-metabolic uptake in the RML SOL, RUL ground-glass opacity and in the right hilar lymph nodes. MRI of the head showed no evidence of metastasis to the brain. Biopsies via mediastinoscopy of the RUL opacity and RML mass were taken. Histopathologic results showed adenocarcinoma of lung origin. The pathologic stage was determined to be T2 N2 M1 (stage 4-A). The patient received systemic intravenous chemotherapy consisting of pemetrexed (500mg/m<sup>2</sup>) plus carboplatin (dosed to area under the curve (AUC)-5) and pembrolizumab (at dose of 200mg) on day 1 every 21 days.

After three cycles the patient presented with hot flashes, sweating, headaches, vertigo, systemic chills and pain in both arms. The treatment was stopped, and she underwent MRI of head and spine (**Figure 1**) with no evidence of distant metastasis or other pathological findings. Additionally, blood and urine cultures demonstrated no bacterial growth, and a total body CT-scan did not suggest any site of origin of the fever. Echocardiography of the heart was performed with no signs of pericarditis or myocarditis, and ejection fraction was within range. She was referred for neurologic consultation because of the arm pain which suggested bilateral upper extremity paresthesias. The neurologic diagnosis was suspected autonomic neuropathy from ICI therapy with pembrolizumab.

Corticosteroid therapy was initiated with prednisone (1mg/kg) for two weeks with no clinical improvement. The dose was then raised to 1.5mg/kg for another two weeks and again resulting in no relief of symptoms. The patient was re-admitted to our department for treatment with intravenous immunoglobulins (IV-IG) at 0.4mg/kg daily for 5 days. Several days into initiating IV-IG treatment, the patient reported improvement in the arm pain and paresthesias. After the 5 course of IV-IG treatment was completed, the clinical symptoms had almost completely resolved, and the patient's episodes of hot flashes and sweating had also stopped.

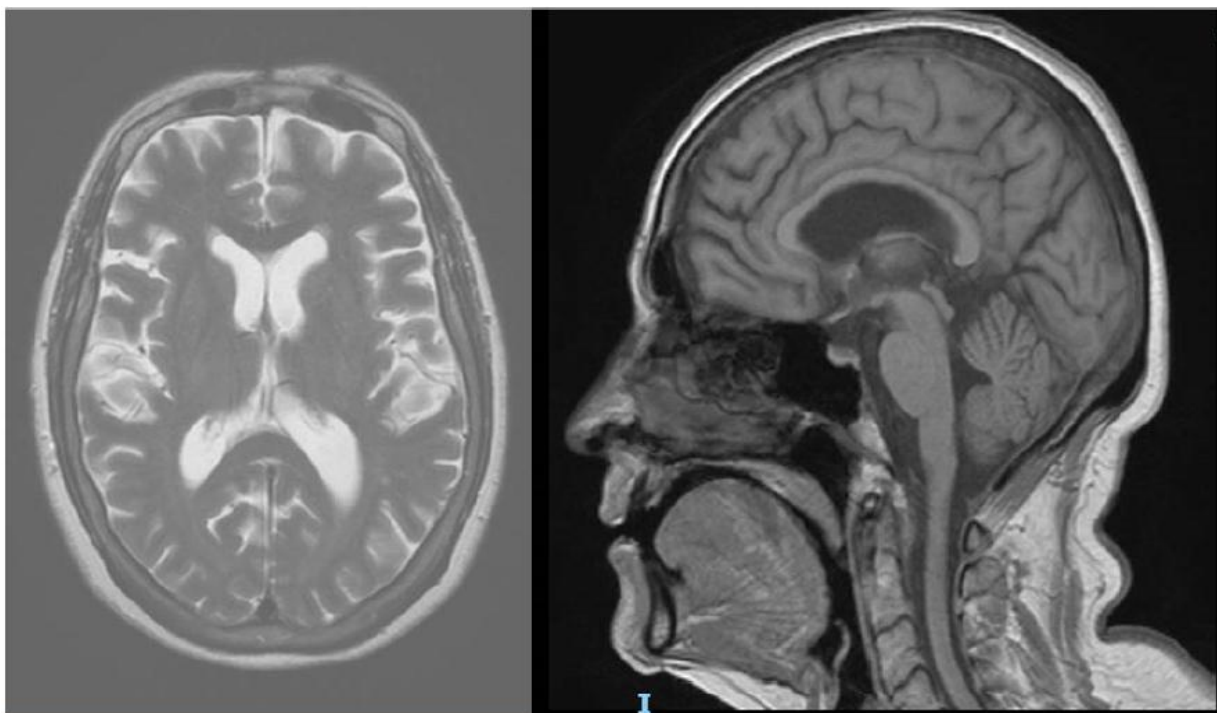


Figure 1: MRI of head with no findings of distant metastasis or pathological findings.

### Case No .2:

A 63-year old male with a 40 PY smoking history presented in June 2017 with increasing cough and mid-chest discomfort.

The patient underwent chest CT-scan which showed significant lymph node enlargement to 2.3cm in the left lung hilum, 1.3cm in right lung hilum, 3cm in mediastinum, and a left upper lung (LUL) ground-glass opacity with the greatest diameter of 2.2 cm.

The patient was referred to our oncology center for further investigation. PET-CT demonstrated hyper-metabolic uptake in the nodes and in the ground-glass opacity that had been seen on chest CT along with a 1.9 cm area of hyper-metabolic absorption in a retroperitoneal lymph node adjacent to the portal vein. In addition, a 1.5cm area of uptake in the right iliac bone was noted. MRI of the head was performed showing no evidence of metastatic disease.

A biopsy of the LUL mass was performed under CT guidance, and histopathologic findings showed adenocarcinoma of lung origin. The clinical diagnosis was adenocarcinoma of lung T2 N3 M1 (stage 4). Molecular testing showed PDL-1 staining at 30-40% and was negative for EGFR mutations and for ALK rearrangement.

The patient received systemic intravenous chemotherapy consisting of pemetrexed 500 mg/m<sup>2</sup>, plus cisplatin 75 mg/m<sup>2</sup> and pembrolizumab at a dose of 200 mg on day one every 21 days for

three cycles. There was a significant partial response (PR) after three cycles, but cisplatin was changed to carboplatin for the subsequent three cycles due to severe nausea. After six cycles of platinum-containing therapy, the patient continued on pemetrexed and pembrolizumab for five cycles. Systemic therapy was stopped due to interstitial pneumonia of the usual type, and the suspected cause was pembrolizumab treatment. Afterwards, stereotactic radiation therapy was administrated to the LUL residual mass.

In September 2018, pembrolizumab was restarted after follow-up PET-CT showed new hypermetabolic uptake in the right supraclavicular lymph node and lymphadenopathy in the left lung hilum. The patient received a fixed dose of 1200mg on day 1 every 21 days.

In July 2019, new dermatological changes with thickening of skin were seen in the both feet accompanied by moderate and progressive pain. The patient was referred to a dermatologist due to suspicion of PPK (Figure 2). The interval between administrations of pembrolizumab was increased to every six weeks with the dose unchanged. Two months later due to pain from progressing PPK, pembrolizumab was discontinued (Figure 3).

The patient was referred again to the dermatologist and who initiated treatment with bifonazole urea cream (Keratospo<sup>TM</sup>), topical salicylic acid 10%, and oral acitretin (Acitretin<sup>TM</sup>) 25mg given once daily. Two months later the thickening of the skin in all extremities showed regression and pain was significantly resolved (Figure 4).

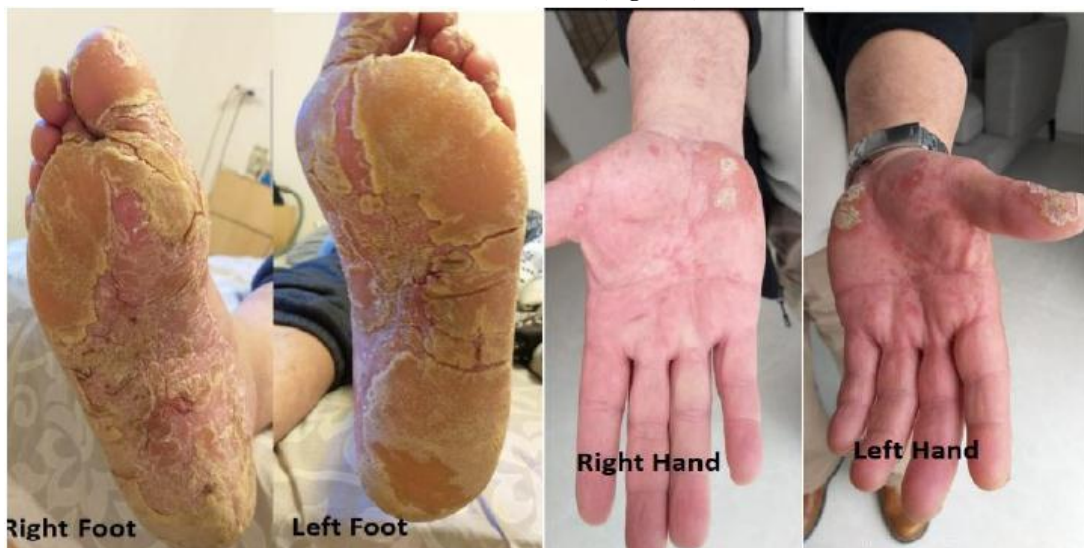

Figure 2: PPK of the hands and feet before stopping the pembrolizumab and initiating dermatological treatment.

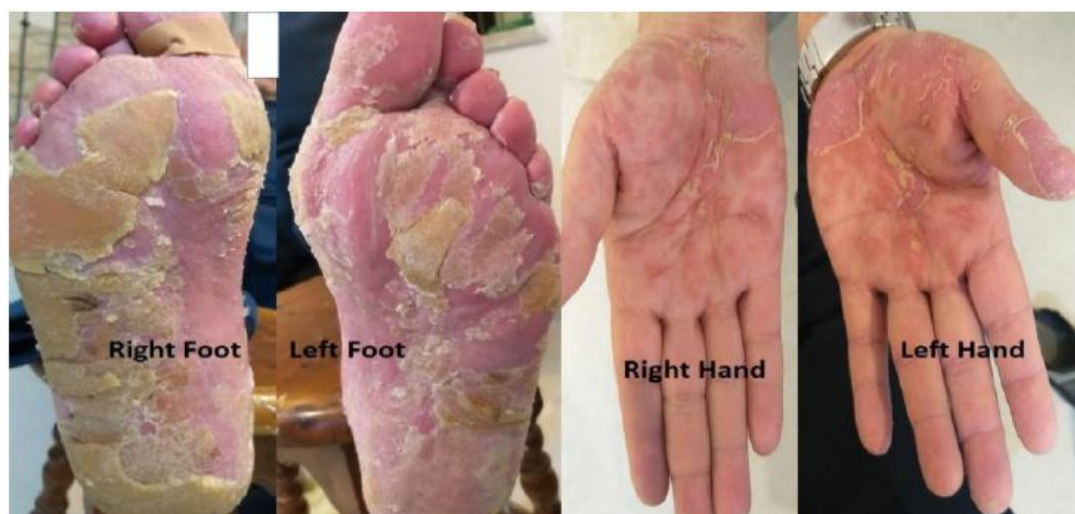
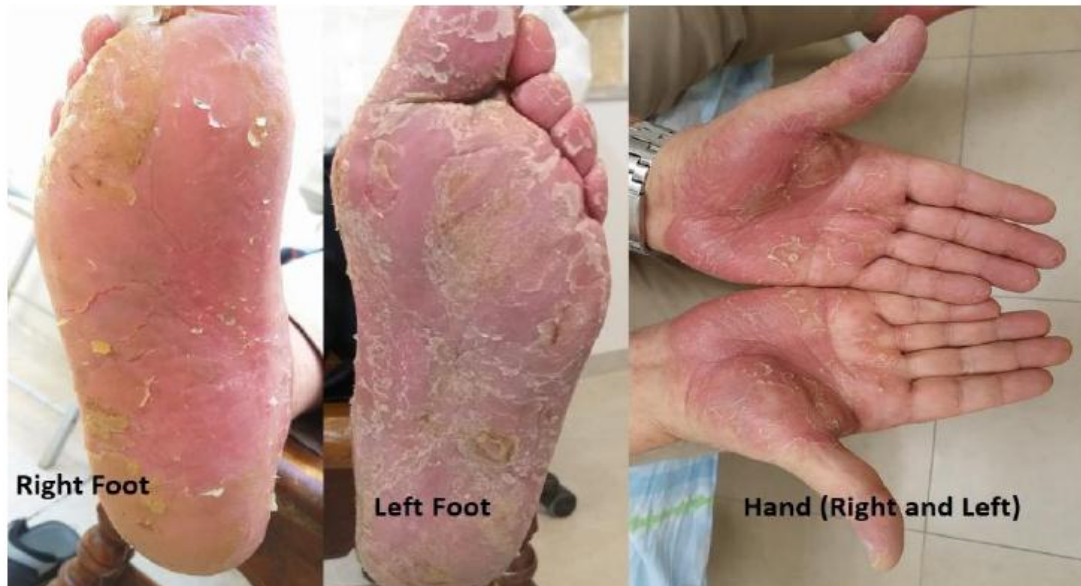
Figure 3: PPK of the hands and foots soon after stopping pembrolizumab and initiating dermatological treatment.





**Figure 4: Improvement of PPK on the hands and feet while on dermatologic treatment.**

### Case No .3

A 63 year-old male was in routine follow-up after being treated in 2001 for squamous cell carcinoma of the larynx, stage 2 (T2N0M0) with curative radiotherapy. He had a 65 PY smoking history and a history of a cerebrovascular accident and hypothyroidism. In September, 2018 because of recurrent falls and headaches he underwent a CT scan of the head which showed a single right occipital brain metastasis (2.2 cm in diameter) with surrounding edema. For further investigation the patient underwent a total body CT which showed a right upper lobe (RUL) mass (diameter of 1.6\*1.5 cm), and right hilar lymph node enlargement to 1.5 cm.

The patient underwent right occipital craniotomy and RUL segmental resection. Histopathologic results from both areas showed adenocarcinoma of lung origin. The pathologic stage was determined to be T1 N1 M1 (stage 4-A). Molecular testing showed PDL-1 staining at 75% and was negative for EGFR mutations and for ALK rearrangement. Radiotherapy to the brain (craniotomy area) was administered (30 GY in 10 fractions). The patient received systemic intravenous chemo-immunotherapy consisting of vinorelbine 30 mg/m<sup>2</sup> at day 1 and 8 every 21 days, carboplatin (dosed to AUC -4) and pembrolizumab at a dose of 200 mg on day 1 every 21 days for four cycles. There was complete radiological response, with the mediastinal lymph nodes decreasing to normal size with no evidence of metastatic disease. The patient continued treatment with pembrolizumab alone (as maintenance at fixed dose of 200mg) on day one every 21 days. After 8 cycles of pembrolizumab he complained of knee pain, burning while urinating and eye irritation. During physical examination swelling and tenderness of both knees and conjunctivitis in both eyes were noted. Laboratory results including complete blood count and chemistry panel were in normal ranges and carcinoembryonic antigen was in normal range but there was a sharp increase in prostatic specific antigen (PSA) (ordered in error by the family physician) from normal values to 21(normal 0-4 ng/ml). A multidisciplinary conference including oncology, rheumatology, immunology and infectious disease specialists came to the conclusion that the clinical presentation of the patient was that of conjunctivitis grade (GR) 3 and arthritis GR 2, consistent with a diagnosis of Reiter's syndrome most probably as a toxicity of immunotherapy. The pembrolizumab was discontinued. For further investigation the patient underwent genitourinary serological tests

and cultures (chlamydia trachomatis, neisseria gonorrhoeae, mycoplasma hominis and ureaplasma urealyticum) which were all negative. Gastrointestinal disease was ruled out clinically due to the lack of complaints and no evidence of active infection. A prostate biopsy was performed which showed chronic and acute inflammation (prostatitis).

Corticosteroid therapy was initiated with prednisone (1.5mg/kg) and he was treated for two weeks with significant improvement and resolution of the symptoms.

### Case No .4

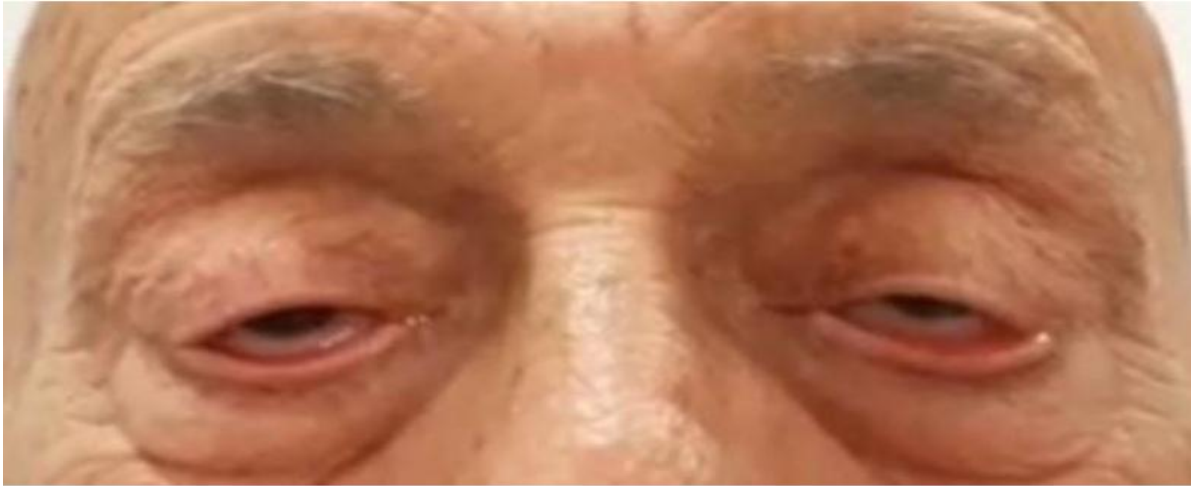A 80-year old male presented in March 2020 with cough and dyspnea of one month duration. He had experienced left sided chest pain for the previous two months.

The patient had a history of benign prostatic hyperplasia, diabetes type 2, hypertension, tobacco use (40 PY) and had stopped smoking 8 years previously.

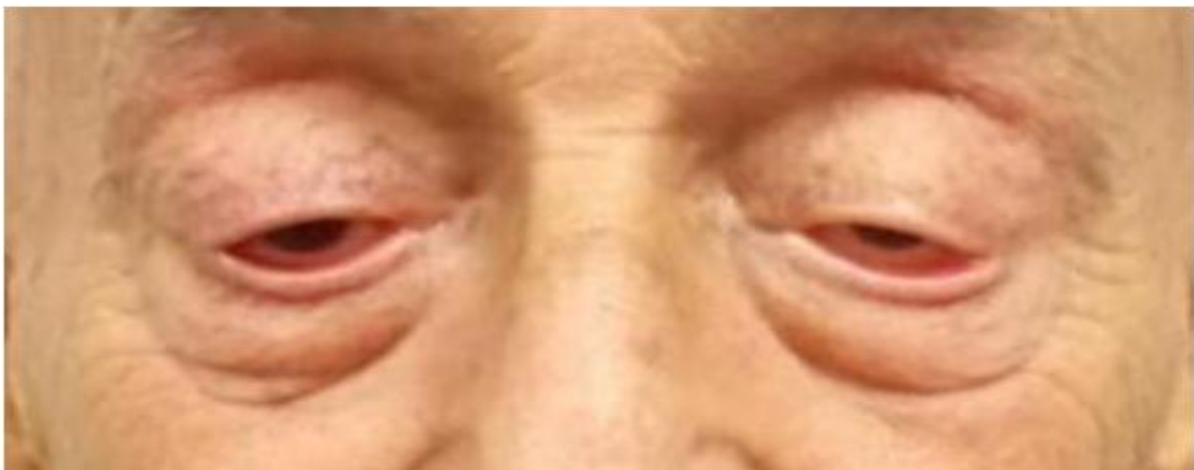Chest radiography (CXR) showed ground-glass opacity in the left upper lobe (LUL). Pneumonia was suspected and he was treated with antibiotics. One month later he underwent follow-up CXR which revealed the same LUL ground-glass opacity. Endobronchial ultrasound was performed with biopsy of the LUL finding. Pathological results showed squamous cell carcinoma of lung origin. Magnetic resonance imaging (MRI) of the head showed no evidence of brain metastases and PET-CT showed hyper-metabolic uptake in the LUL mass (diameter of 8.5\*6.5 cm), a hyper-metabolic uptake and enlargement in left mediastinal lymph nodes (with diameter of 2 cm). In addition there were multiple lung nodules with diameter up to 3-2 mm too small in size to show uptake on PET. The presumptive clinical diagnosis was stage T4 N1 M0 (stage 3-A) non-small cell lung cancer. Molecular testing showed PDL-1 staining at 50% and was negative for EGFR mutations and for ALK rearrangement. The patient received systemic intravenous chemo-immunotherapy consisting of paclitaxel 200 mg/m<sup>2</sup>, carboplatin (dosed to AUC-3) and pembrolizumab at a dose of 200 mg on day one every 21 days for three cycles. After receiving four cycles of treatment a PET-CT showed good radiological response with a decrease in size of the LUL mass to a diameter of 6\*4cm, and decrease of the hyper-metabolic uptake in the mediastinal lymph nodes along with shrinkage of the nodes to normal size. In addition there was

disappearance of the lung nodules. The patient continued treatment with pembrolizumab alone (fixed dose of 200mg) on day one every 21 days. After two cycles of pembrolizumab (as monotherapy), he complained of bilateral ptosis (plus near complete ophthalmoplegia), and slurred speech with drooping of one corner of the mouth (**Figure 5**). The suspected diagnosis was myasthenia gravis due to ICI therapy with pembrolizumab. The treatment was stopped. Neurologic consultation concurred with the diagnosis.

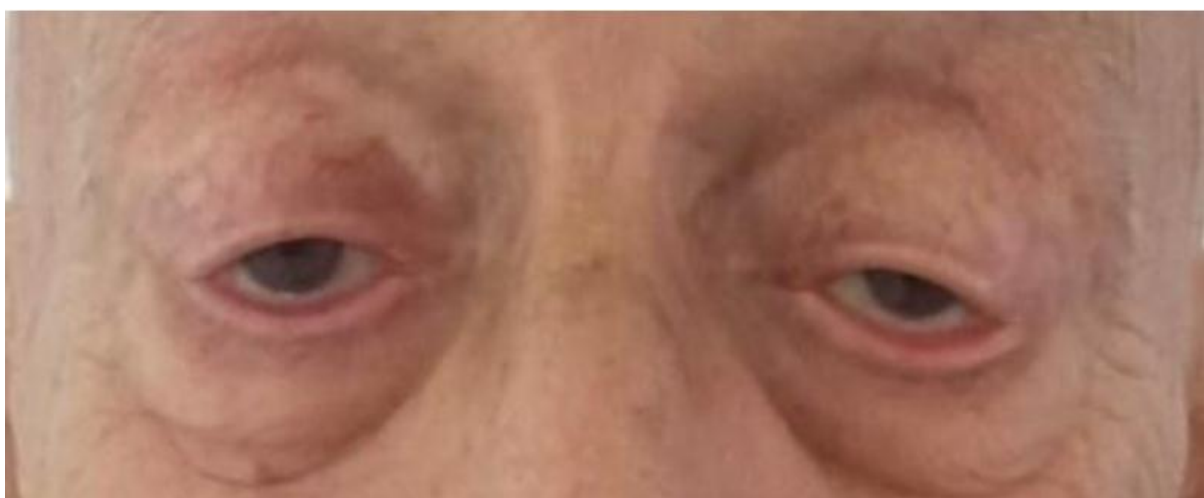Corticosteroid therapy was initiated and he was treated with prednisone (1mg/kg) for two weeks with minimal clinical improvement (**Figure 6**). The patient was re-admitted to our department for treatment with IV-IG at 0.4mg/kg daily for 5 days. On the second day of IV-IG treatment, the ptosis improved and he was speaking more clearly (**Figure 7 and Figure 8**). One week later the symptoms completely resolved.



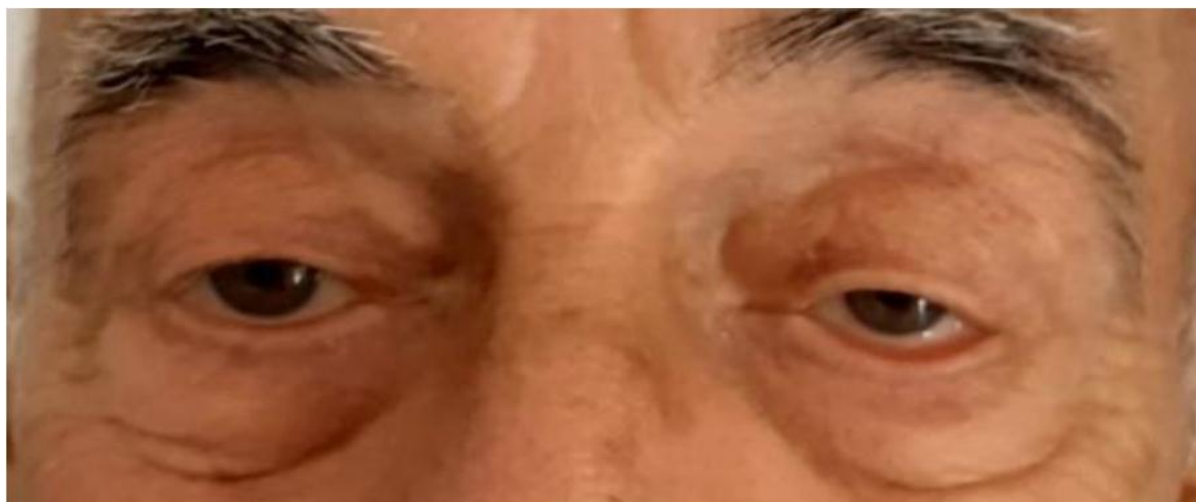**Figure 5: Bilateral ptosis, plus near complete ophthalmoplegia (at presentation)**



**Figure 6: Minimal improvement in the bilateral ptosis after corticosteroid treatment.**



**Figure 7: Improvement in the bilateral ptosis, after the second day of IV-IG treatment.**



**Figure 8: Improvement in the bilateral ptosis, after the fifth day of IV-IG treatment.**

## Discussion and Conclusion

Recognition and treatment of ICIs including the neurological and cutaneous toxicities as well as resulting autoimmune disease can be challenging. Immune-suppressant treatments with IV and oral corticosteroids, immunoglobulin agents, and plasma exchange can lead to partial recovery. IV-IG is usually reserved for more severe cases of irAEs. Johnson et al. reported five distinct categories of neurologic toxicities associated with ICI therapy including autonomic neuropathy, neuromuscular dysfunction (myasthenia gravis), encephalitis/myelitis, cerebral vasculitis, Guillain-Barre Syndrome, and non-infectious meningitis [9,10]. The spectrum of neurologic complications from ICI therapy has been expanded to include painful brachial plexus neuritis [11]. Reiter's syndrome (autoimmune disorder) consists of a classic triad of arthritis, genitourinary and conjunctivitis as well as specific symptoms. Most often the cause of this syndrome is secondary to intestinal infection or genital infection [12,13]. Therefore we hypothesized that the symptoms were related to an autoimmune response associated with pembrolizumab. Here, we present four unusual cases of irAEs in which treatment lead to complete symptom relief or a significant improvement. This case series supports the notion that an unusual or rare adverse effect may be a predictive factor for favorable treatment response [14].

To the best of our knowledge, neither Reiter Syndrome nor PPK associated with pembrolizumab therapy have been previously reported. The occurrence and rapid improvement of symptoms after corticosteroid and/or IV-IG treatment suggest a neurologic and immunologic mechanism rather than an independent synchronous occurrence. While the exact immune-mediated mechanism is not clear, peripheral T-cell dysregulation seems likely.

Withholding ICIs and initiating high-dose corticosteroids has been beneficial in most irAEs especially when the adverse effect is observed early. Whether to add corticosteroid sparing agents such as IV-IG to the course of therapy needs to be considered on an individual basis. Therefore, oncology patients on ICI treatment regimens should be evaluated for irAEs, and we recommend early administration of high-dose corticosteroids as treatment and IV-IG in specific, severe cases.

## Data Availability

Not applicable

## Disclosure Statement

The authors declare no conflict of interest.

## Funding Sources

The authors received no financial support for the research, authorship, and/or publication of this article.

## Acknowledgements

The authors thank David B. Geffen, MD for his critical review of the manuscript.

## Statement of Ethics

The authors have no ethical conflicts to disclose.

## References

- [1] Postow MA, Sidlow R, Hellmann MD. Immune-related adverse events associated with immune checkpoint blockade. *N Engl J Med.* 2018;378(2):158–68.
- [2] Pardoll DM. The blockade of immune checkpoints in cancer immunotherapy. Vol. 12, *Nature Reviews Cancer.* 2012. p. 252–64.
- [3] Wang M, Ma X, Guo L, Xia F. Safety and efficacy profile of pembrolizumab in solid cancer: Pooled reanalysis based on randomized controlled trials [Internet]. Vol. 11, *Drug Design, Development and Therapy.* Dove Medical Press Ltd.; 2017 [cited 2020 Apr 11]. p. 2851–60. Available from: <http://www.ncbi.nlm.nih.gov/pubmed/29033546>
- [4] Spain L, Tippu Z, Larkin JM, et al. How we treat neurological toxicity from immune checkpoint inhibitors *ESMO Open* 2019;4:e000540. doi: 10.1136/esmoopen-2019-000540
- [5] Wang DY, Salem J-E, Cohen JV, et al. Fatal Toxic Effects Associated with Immune Checkpoint Inhibitors: A Systematic Review and Meta-analysis. *JAMA Oncol* 2018; 4:1721-8. doi:10.1001/jamaoncol.2018.3923
- [6] Jonathan T. Blackmon, Toni M. Viator, Robert M. Conry. Central Nervous System Toxicities of Anti-Cancer Immune Checkpoint Blockade. *Jneurology.com.* <<https://www.jneurology.com/articles/central-nervous->

- system-toxicities-of-anticancer-immune-checkpoint-blockade.pdf> [30 July 2016].
- [7] Thiers BH, Sahn RE, Callen JP. Cutaneous Manifestations of Internal Malignancy. *CA: A Cancer Journal for Clinicians*. 2009 Mar 1 [cited 2020 Apr 11];59(2):73–98. Available from: <http://doi.wiley.com/10.3322/caac.20005>
- [8] Kallini JR, Sadeghani K, Khachemoune A. Paraneoplastic palmoplantar keratoderma secondary to metastatic uterine adenocarcinoma. *Cutis* [Internet]. 2017 Mar 1 [cited 2020 Apr 11];99(3):E32–5. Available from: <http://www.ncbi.nlm.nih.gov/pubmed/28398428>
- [9] Wu, I. and Schwartz, R., 2008. Reiter's syndrome: The classic triad and more. *Journal of the American Academy of Dermatology*, [online] 59(1), pp.113-121. Available at: [https://www.jaad.org/article/S0190-9622\(08\)00281-8/fulltext](https://www.jaad.org/article/S0190-9622(08)00281-8/fulltext). Johnson, D.B., Manouchehri, A., Haugh, A.M. et al. Neurologic toxicity associated with immune checkpoint inhibitors: a pharmacovigilance study. *J. immunotherapy cancer* 7, 134 (2019). <https://doi.org/10.1186/s40425-019-0617-x>
- [10] Trinh S, Le A, Gowani S, La-Beck NM. Management of Immune-Related Adverse Events Associated with Immune Checkpoint Inhibitor Therapy: a Minireview of Current Clinical Guidelines. *Asia Pac J Oncol Nurs*. 2019;6(2):154-160. doi:10.4103/apjon.apjon\_3\_19
- [11] Connie Jackaman, Christine S. Bundell, Beverley F. Kinnear, Alison M. Smith, Pierre Filion, Deborah van Hagen, Bruce W. S. Robinson and Delia J. Nelson *J Immunol* November 15, 2003, 171 (10) 5051-5063; DOI: <https://doi.org/10.4049/jimmunol.171.10.5051>
- [12] National Organization for Rare Disorders, & J.D.C. (2020, February 13). Reactive Arthritis. <https://Rarediseases.Org/Rare-Diseases/Reactive-Arthritis/>. <https://rarediseases.org/rare-diseases/reactive-arthritis/>
- [13] Mayo Clinic. (2019, October 2). Reactive arthritis. <https://www.mayoclinic.org/diseases-conditions/reactive-arthritis/symptoms-causes/syc-20354838>.
- [14] Shalata W, Peled N, Gabizon I, Abu Saleh O, Kian W, Yakobson A: Associated Myocarditis: A Predictive Factor for Response? *Case Rep Oncol* 2020;13:550-557. <https://doi.org/10.1159/000507278>