



Ovarian Ectopic Gestation after Assisted Reproductive Technique with Intracytoplasmic Sperm Insemination

Muna Kh. Al Kubaisi¹, Md Azam Md Yusoff¹, Saad M. Al-Shibli^{*2}, Nurul Jannah Ismail¹, Iza Emilia Md Ibrahim¹, Azha S. Azizan¹, Khairunisa Ahmad Affandi KA Affandi³, Roszaman Ramli⁴

¹Department of O&G, Kulliyyah of Medicine, International Islamic University Malaysia (IIUM), SASMEC

²College of Medicine, Komar University of Science and Technology, Iraq

³Department of Pathology and Laboratory Medicine, Kulliyyah of Medicine, International Islamic University Malaysia (IIUM), SASMEC

⁴Fertility Clinic, International Islamic University Malaysia Specialist Centre, (IIMSC)

*Corresponding author: Dr Saad M. Al-Shibli; salshibli2004@yahoo.com

Received 12 February 2022;

Accepted 01 March 2022;

Published 05 March 2022

Abstract

Assisted reproduction technique (ART) is a known risk factor for ectopic pregnancy (EP). Ovarian ectopic pregnancy (OEP) is a rare but well-known variant of EP, which carries diagnostic challenges & is mostly diagnosed intraoperatively. Fibroid is a common medical problem, but it is not yet a recognised risk factor for OEP. Risk factors as pelvic inflammatory disease, endometriosis or fibroids can alter fallopian tube patency results in EP. In this case study the embryo implantation occurs in the ovaries with retrograde embryo migration from the uterine cavity to the peritoneum. We present an OEP with male factor subfertility that went for frozen embryo transfer. The woman had multiple small fibroids referred to the tertiary centre for fluctuation in β -hCG level and suspicion of cornual pregnancy. However, the patient was asymptomatic & haemodynamically stable. Initial diagnosis of EP with viable fetus necessitate laparoscopic interference revealed left sided OEP with normal left fallopian tube (FT). The right ovary and FT looked normal. Surgical interference with partial oophorectomy was done and the histopathological report confirms the diagnosis of OEP. The following embryo transfer after 3 months ended by viable intrauterine pregnancy.

Keywords: Ovarian ectopic, Pregnancy, frozen embryo, Laparoscopy, β -hCG.

Introduction

Ectopic pregnancy is defined as implantation of conceptus material outside the uterine cavity [1]. Its incidence is difficult to be determined because of significant variation in the standards of reporting. Its incidence is rising with the development of new medical techniques as assisted reproduction (ART), which carry 2% risk of ectopic pregnancy [2]. Ovarian ectopic pregnancy is a rare form of non-tubal ectopic and its incidence of all ectopic pregnancy is about 3%. It could be primary, which is the result of follicular fertilization in the ovary, or secondary, which is due to the embryo reflux through the tube [3] as in our case.

Reverse migration during embryo transfer can be enhanced by increasing the volume of culture fluid used in the transfer, deep deposition of embryos in the uterine cavity, positioning of the patient with a head down tilt (Trendelenburg), and high oestrogen levels after ovarian stimulation [4].

Risk factors for EP include ART [5], history of using IUCD [6], age, history of subfertility [7], and low body mass index [8]. Most presentations are in first trimester with acute abdominal pain and vaginal bleeding while some cases can proceed to term & present as abdominal pregnancy [6].

Ovarian ectopic pregnancy usually possesses a diagnostic challenge. It is usually diagnosed intraoperatively and histologically. However, initial diagnosis of ectopic pregnancy is made by hormonal & sonographic examination. There are no specific known criteria for the ultrasound diagnosis of ovarian ectopic pregnancy [1]. Contrary to the usual presentation of ectopic pregnancy, the patient in this case report was asymptomatic and referred for fluctuation in her serum β -hCG levels with initial diagnosis of intrauterine pregnancy.

Treatment of OEP is usually surgical by removing the conceptus material, but partial oophorectomy is sometimes

inevitable [1]. Successful medical treatment reported with Methotrexate or Misoprostol is also reported [9].

Case Report

A Malaysian Chinese couple presented to a fertility clinic for trying to conceive. They practice barrier method as contraception for 3 years after having their first baby. The couple had 9 years of secondary subfertility due to male factor. The wife is 38-year-old and the husband is 49 years old. The patient has no known medical illness with a body mass index (BMI) of 23 kg/m², while the husband is a smoker and drinks alcohol 2 to 3 units/day with a BMI of 24 kg/m².

The husband was diagnosed with severe asthenozoospermia of five percent (5%) motility despite the count of 16 million/ml and the morphology of normal sperms was eleven percent (11%). Two frozen thawed embryos transfer was performed. Routine β-hCG serial monitoring was started on day 16 after embryo transfer and her early pregnancy ultrasound scan at three weeks suggested an intrauterine gestational sac. After the 4th β-hCG reading that showed fluctuation (Table 1) necessitate more work out beside the transvaginal scan (TVS) which raise a suspicion of angular or cornual pregnancy. She was subsequently referred at week 6 post embryo transfer from the fertility centre to the tertiary hospital for second opinion.

Assessment of the patient at the centre revealed stable vital signs, her abdomen was soft with no tenderness or guarding felt upon palpation. Her β-hCG and transvaginal scanning were repeated in the hospital reveals a β-hCG level of 11282 IU/L and her TVS showed empty uterus with multiple fibroids. There was a left adnexal mass showing bagel sign with viable fetal echo of crown rum length (CRL) of 6 weeks+3d gestation. The right ovarian tissue looked normal with no free fluid in pouch of Douglas. The TVS findings are shown in Figure 1.

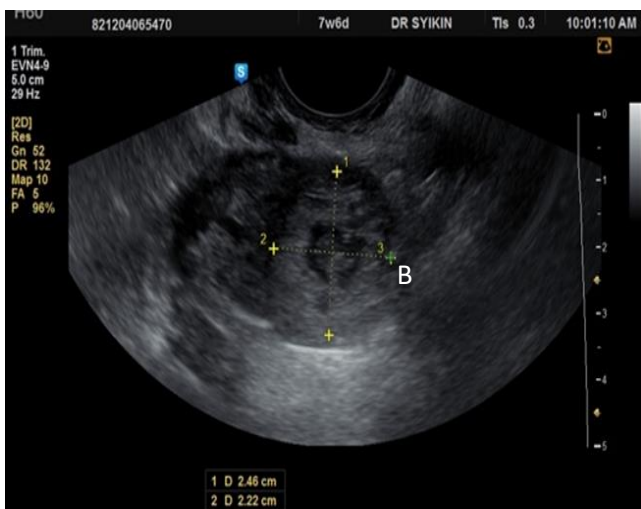


Figure 1: Adnexal mass with fetus showing CRL of 6w+ 3 (bagel sign).

The patient was informed regarding the ectopic location of her pregnancy and subsequently counselled for laparoscopy. The intraoperative finding showed left ovarian ectopic as seen in figure 2.

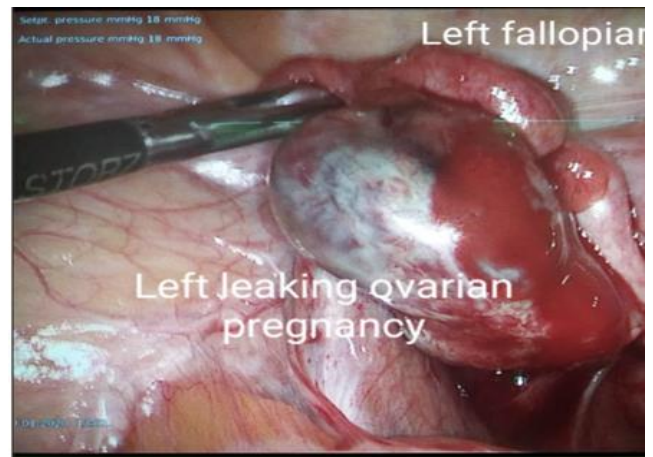

Figure 2: Intraoperative finding of ovarian ectopic with healthy left fallopian tube

The conceptus material was removed with partial oophorectomy to secure adequate haemostasis. The tissue samples were sent for histopathological examination. The right ovary and tube looked healthy as seen in figure 3.

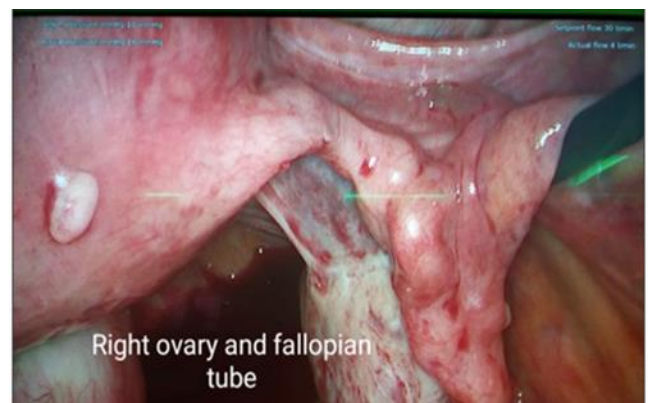


Figure 3: Intraoperative finding of right ovary and fallopian tube with small subserosal fibroid.

The postoperative period was uneventful, and the patient was discharged in good general condition with plan for follow up to review the histopathology report as well as serial β-hCG follow-up (Table 1).

Table 1: Timeline of pre & postoperative β-hCG level (IU/L)

Preoperative	
weeks	β-hCG
2 ^{+2d}	20
4	8285
5	4918
6	6152
6 ^{+3d}	11282
Postoperative	
Day	β-hCG
3	400.8
9	31.7
17	13.9
24	8.8

The histopathology report revealed ovarian tissue with presence of chorionic villi, trophoblasts and decidual tissue within the stroma. There was an ovarian follicle lined by granulosa and theca cells. No evidence of dysplasia or malignancy, which gives an impression of ovarian ectopic pregnancy. Figure 4.

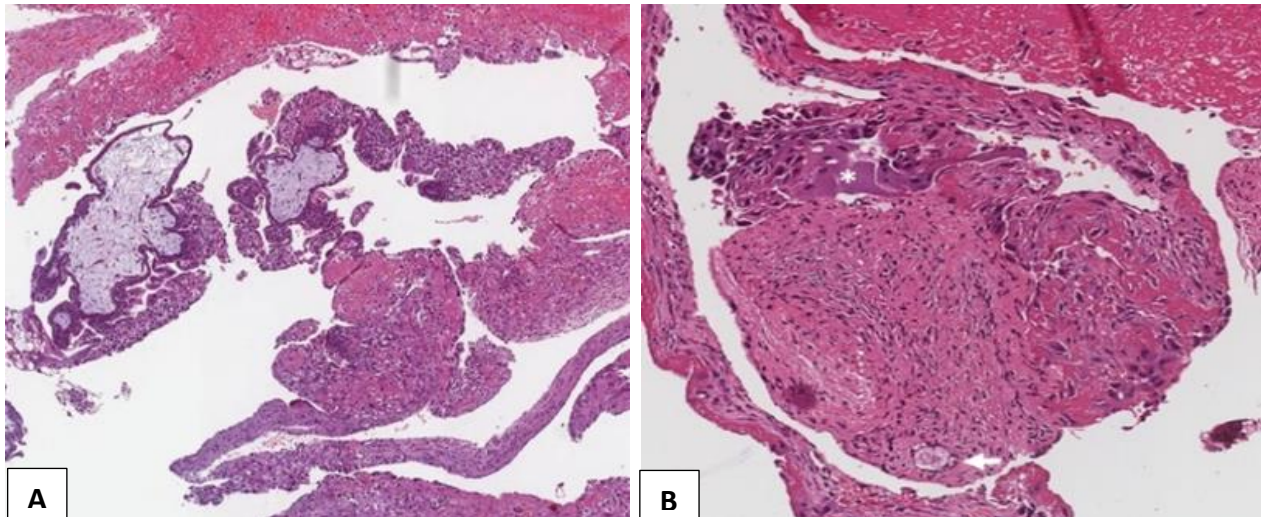


Figure 4: Histopathology of the specimen report. A. Chorionic villi and trophoblasts are seen within the ovarian stroma (H&E). B. Trophoblast (white *) are embedded within ovarian stroma. There is presence of primordial follicle (white arrow). Despite such an experience, the patient determined for another pregnancy and the successive embryo transfer achieves a viable intrauterine pregnancy.

Discussion

In IVF process, the early embryo is placed in the uterine cavity for the process of implantation to be accomplished [10]. In some cases, the embryo migrates through fallopian tube and presented as ectopic pregnancy [11]. The aetiology of this migration is unclear but retrograde tubal peristalsis can be detected during the menstrual cycle [12].

The patient has multiple uterine fibroid and it is not very well known if uterine fibroid can enhance the retrograde fallopian tube antiperistalsis or not. Tumour necrosis factor alpha (TNF- α) is a cell signalling protein involved in systemic inflammation which increases in women with symptomatic fibroids [13]. TNF- α might affect the smooth muscle tone or the ciliary activity of the endosalpinx secondary to inflammation [14].

Recognised EP risk factors are previous ectopic, age of above 35 years, pelvic inflammatory disease, smoking, ART, subfertility, previous pelvic surgery, low BMI, and current use or history of IUCD [11,7,6,8]. Fibroids are reported as a risk factor by some researchers [15], at the same time, women diagnosed with ectopic pregnancy may have no known risk factors [16]. In this case study, many recognised risk factors do exist such as the transfer of frozen embryo, age, and risk of being a secondary smoker. However, the subfertility was mainly due to male factor. Fibroids are not yet documented as a risk factor for EP.

Known risk factors for EP during ART correlated with the volume of fluid used in the transfer, site of positing of the embryo, patient position during the procedure, oestrogen levels after ovarian stimulation [4]. In mentioned case, the fertility centre uses low fluid volume & the pregnancy took place after frozen embryo transfer with no history of ovarian stimulation.

Majority of OEP presents with classical symptoms and signs of tubal ectopic pregnancy as abdominal pain and a complex adnexal mass by sonographic evaluation after which intraoperative diagnosis of OEP is made. In some cases, OEP is silent and can progress to abdominal pregnancy [6] which carries high mortality rate and multidisciplinary surgical approach [17]. An ultrasonic appearance of a wide echogenic ring with an internal echolucent area on the ovary is suggestive of OEP [18]. Early detection and treatment can spare a lot of risks to maternal health.

Because ART requires close monitoring, the patient was under β -hCG and sonographic monitoring. The fluctuation in the hormonal gave an alarm about the possibility of EP. Diagnostic criteria for OEP includes echogenic ring with anechoic area of the ovary, yolk sac or embryo less likely seen [1] (Goyal, 2014) in our case, there was a single viable fetus with CRL of 6w gestation with bagel sign which suggested extra-uterine pregnancy rather than initial diagnosis of cornual pregnancy, which necessitate the laparoscopic interference.

During the follow up of the patient, the histopathology finding supported the diagnosis of OPE according to Spiegelberg criteria that includes the presence of ovarian tissue attached to the gestation sac, as in figure 6.

It is agreed that treatment of choice for PEP is surgical removal of conceptus and preserving the ovarian tissue [1]. Sometimes partial oophorectomy is an acceptable alternative if needed to secure haemostasis. Others have reported successful conservative medical treatment with methotrexate [9]. Fetal heart activity considered as contraindication for Methotrexate administration, as in our case, but local instillation of methotrexate, KCl, or hyperosmolar glucose under ultrasound guidance and direct visualization of immediate cessation of fetal heart activity is also helpful [19].

Conclusion

Assisted reproductive technique is a risk factor for ectopic pregnancy. Ovarian ectopic pregnancy is a rare variant of EP, which is considered as diagnostic challenge. Follow up of ART cases is very helpful in early detection of abnormal findings. Early recognition & management gives chance for fertility preserving procedure & can decrease maternal morbidity & mortality.

Conflict of Interest

The authors declare no conflict of interest regarding the publication of this paper.

Acknowledgments

We wish to thank our patient for allowing us to share her unique clinical presentation. We also wish to express our gratitude to all

healthcare providers in SASMEC and the department of Obstetrics and Gynaecology, IIUM, Kuantan, Malaysia involved in her care.

References

- [1] Diagnosis & management of ectopic pregnancy. Elson CJ, Salim R, Potdar N, Chetty M, Ross JA, Kirk EJ on behalf of the Royal College of Obstetricians and Gynaecologists. UK: RCOG green top guideline, 2016, BJOG, pp. 15-55.
- [2] Assisted reproductive technologies (ART) in Canada: 2004 results from the Canadian ART Register. Gunby J, Bissonnette F, Librach C, Cowan L and Society, IVF Directors Group of the Canadian Fertility and Andrology. 2008, pp. 89:1123-32.
- [3] Ovarian Ectopic Pregnancy: A Clinical Analysis. Sotelo, C. 15(3), 224-227. 3, 2019, The Journal for Nurse Practitioners, Vol. 15, pp. 224-227.
- [4] Impact of different embryo loading techniques on pregnancy rates in in vitro fertilization/embryo transfer cycles. Halvaei I, Khalili MA, Razi MH, Agha-Rahimi A, Nottola SA. 2013; J Hum Reprod Sci, Vol. 6(1):, pp. 65-69.
- [5] Ectopic pregnancy following in vitro fertilization with embryo transfer: A single-center experience during 15 years. Cheng, L. Y., Lin, P. Y., Huang, F. J., Kung, F. T., Chiang, H. J., Lin, Y. J., & Lan, K. C. 2015, Taiwanese Journal of Obstetrics and Gynaecology.
- [7] Ovarian ectopic pregnancy: A 10 years' experience and review of literature. Goyal, L. D., Tondon, R., Goel, P., & Sehgal, A. 2014, Iranian Journal of Reproductive Medicine, pp. 12(12), 825.
- [8] ACOG. <https://www.acog.org/womens-health>. Ectopic pregnancy. [Online] Feb 2018. <https://www.acog.org/womens-health/faqs/ectopic-pregnancy>.
- [9] Low body mass index is associated with ectopic pregnancy following assisted reproductive techniques: a retrospective study. Cai, J., Liu, L., Jiang, X., Li, P., Sha, A., & Ren, J. 2020, BJOG: An International Journal of Obstetrics & Gynaecology.
- [10] Medical management of an ovarian ectopic pregnancy: a case report. Birge, O., Erkan, M. M., Ozbey, E. G., & Arslan, D. 2015, Journal of medical case report, pp. 1-4.
- [11] Embryo transfer to low uterine cavity. Waterstone J, Curson R and Parsons. 1991, Lancet J, pp. 337, 1413.
- [12] (2016). Ectopic pregnancy following in vitro fertilization: meta-analysis and single-center experience during 6 years. Muller, V., Makhmalieva, M., Kogan, I., Fedorova, I., Lesik, E., Komarova, E., & Ailamazyan, E. 2016, Gynecological Endocrinology, Vol. 32(sup), pp. 69-74.
- [13] Peristalsis and Antiperistalsis of the Human Fallopian Tube during Menstrual Cycle. Hugo S.Maia, Elsimar M. Coutinho. 1970, Biology of Reproduction, pp. 305-314.
- [14] The Role of Tumor Necrosis Factor α in the Biology of Uterine Fibroids and the Related Symptoms. Ciebiera M, Włodarczyk M, Zgliczyńska M, Łukaszuk K, Męczekalski B, Kobierzycki C, Łoziński T, Jakiel G. 2018, International Journal of Molecular Sciences., pp. (12), 3869.
- [15] Dual regulation of tumor necrosis factor- α on myosin light chain phosphorylation in vascular smooth muscle. Chen, M., Ma, L., Hall, J. E., Liu, X., & Ying, Z. 2015, American Journal of Physiology-Heart and Circulatory Physiology, pp. 398-406.
- [16] Risk factors for ectopic pregnancy in assisted reproduction., Strandell, A., Thorburn, J., & Hamberger, L. 1999, Fertility and sterility, pp. 282-286.
- [17] Bilateral Tubal Pregnancy without Known Risk Factor. Hyacinthe Zamané, Barnabé Yameogo, Paul Dantola Kain, François Gueswendé Xavier Kaboré, Yobi Alexis Sawadogo, Sibraogo Kiemtoré, Sidbewenné Yacinthe Kaboré, Blandine Bonané Thiéba, ". 2017, Case Reports in Obstetrics and Gynecology, p. 3.
- [18] Orabi, Mokhamed. <https://www.middleeastmedicalportal.com/undiagnosed-live-term-extra-uterine-abdominal-pregnancy>. [Online] 2020. <https://www.middleeastmedicalportal.com/undiagnosed-live-term-extra-uterine-abdominal-pregnancy/#:~:text=The%20most%20common%20complication%20of,approach%20when%20it%20is%20anticipated>.
- [19] Ovarian ectopic pregnancy: aetiology, diagnosis, and challenges in surgical management. 32(5), 472-474. Joseph, R. J., & Irvine, L. M. 2012, Journal of Obstetrics and Gynaecology, pp. 472-474.
- [20] Huber, W. J., & Frishman, G. N. Ovarian Ectopic Pregnancy. s.l.: Springer, Cham., 2015, pp. 93-99.
- [21] Frozen-thawed embryo transfer is associated with a significantly reduced incidence of ectopic pregnancy. Shapiro, B. S., Daneshmand, S. T., De Leon, L., Garner, F. C., Aguirre, M., & Hudson, C. 6, 2012, Fertility and sterility, Vol. 98, pp. 1490-1494.
- [22] JOSIE L. TENORE, M.D., S.M., Ectopic pregnancy. [Online] the American Academy of Family Physicians., 15 Feb. 2000. <https://www.aafp.org/afp/2000/0215/p1080.html>.
- [23] The role of tumor necrosis factor α in the biology of uterine fibroids and the related symptoms. Ciebiera, M., Włodarczyk, M., Zgliczyńska, M., Łukaszuk, K., Męczekalski, B., Kobierzycki, C., Łoziński, T., & Jakiel, G.. 2018, International Journal of Mol.



Open Access This article is licensed under a Creative Commons Attribution 4.0 International License, which permits use, sharing, adaptation, distribution and reproduction in any medium or format, as long as you give appropriate credit to the original author(s) and the source, provide a link to the Creative Commons license, and indicate if changes were made. The images or other third party material in this article are included in the article's Creative Commons license, unless indicated otherwise in a credit line to the material. If material is not included in the article's Creative Commons license and your intended use is not permitted by statutory regulation or exceeds the permitted use, you will need to obtain permission directly from the copyright holder. To view a copy of this license, visit <https://creativecommons.org/licenses/by/4.0/>.