



Lacrimal Gland Measurements in Patients with Graves' Ophthalmopathy

Elmas Yuksel ¹ MD, Abdullah Sukun ², MD

¹Department of Ophthalmology, Alaaddin Keykubat University Alanya Education and Research Hospital, Antalya, Turkey

²Department of Radiology, Baskent University Alanya Application and Research Center, Antalya, Turkey

*Corresponding author: Abdullah Sukun; [abdullah.sukun\[AT\]gmail.com](mailto:abdullah.sukun[AT]gmail.com)

Received 21 July 2022;

Accepted 29 July 2022;

Published 05 August 2022

Abstract

Purpose: Lacrimal gland sizes are increased in Graves' ophthalmopathy. Lacrimal gland herniation has been reported to be a simple radiological marker. This study aimed to investigate the relationship of lacrimal gland herniation (LGH) with lacrimal gland dimensions, proptosis, and hormonal parameters. **Methods:** Sixty-eight eyes of 34 patients with Graves' ophthalmopathy were evaluated. Lacrimal gland herniation, proptosis, the long and short axis of the lacrimal gland were measured in mm on the right and left sides. TSH, FT4, FT3, Anti-TPO and Anti-TG values of each patient were recorded. Multiple linear regression was applied to determine the factors affecting lacrimal gland herniation. **Results:** 21 female 13 male 34 patients were included in this study. The mean age of the patients was found to be 37.29±11.91 years. The regression model for LGH was found to be statistically significant. (R2 right eye :0.57 R2 left eye 0.51 p<0.001). The predictive variables for LGH were short diameter of the lacrimal gland and proptosis. No statistical significance was found in other variables (p<0.05). The equation showing right LGH in millimeters was found as -5.268+ Lacrimal gland short-axis x 1.271 + Proptosis x 0.284. The equation showing left LGH in millimeters was found as -3.598+ lacrimal gland short-axis x 0.937 + Proptosis x 0.292. **Conclusions:** Lacrimal gland herniation is associated with lacrimal gland short diameter and proptosis. Our findings support that lacrimal gland herniation may be an important and useful radiological marker in Graves' ophthalmopathy.

Keywords: lacrimal gland herniation, Graves ophthalmopathy, Thyroid-associated orbitopathy, MRI,

Introduction

Graves ophthalmopathy (GO) is the most common and most important ophthalmologic finding of Graves' disease. This chronic autoimmune condition affects the extraocular muscles, periorbital connective-fatty tissue and lacrimal gland [1]. The size of the lacrimal gland increases in Graves ophthalmopathy [2]. Graves' ophthalmopathy is the most common cause of proptosis in adult women, especially in those with positive thyroid antibodies. In Graves' ophthalmopathy, an increase in lacrimal gland volume was detected with CT [3]. In active graves ophthalmopathy, lacrimal gland surface area and lacrimal gland width in coronal and axial planes are increased with MRI. It has been reported that increased cytokines in active disease are associated with inflammatory involvement of the lacrimal gland [4].

In a study evaluating the Lacrimal Gland with 3T MR, length and width in the axial plane, length and width in the coronal plane were compared to the structures in the healthy control group, and it was reported that all measurements, except coronal length, increased significantly in patients with graves ophthalmopathy [5]. The lacrimal gland volume was investigated by CT in Korean Graves' ophthalmopathy (GO) patients, and a significant increase was found compared to the healthy control (HC) group. They reported that the volume of the lacrimal gland decreased with age, and there was no difference between gender and right-left [6]. In various studies, in which quantitative measurements were made with the lacrimal gland under CT guidance, it was found that the extraocular muscles and lacrimal gland volume were significantly higher in graves

ophthalmopathy compared to the control group [7,8]. Researchers have reported that measurements of orbital soft tissue volume and density using CT scans can be used as a reliable and feasible technique to induce active inflammation in patients with Thyroid-associated orbitopathy (TAO) [8].

Various classifications are used to distinguish active inflammation in Graves' ophthalmopathy. The most accepted one is the VISA classification-V (vision, dysthyroid optic neuropathy); I (inflammation, congestion); S (strabismus, motility restriction); A (appearance, exposure) [9]. Gagliardo et al [10], reported that lacrimal gland herniation may be useful in differentiating active and inactive ophthalmopathy of the graves in the early stages of the disease. Our aim in this study is to investigate whether there is a relationship between hormonal parameters between lacrimal gland herniation, proptosis values and lacrimal gland sizes.

Methods

This study was approved by the Clinical Research and Ethics Committee on May 26, 2021 (Decision Number 06-18). Due to the retrospective nature of the study, the requirement for written informed consent was waived.

Patients Selection

Orbital MRI reviews between 2014 and 2021 were screened through a retrospective review of the institution's database. Of the 270 MRI scans, 38 patients with Graves' ophthalmopathy were included. 2 patients were excluded due to artifactual MR examination and 2 patients were excluded due to lack of hormone levels.

Evaluation of MR images

MRI scans were done with 1.5 T Hitachi Echelon (Hitachi Medical Corporation Soto-Kanda, Chiyoda-ku, Tokyo, Japan). In our radiology clinic, orbital MR protocol consists of T2AX, T1AX, T2AX fat-suppressed (FS), Short Tau short time inversion recovery (STIR) COR, T2 SAG, T1AX/COR FS, Post contrast T1AX/COR FS sequences. Throughout the scan, the patient’s head was stabilized in a supine position and kept stationary. T2AX FS and Post contrast T1AX were chosen for the present study (T2AX FS acquisition

matrix: 320x212; slice thickness 3 mm; TR 3332 ms; TE 96 ms; ETL 15; NEX 2, Post contrast T1AX acquisition matrix: 320x204; slice thickness 3 mm; TR 664 ms; TE 13 ms; NEX 1), The lacrimal gland protruding in front of the interzygomatic line was defined as a lacrimal gland herniation (LGH). Right and left LGH and proptosis were measured in T2AX FS sequences. The axial length and width of the lacrimal gland were recorded on post-contrast FS T1 axial images. Measurements and definitions made are shown in figure 1 and 2.

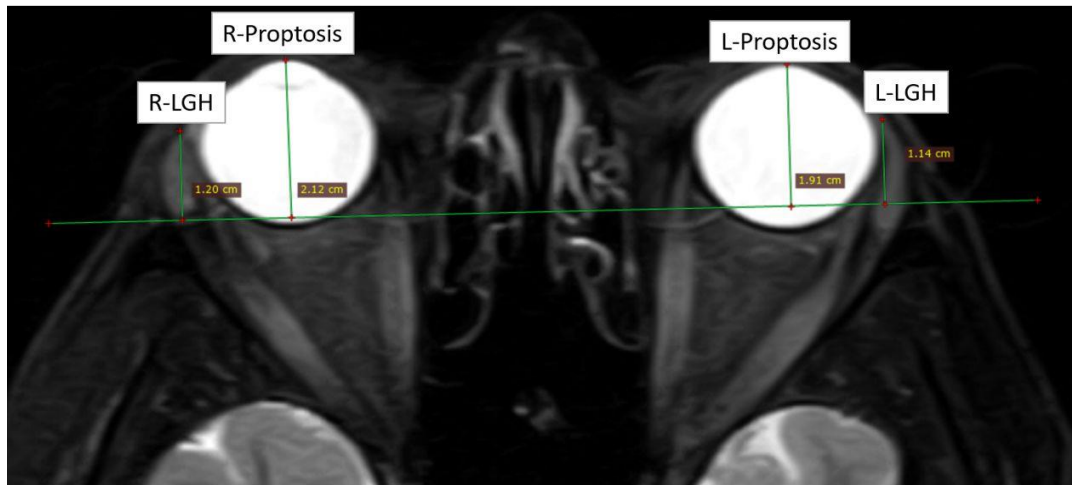


Figure 1: Lacrimal gland herniation and proptosis measurements on axial 3-mm-thick T2AX FS sequence. The lacrimal gland protruding anteriorly from the interzygomatic line was measured and defined as lacrimal gland herniation (LGH). In addition, proptosis measurements were made from the interzygomatic line to the anterior cornea.

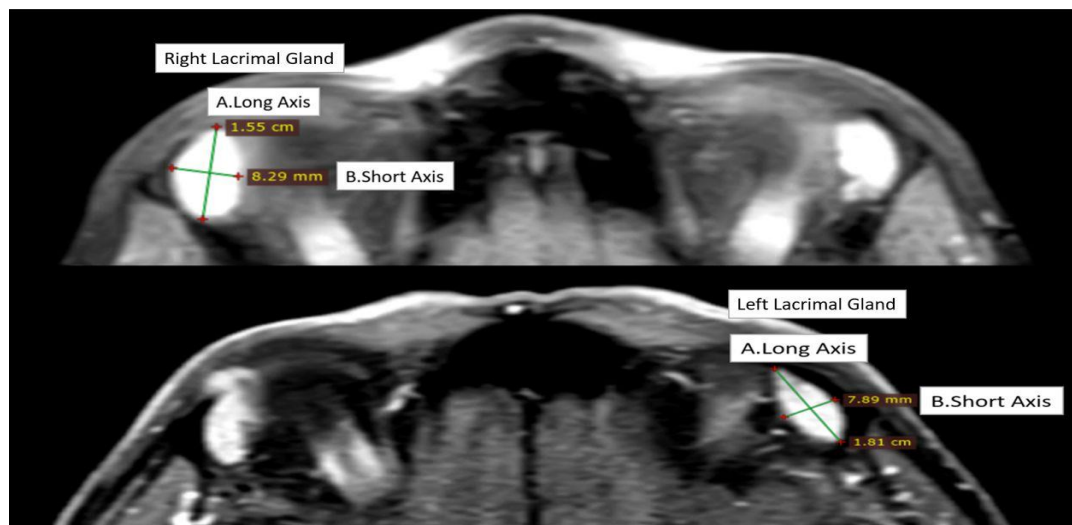


Figure 2: The short and long axis of the right and left lacrimal glands, which show bright homogeneous contrast enhancement, were measured in postcontrast fat-suppressed T1W sequences after gadolinium.

Examination of hormonal parameters

Serum TSH, FT3, FT4, Anti TPO and Anti TG were measured by Electro-chemiluminescence immunoassay device (E611 Roche Roche Cobas E601). Normal reference ranges in our laboratory are TSH: 0.27-4.2 mU/L, FT3: 2-4.4 ng/L, FT4: 0.93-1.7 ng/dl, Anti TPO: 0-34 IU/ml, Anti TG: 0-115 IU/ml.

Statistical analysis

The Statistical Packages for Social Sciences (SPSS Chicago, IL, USA) version 25 was used for data analysis. Multiple linear regression analysis was performed to explain lacrimal gland herniation. All variables were continuous. There is a linear relationship between lacrimal gland herniation and other independent variables. There were no significant outliers in the data set. No correlation was found between residual values and independent variables. Lacrimal gland herniation shows equal variance in all values of independent variables. Residual values are

approximately normally distributed. There is no significant multicollinearity between the independent variables. P value <0.05 was considered statistically significant.

Results

21 female 13 male 34 patients were included in this study. The mean age of the patients was found to be 37.29±11.91 years. The measurements of thyroid ophthalmopathy patients are presented in Table 1. A multiple linear regression model to explain lacrimal gland herniation was found statistically significant p<0.001. In the defined model, the short diameter of the lacrimal gland and proptosis were found to be significant in order of importance. The p-value of the short diameter of the lacrimal gland was 0.001 on the right and 0.004 on the left, the p-value of proptosis was 0.027 on the right and 0.023 on the left. These two independent variables explain 57% of the

variance on the right eye and 51% on the left eye. The equation showing right lacrimal gland herniation in millimeters was found as- $5.268 + \text{Lacrimal gland short-axis} \times 1.271 + \text{Proptosis} \times 0.284$. The

equation showing left lacrimal gland herniation in millimeters was found as- $3.598 + \text{lacrimal gland short axis} \times 0.937 + \text{Proptosis} \times 0.292$.

Table 1: MRI measurements of Lacrimal Gland Herniation, Proptosis, Lacrimal Glands Size

	Right Eye (n:34)	Left Eye (n:34)
Lacrimal Gland Herniation (mm)	8.74±2.48	8.54±2.24
Proptosis (mm)	20.46±2.82	20.10±2.73
Lacrimal Gland Size (mm)		
Long Axis	14.70±2.74	14.80±2.62
Short Axis	6.45±1.04	6.70±1.10

Table 2: Significant predictors for LGH in Multiple linear regression

	B	Std. Err.	t	Sig	%95 CI For B
Right Eye (Constant)	-3.598	2,206	-1.631		
LG Short Axis (mm)	0.937	0.304	3.085	0.004	0.317-1.556
Proptosis (mm)	0.292	0.122	2.387	0.023	0.042-0.541
Left Eye (Constant)	-5.268				
LG Short Axis (mm)	1.271	0.331	3.834	0.001	0.595-1.947
Proptosis (mm)	0.284	0.122	2.330	0.027	0.035-0.533

Table 3: Other Variables

	Median	P value Right Eye	P value Left Eye
TSH (mU/L)	0.03500	0.344	0.516
FT3 (ng/L)	9.9313	0.434	0.178
FT4 (ng/dl)	3.5482	0.060	0.176
Anti TPO (IU/ml)	162.08	0.564	0.880
Anti TG (IU/ml)	210.02	0.322	0.304
LG Long Axis (mm)	Mean		
Right Eye (mm)	14.70±2.74	0.133	
Left Eye (mm)	14.80±2.62		0.334

Discussion

In studies conducted in Graves' ophthalmopathy, it is known that the lacrimal gland is affected by active cytokines [7]. Recent studies have also reported that herniation of the lacrimal gland may be a useful marker for disease activity [10]. In our study, we found lacrimal gland short diameter and proptosis as significant predictive factors for lacrimal gland herniation. The short diameter of the lacrimal gland and increased proptosis have been associated with disease activity in previous studies [4,5]. Our findings also strengthen the view that lacrimal gland herniation will be a useful marker in determining disease activity.

Thyroid-associated orbitopathy (TAO) develops secondary to an inflammation in the orbit, the etiopathogenesis of which is not clearly elucidated. TAO occurs in hyperthyroid patients with Graves' disease (GD); however, cases of severe orbitopathy associated with Hashimoto's thyroiditis (HT) have been rarely described.

In a study to determine disease activity in extra-ocular muscles by fat fraction measurements and T2 relaxation map, a significant correlation was found between T2 relaxation times and signal intensity ratios. They reported that the fat fraction measurements were high in thyroid-related ophthalmopathy, and the decrease after treatment corresponded to the clinical activity score [11]. In our study, the CAS score of the patients could not be evaluated. In addition, MR imaging was performed with 1.5 T conventional sequences. It has been reported that OCT can be used to detect thickening in the anterior part of the medial rectus muscle when MRI cannot be performed in patients with Graves' ophthalmopathy [12].

Clinical Activity Score (CAS), ultrasonography (USG), computed tomography (CT), and magnetic resonance imaging (MRI) are used to evaluate Graves' orbitopathy (GO). SPECT+MRI, SPECT/CT, MRI and clinical activity score (CAS) were compared

in a study investigating the specifics of diagnostic methods. The specificities of the diagnostic methods were found to be 0.93, 0.89, 0.78, and 0.56, respectively [13]. Evaluation by CAS in patients with long-term GO is not always consistent with retro-orbital activity. CAS is sufficient to reflect disease activity in patients with short-term GO. Supplementation of CAS with orbital MRI would be valuable in selecting suitable active patients with long disease duration [14].

In current studies, the two-point Dixon T2WI offers better image quality than the fat-sat T2WI in MR examination. Dixon-EOM-SIR alone showed the highest staging accuracy. It is recommended to use the Dixon T2WI to evaluate TAO patients in clinical practice [15]. Treatment with the combination of orbital radiation and systemic glucocorticoids in Graves' ophthalmopathy is subjectively and objectively effective without severe toxicity for Asian Graves' ophthalmopathy [16]. Graves' ophthalmopathy (GO) is characterized by an autoimmune reaction to thyrotropin (TSH) receptors and is diagnosed by TSH receptor antibody (TRAb). Thyroid stimulating antibody (TSAb) titers have been reported to correlate with clinical activity score [17]. Aequorin TSAb levels were significantly associated with proptosis and signal intensity ratio of enlarged eye muscle evaluated by MRI before steroid pulse therapy, and the Aequorin TSAb test was more sensitive than conventional tests, especially in euthyroid GO.

The success of radiological imaging in predicting orbital inflammation and clinical activity has been investigated. The radiological diagnostic accuracy was 80.0% for IgG4-related ophthalmic disease, 77.3% for non-specific orbital inflammation (NSOI) and 73.2% for thyroid-eye-disease (TED). It was concluded that orbital imaging is required for the diagnosis of IgG4, NSOI and TED [18]. In this study, it was reported that Orbital CT, for which orbital imaging could not diagnose sarcoidosis, had a sensitivity of 50% and a specificity of 75.0% in predicting active TED using

clinical evaluation as the gold standard. Histogram analysis of T2 values has been used to detect early involvement of extraocular muscles (EOMs) in TAO patients and has been reported to be able to detect early involvement of EOMs in TAO before they are detected on conventional orbital MRI [19]. In another study, T2 signal intensity values and normalized ADC values were reported to be valuable MRI indicators of inflammatory activity in GO by detecting the involvement of EOMs. In addition, it has been reported that it is an ideal tool to monitor the effectiveness of anti-inflammatory therapy in patients with active stage GO, and n-ADC values, when combined with CAS, can be promising predictive factors in the determination of disease stages [20].

Limitations

In our study, most of the patients did not have data on Trab antibodies. Clinical examinations and CAS scores are not clearly documented in the hospital archives. For these reasons, these data could not be collected in our study.

Conclusions

Most studies used T2 relaxation maps, histogram analyzes, SIR values, Dixon T2WI images, and ADC measurements in MRI examinations to distinguish between active and inactive GO patients. Thyroid stimulating antibodies are the most recent antibodies in GO patients. Radiological imaging was able to distinguish between active and inactive in 70% of GO patients. Our findings showed that the most important predictors of lacrimal gland herniation are lacrimal gland short axis and proptosis. Both of these independent variables have been proven to be associated with disease activity in previous studies. Therefore, we think that lacrimal gland herniation is a simple and important radiological marker in GO patients.

List of abbreviations

GO: Graves ophthalmopathy
TAO: Thyroid-associated orbitopathy
TED: Thyroid-eye-disease
EOMs: Extraocular muscles
CAS: Clinical Activity Score
LGH: Lacrimal Gland Herniation
TSH: Thyroid-stimulating hormone
FT3: Triiodothyronine
FT4: Free thyroxine
Anti-TPO: Anti Thyroid peroxidase antibody
Anti-TG: Anti-thyroglobulin antibody

Declarations

Ethics approval and consent to participate

All procedures performed in the studies involving human participants were in accordance with the ethical standards of the Kafkas University Clinical Research and Ethic Committee (decision number 2021/06-18) and with the 1964 Helsinki Declaration.

Consent for publication

Not applicable.

Availability of data and material

The datasets used and/or analyzed during the study are available upon reasonable request.

Competing interests

The authors declare that they have no competing interests.

Funding

No funding was received for this study.

Authors' contributions

E.Y. shared in study conception and design, collecting patients' data and writing and correcting the manuscript and revision. A.S shared in study conception and design, acquisition of data, analysis and interpretation of data and drafting of manuscript. All authors read and approved the final manuscript.

References

- [1] Clauser LC, Tieghi R, Galie M, Franco F, Carinci F. Surgical decompression in endocrine orbitopathy. Visual evoked potential evaluation and effect on the optic nerve. *J Craniomaxillofac Surg.* 2012;40(7):621-5. doi:10.1016/j.jcms.2012.01.027.
- [2] Harris MA, Realini T, Hogg JP, Sivak-Callcott JA. CT dimensions of the lacrimal gland in Graves orbitopathy. *Ophthalmic Plast Reconstr Surg.* 2012;28(1):69-72. doi:10.1097/IOP.0b013e31823c4a3a.
- [3] Bingham CM, Harris MA, Realini T, Nguyen J, Hogg JP, Sivak-Callcott JA. Calculated computed tomography volumes of lacrimal glands and comparison to clinical findings in patients with thyroid eye disease. *Ophthalmic Plast Reconstr Surg.* 2014;30(2):116-8. doi:10.1097/iop.0000000000000015.
- [4] Huang D, Luo Q, Yang H, Mao Y. Changes of lacrimal gland and tear inflammatory cytokines in thyroid-associated ophthalmopathy. *Invest Ophthalmol Vis Sci.* 2014;55(8):4935-43. doi:10.1167/iovs.13-13704.
- [5] Hu H, Xu XQ, Wu FY, Chen HH, Su GY, Shen J et al. Diagnosis and stage of Graves' ophthalmopathy: Efficacy of quantitative measurements of the lacrimal gland based on 3-T magnetic resonance imaging. *Exp Ther Med.* 2016;12(2):725-9. doi:10.3892/etm.2016.3389.
- [6] Huh HD, Kim JH, Kim SJ, Yoo JM, Seo SW. The Change of Lacrimal Gland Volume in Korean Patients with Thyroid-associated Ophthalmopathy. *Korean J Ophthalmol.* 2016;30(5):319-25. doi:10.3341/kjo.2016.30.5.319.
- [7] Khu J, Freedman KA. Lacrimal gland enlargement as an early clinical or radiological sign in thyroid orbitopathy. *Am J Ophthalmol Case Rep.* 2017;5:1-3. doi:10.1016/j.ajoc.2016.10.005.
- [8] Byun JS, Moon NJ, Lee JK. Quantitative analysis of orbital soft tissues on computed tomography to assess the activity of thyroid-associated orbitopathy. *Graefes Arch Clin Exp Ophthalmol.* 2017;255(2):413-20. doi:10.1007/s00417-016-3538-0.
- [9] Dolman PJ. Grading Severity and Activity in Thyroid Eye Disease. *Ophthalmic Plast Reconstr Surg.* 2018;34(4S Suppl 1):S34-s40. doi:10.1097/iop.0000000000001150.
- [10] Gagliardo C, Radellini S, Morreale Bubella R, Falanga G, Richiusa P, Vadalà M et al. Lacrimal gland herniation in Graves ophthalmopathy: a simple and useful MRI biomarker of disease activity. *Eur Radiol.* 2020;30(4):2138-41. doi:10.1007/s00330-019-06570-5.
- [11] Das T, Roos JCP, Patterson AJ, Graves MJ, Murthy R. T2-relaxation mapping and fat fraction assessment to objectively quantify clinical activity in thyroid eye

- disease: an initial feasibility study. *Eye (Lond)*. 2019;33(2):235-43. doi:10.1038/s41433-018-0304-z.
- [12] De-Pablo-Gómez-de-Liaño L, Fernández-Vigo JI, Merino-Menéndez S, Duque-Muñoz M, Gómez-de-Liaño R. Correlation Between Optical Coherence Tomography and Magnetic Resonance Imaging of Rectus Muscle Thickness Measurements in Graves' Ophthalmopathy. *J Pediatr Ophthalmol Strabismus*. 2019;56(5):319-26. doi:10.3928/01913913-20190607-01.
- [13] Szumowski P, Abdelrazek S, Żukowski Ł, Mojsak M, Sykała M, Siewko K et al. Efficacy of (99m)Tc-DTPA SPECT/CT in diagnosing Orbitopathy in graves' disease. *BMC Endocr Disord*. 2019;19(1):10. doi:10.1186/s12902-019-0340-0.
- [14] Zhou M, Shen L, Jiao Q, Ye L, Zhou Y, Zhu W et al. ROLE OF MAGNETIC RESONANCE IMAGING IN THE ASSESSMENT OF ACTIVE THYROID-ASSOCIATED OPHTHALMOPATHY PATIENTS WITH LONG DISEASE DURATION. *Endocr Pract*. 2019;25(12):1268-78. doi:10.4158/ep-2019-0133.
- [15] Chen L, Hu H, Chen HH, Chen W, Wu Q, Wu FY et al. Usefulness of two-point Dixon T2-weighted imaging in thyroid-associated ophthalmopathy: comparison with conventional fat saturation imaging in fat suppression quality and staging performance. *Br J Radiol*. 2021;94(1118):20200884. doi:10.1259/bjr.20200884.
- [16] Ma Z, Ozaki H, Ishikawa Y, Jingu K. Improvement of the MRI and clinical features of Asian Graves' ophthalmopathy by radiation therapy with steroids. *Jpn J Radiol*. 2019;37(8):612-8. doi:10.1007/s11604-019-00846-y.
- [17] Hiromatsu Y, Eguchi H, Matsuo Y, Kato T, Tani J, Watanabe S et al. Role of a new bioassay for thyroid-stimulating antibodies (aequorin TSAb) in Graves' ophthalmopathy. *Endocr J*. 2020;67(3):347-52. doi:10.1507/endocrj.EJ19-0398.
- [18] Lee MJ, Hamilton BE, Pettersson D, Ogle K, Murdock J, Dailey RA et al. Radiologic imaging shows variable accuracy in diagnosing orbital inflammatory disease and assessing its activity. *Sci Rep*. 2020;10(1):21875. doi:10.1038/s41598-020-78830-0.
- [19] Liu P, Chen L, Wang QX, Luo B, Su HH, Yuan G et al. Histogram analysis of T2 mapping for detecting early involvement of extraocular muscles in patients with thyroid-associated ophthalmopathy. *Sci Rep*. 2020;10(1):19445. doi:10.1038/s41598-020-76341-6.
- [20] Liu X, Su Y, Jiang M, Fang S, Huang Y, Li Y et al. Application of Magnetic Resonance Imaging in the Evaluation of Disease Activity in Graves' Ophthalmopathy. *Endocr Pract*. 2021;27(3):198-205. doi:10.1016/j.eprac.2020.09.008.



Open Access This article is licensed under a Creative Commons Attribution 4.0 International License, which permits use, sharing, adaptation, distribution and reproduction in any medium or format, as long as you give appropriate credit to the original author(s) and the source, provide a link to the Creative Commons license, and indicate if changes were made. The images or other third-party material in this article are included in the article's Creative Commons license, unless indicated otherwise in a credit line to the material. If material is not included in the article's Creative Commons license and your intended use is not permitted by statutory regulation or exceeds the permitted use, you will need to obtain permission directly from the copyright holder. To view a copy of this license, visit <https://creativecommons.org/licenses/by/4.0/>.

© The Author(s) 2022