



One-Year Prospective Study Evaluating the Role of the WALANT Technique in Managing Upper Limb Trauma in the Emergency Room

Oussama Barchah *, Marouane Ait Rahou, Abdessalam Achkoun, Hanane El Haoury, Mohammed Madhar, Rachid Chafik, Youssef Najeb

Traumatology and Orthopedics Surgery Department, Cadi Ayyad University, Marrakech, Morocco.

*Corresponding author: Oussama Barchah; oussamabarchah@gmail.com

Received 25 March 2023;

Accepted 12 April 2023;

Published 15 April 2023

Abstract

Background: WALANT (Wide Awake Local Anesthesia No Tourniquet) is a technique recently developed by Lalonde. It has allowed surgeons to perform more procedures with a remarkable time gain and to reduce the cost. The objective of our study is to evaluate the interest of this technique in the management of upper limb trauma in the emergency room. **Results:** The study included 36 patients, 14 fractures and 22 wounds. The average waiting time in the emergency room was 82.9 minutes, the average time between anesthesia and incision was 37 minutes, and the average duration of the procedure was 37 minutes. Three patients whose procedure was prolonged required additional anesthetic, and no patient required sedation or general anesthesia. None of the patients required the use of a tourniquet. No complications were reported in these patients. 92% of patients were satisfied. **Discussion:** WALANT makes it possible to perform surgical procedures using only lidocaine and adrenaline in combination with bicarbonate and saline. The long-standing dogma about the involvement of adrenaline in ischemic necrosis of the fingers has been reconsidered by several authors. Several advantages have been reported in the various publications. This concerns the patient, the surgeon and the health care system. Thus, it allows to improve the result in tendon repairs and to verify the stability of the osteosynthesis intraoperatively. **Conclusion:** WALANT presented a solution to the shortage of medical staff during the COVID-19 pandemic by reducing the risk of contagiousness through the reduction of the number of staff in the OR and shortening the hospital stay.

Keywords: *Wide Awake Local Anesthesia No Tourniquet; Upper limb trauma; Emergency room; Patient satisfaction; Surgical procedures*

Introduction

WALANT (Wide Awake Local Anesthesia No Tourniquet) is a newer anesthesia technique that has gained popularity among orthopedic and plastic surgeons. It was developed by Dr. Lalonde in Canada, and it involves the use of Lidocaine and adrenaline in the surgical site to control bleeding without the need for a tourniquet. This technique has several advantages for patients, surgeons, and the health system, such as a clean operative field, shorter waiting time and hospitalization, reduced costs, and an alternative for patients who cannot have general anesthesia [1,2].

WALANT can be applied in both elective and emergency surgeries and is commonly used for procedures involving the hand, wrist, and fingers, such as root tunnels syndromes, trigger finger, and fractures. However, it has some limitations and contraindications, including patients with coagulopathy or on anticoagulants, those with allergies to any of the anesthesia components, or patients with a history of psychiatric disorders or aggressive behavior [3].

It is a safe and effective anesthesia technique, but it requires proper training and expertise to ensure optimal patient outcomes [4]. Surgeons and patients should discuss the benefits and limitations of this technique before deciding to use it for a particular procedure [3].

The purpose of this study is to assess the efficacy of this technique for upper extremity surgical emergencies, with a focus on the experiences of both patients and surgeons.

The results of this study could help to inform clinical practice by providing insights into the effectiveness and feasibility of the technique in question. This could ultimately lead to improved outcomes for patients who require emergency upper extremity surgery.

Materials and Methods

We conducted a one-year prospective descriptive study in the emergency department (ED) and enrolled consenting and cooperating patients presenting with hand, wrist, or forearm wounds, as well as ulna, lower extremity of the radius, and metacarpal fractures. Patients with phalanx fractures, zone 1 and 2 wounds, contraindications to the WALANT technique, anxiety, or those who declined the technique were excluded. We collected and analysed data from 36 patients, and the inclusion and exclusion criteria are detailed in the table below.

Table 1: inclusion and exclusion criteria

Inclusion criteria	Exclusion criteria
Hand, wrist, or forearm wounds. Fractures of the ulna, the lower end of the radius and the metacarpus. Consenting patients. Cooperating patients.	Fractures of the phalanges. Zone 1 and 2 wounds. Patients with contraindications to this technique anxious patients patients who have not accept this technique.

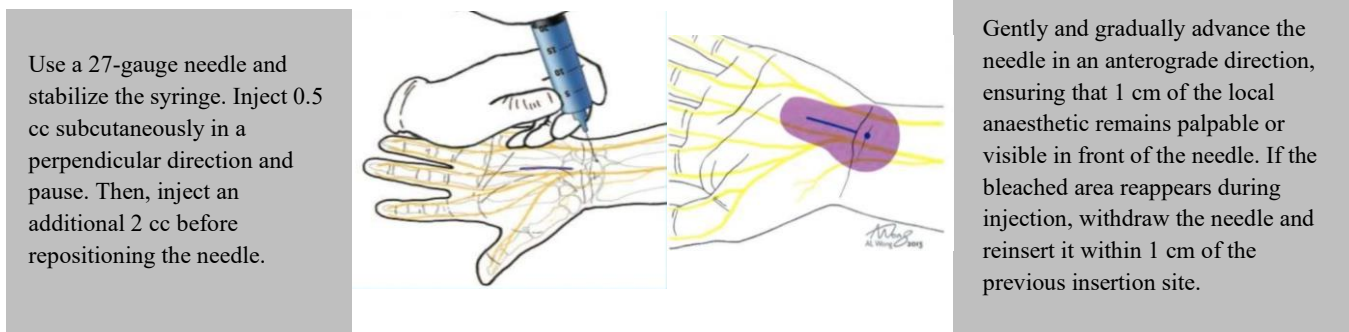


Figure 1 illustrates the process for administering WALANT anaesthesia, as described in [4].

We assessed the pain in the different times during the surgery using the visual analogue score (VAS) for pain and assessed the satisfaction of patients who underwent surgery using the WALANT technique by administering the EVAN-LR satisfaction questionnaire after the procedure [5]. This approach allowed us to gather data directly from patients about their experiences and perceptions of the surgery and recovery process.

Results

Table 2: descriptive results for continuous variables

Variables	Minimum	Maximum	Mean	SD
Age	21	61	35.97	12.519
Waiting time in the ER (minutes)	28	270	82.86	57.596
Time between anaesthesia and incision (minutes)	25	50	37.00	7.899
Surgery time (minutes)	10	180	61.58	44.233
VAS at the time of the incision	0	0	.00	.000
VAS during the surgery	0	2	.14	.487
VAS 2 H after the surgery	0	4	.36	.961

The most found diagnosis were Lower extremity fracture of the radius in 19.4% of our patients followed by metacarpus fractures and dorsal Hand wound area 6 in 13.9% of cases. The least found diagnosis was palmar forearm wounds in 2.8% cases.

Three patients required additional anesthesia due to prolonged procedures, but none of the patients required conversion to sedation or general anesthesia. None of the patients required the use of a tourniquet.

We conducted a study to assess the efficacy of the WALANT technique for upper extremity surgical emergencies, involving 36 patients with 14 fractures and 22 wounds. The mean age of the patients was 35.97 years, with a greater proportion of male than female patients. The average waiting time in the emergency room was 82.9 minutes, and the mean time between anaesthesia and incision was 37 minutes. Visual Analog Scale (VAS) scores were assessed at the time of incision, during the surgery, and 2 hours after the surgery. The results of the continuous variables can be found in Table 2.

No complications in the patients who underwent surgery using the WALANT technique were reported, Additionally, 92% of the patients reported being satisfied with their experience.

Table 3 summarizes the different results assessed. Through Figures 2 to 4, we present a visual depiction of the steps involved in the WALANT surgery performed on one of our patients.

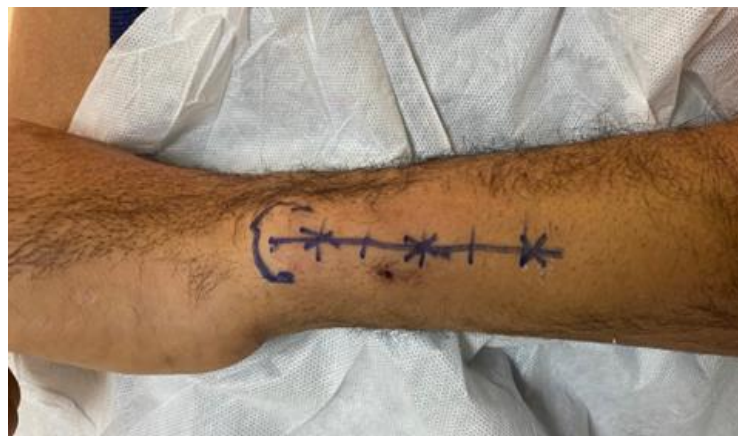

Figure 2: Approach marking for ulnar fracture. Subperiosteal injection points of the anaesthetic marked with red stars.

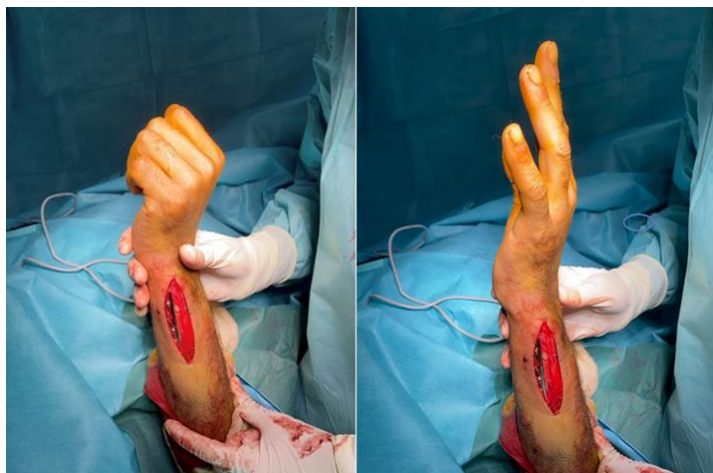

Figure 3: Verification of the stability of osteosynthesis during surgery to facilitate early rehabilitation.

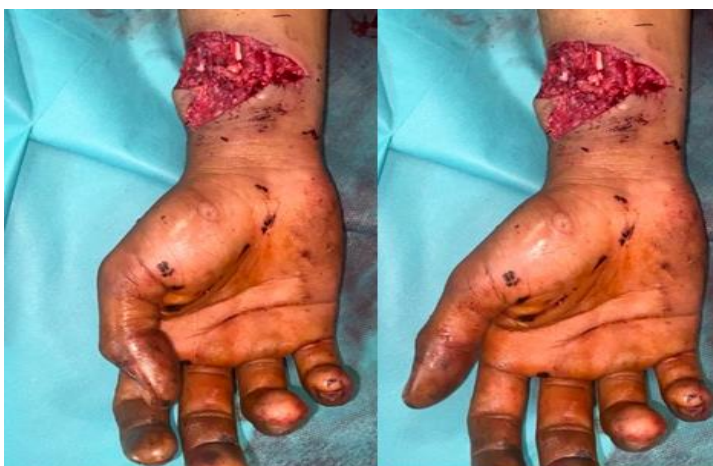

Figure 4: Assessing the intraoperative quality of the tendon suture following the repair of the flexor pollicis longus tendon using the WALANT technique.

Table 3: Continuous variables results

Variables	%
Gender	
Male	72.2
Female	27.8
Diagnosis	
Hand wound: palmar area 3	5.6
Hand wound: palmar area 4	11.1
Hand wound: palmar area 5	5.6
Hand wound: dorsal area 5	5.6
Hand wound: dorsal area 6	13.9
Hand wound: dorsal area 7	8.3
Forearm wound: dorsal	8.3
Forearm wound: palmar	2.8
Lower extremity fracture of the radius	19.4
Ulna fracture	5.6
Metacarpus fractures	13.9
Addition of anesthesia	
no	91.7
yes	8.3
Tourniquet use	
no	100
yes	0
Conversion to general anesthesia	
no	100
yes	0
Attention	
less than expected	5.6
as expected	30.6
more than expected	36.1

much more than expected	27.8
Information	
less than expected	2.8
as expected	36.1
more than expected	36.1
much more than expected	25.0
Pain	
less than expected	52.8
much less than expected	47.2
Comfort	
as expected	33.3
more than expected	41.7
much more than expected	25.0

Discussion

According to the data in the literature, the Walant technique has shown its interest in several interventions, notably wounds and fractures of interest to the upper limb, which represent a frequent situation in emergencies, such as wounds of the hand and wrist (spaghetti wrist), fractures of the metacarpals, phalanges, and the lower extremity of the radius [1,2,6-8].

It allows surgeons to carry out surgical procedures using only lidocaine and adrenaline by associating bicarbonate and saline at different dilutions depending on the duration of the procedure and the surgical indication (fracture vs. wound) [6,8-10].

The belief that reigned for a long time on the involvement of adrenaline in ischemic necrosis of the fingers has been reconsidered

by several, it was found that there was no significant difference in the incidence of ischemic necrosis between patients who received local anesthesia with adrenaline and those who received local anesthesia without adrenaline for finger surgery [11,12].

According to his studies Denkler et al [12] on a series of 40 cases with finger necrosis over 120 years of which none used adrenaline and that procaine was the substance involved in their necroses. The use of phentolamine as an antagonist to adrenaline in phalangeal surgery under WALANT has been used by several practitioners. Its use is not always systematic, but it is preferable to have it on hand in case of need.

The WALANT technique represents several advantages for the patient and for the surgeon, these have been grouped in the following table [8]:

Table 4: Advantages of the WALANT technique.

ADVENTAGES	
Patient	<ul style="list-style-type: none"> • Economical: no need for additional charges for anesthesia, complementary examinations (biological check-up, EKG.) • No pricking for sampling or venipuncture • Time saving: Outpatient surgery • The patient can communicate with the surgeon during the procedure. • The patient can see the result of the surgery during the procedure motivating the patient to adhere to the advice of his doctor and to the rehabilitation and by involving him in his care and his healing process. • The absence of tourniquet and its discomfort • The patient does not change his medication, especially for diabetics. • The patient can put himself in a comfortable position since there is no tourniquet and no monitoring or anesthesia equipment. • a solution for patients with a contraindication to general anesthesia
Surgeon	<ul style="list-style-type: none"> • Less medical and paramedical staff. • More patients to pass for the same duration. • Education of the patient during the procedure for a better result and fewer complications. • The patient can actively mobilize, allowing the surgeon to make the necessary adjustments to the tendons and bone. • Ease of operating on patients with multiple defects. • THE SAFEST SEDATION IS NO SEDATION

As with any other medical procedure, the use of WALANT has certain limitations and contraindications, which are summarized in the table below [8]:

Table 5: Contraindications of the WALANT technique.

Contraindications	
Absolut	<ul style="list-style-type: none"> • Lack of consent • Uncooperative
Relatives	<ul style="list-style-type: none"> • Anxiety • Needle phobia • Peripheral vascular disease • Coagulopathy • Hypersensitivity to lidocaine • Ongoing infection. This has been questioned by the study of Enechukwu et al [13] • Polytrauma • Lack of staff, training, appropriate facilities • Anticoagulants (controversial)

The practical applications of this technique are multiple. In tendon repairs, this technique has the advantage of allowing the surgeon to test the success of his sutures in cooperation with the patient by active flexion-extension movements. This makes it possible to detect the gap between the two ends during the operation. This is a major factor of rupture, and thus adjust the tension of the sutures. It allows us to see the passage of the repaired tendon in the pulleys and thus to make the necessary adjustments to them. It also allows us to verify that the sheath has not been caught in the tendon sutures and that the latter slide perfectly in the sheath. If the patient can make a point with his or her hand intraoperatively, this will allow him or her to begin early mobilization of the hand by means of half a fist (45 degrees for each MCP, IPP, IPD joint) [1,6].

This technique can be applied even for multiple tendon repairs in spaghetti wrists with vascular and nerve lesions if the duration of the procedure does not exceed 6-10h. This was reported in the publication of Arik et al in a study involving 13 wrist wounds operated on under Walant anesthesia and that the result was satisfactory [7].

In the case of fractures, the stability of our osteosynthesis can be checked intraoperatively during active movements of the patient with the help of a vibration amplifier. This makes it possible to detect rotational disorders in phalangeal fractures. Thus, early rehabilitation can be initiated in patients using Kirschner wires.

Other pathologies can be treated under Walant, such as: root canal syndromes (carpal tunnel, ulnar canal), finger protrusion, dequervain's disease, tendon transfers, rheumatic diseases of the hand.

Lalonde described a technique to reduce the pain due to the injection of the anesthetic product [14]:

Step 1: Buffering of lidocaine and epinephrine with 8.4% bicarbonate

Step 2: Warming of the local anesthetic

Step 3: Distract the patient or the injection area by touch, pressure, pinch or ice.

Step 4: Use of a 27-gauge needle

Step 5: Stabilize the syringe to prevent needle oscillation.

Step 6: Inject 0.5 cc perpendicularly subcutaneously and pause until the patient says that the pain of the needle has disappeared.

Step 7: Injection of an additional 2 cc before moving the needle, then anterograde movement very slowly with 1 cm of local anesthetic still palpable or visible in front of the needle

Step 8: Reinsertion of the needles within 1 cm of the bleached areas

Step 9: Learn from all patients by asking them to note the number of times they felt pain during the injection.

Studies have raised the interest of this technique during the COVID 19 pandemic. During this period, resources were directed towards the resuscitation services (resuscitator, anesthetist, respirator, etc.). It allowed for a reduction in the number of staff in the operating room (surgeon and nurse), a reduction in the waiting time in the emergency room, the duration of the procedure, no hospitalization, and fewer respirators were required. Decrease of the risk of contagiousness in hospitals and saturation of beds, allowing a better adaptation to the current circumstances during the pandemic COVID-19 [15].

Conclusions

The WALANT tourniquet-free local anesthesia has experienced a great increase in recent decades. It has allowed the realization of more surgical interventions. To reduce the risks linked to anesthesia. And to spare the patient the discomfort related to the tourniquet. It also has a major economic impact on the patient and on the health system.

The practical applications in trauma pathology of the upper limb are constantly developing. In addition to trauma pathology, scheduled

orthopedic surgery has also benefited from this technique. The different authors were unanimous on the positive impact of this technique during the COVID-19 pandemic.

Ethics approval and consent to participate.

The study was conducted in accordance with the World Medical Association Declaration of Helsinki. Informed consent was obtained from all the participants of this study.

Data Availability

The data that supports the findings of this study are available from the corresponding author upon reasonable request

Conflicts of Interest

The author(s) declare(s) that there is no conflict of interest regarding the publication of this paper.

Funding Statement

None

Authors' contributions

The study protocol was developed by OB with the assistance of HE, MA, AA, and MM facilitated successful data collection and reviewed the data collection forms. OB performed the statistical analysis with the review of RC. Manuscript writing was completed by OB and validated by YN. The manuscript was reviewed and approved by all authors prior to publication.

Acknowledgments

We would like to express our gratitude to all the patients who participated in this study and made this research possible. We are also thankful to the medical and nursing staff of the emergency department for their support and cooperation throughout the study. Lastly, we thank our colleagues who provided valuable insights and feedback during the preparation of this manuscript.

References

- [1] D. Lalonde, "How the wide-awake approach is changing hand surgery and hand therapy: Inaugural AAHS sponsored lecture at the ASHT meeting, San Diego, 2012," *Journal of Hand Therapy*, vol. 26, no. 2, pp. 175–178, 2013, doi: 10.1016/j.jht.2012.12.002.
- [2] D. H. Lalonde, "Conceptual origins, current practice, and views of wide-awake hand surgery," *Journal of Hand Surgery: European Volume*, vol. 42, no. 9, pp. 886–895, 2017, doi: 10.1177/1753193417728427.
- [3] D. Lalonde, "Wide awake local anaesthesia no tourniquet technique (WALANT)," *BMC Proc*, vol. 9, no. S3, pp. 1–2, 2015, doi: 10.1186/1753-6561-9-s3-a81.
- [4] D. H. Lalonde and A. Wong, "Dosage of local anesthesia in wide awake hand surgery," *Journal of Hand Surgery*, vol. 38, no. 10, pp. 2025–2028, Oct. 2013. doi: 10.1016/j.jhsa.2013.07.017.
- [5] V. Meunier, O. Mares, Y. Gricourt, N. Simon, P. Kouyoumdjian, and P. Cuvillon, "Patient satisfaction after distal upper limb surgery under WALANT versus axillary block: A propensity-matched comparative cohort study," *Hand Surg Rehabil*, vol. 41, no. 5, pp. 576–581, 2022.
- [6] D. Lalonde, "Minimally invasive anesthesia in wide awake hand surgery," *Hand Clin*, vol. 30, no. 1, pp. 1–6, 2014, doi: 10.1016/j.hcl.2013.08.015.

- [7] H. O. Arik, T. Coskun, and O. Kose, "Management of spaghetti wrist under WALANT technique," *Hand Surg Rehabil*, vol. 40, no. 5, pp. 655–659, 2021, doi: 10.1016/j.hansur.2021.06.006.
- [8] M. J. Fish and H. B. Bamberger, "Wide-awake Local Anesthesia No Tourniquet (WALANT) Hand Surgery," *StatPearls*. 2021. [Online]. Available: <http://www.ncbi.nlm.nih.gov/pubmed/34033408>
- [9] A. DELEUZE, L. DELAUNAY, and M. GENTILI, "Anesthésie locorégionale pour la chirurgie de la main," *Ann Fr Anesth Reanim*, vol. 23, no. 8, pp. 845–849, 2004, doi: 10.1016/s0750-7658(04)00286-2.
- [10] N. O'Neill et al., "Use of Wide-Awake Local Anaesthetic No Tourniquet (WALANT) in upper limb and hand surgery: A systematic review protocol," *Int J Surg Protoc*, vol. 20, pp. 8–12, 2020, doi: 10.1016/j.isjp.2020.03.001.
- [11] S. Chowdhry, L. Seidenstricker, D. S. Cooney, R. Hazani, and B. J. Wilhelmi, "Do not use epinephrine in digital blocks: Myth or truth? part II. A retrospective review of 1111 cases," *Plast Reconstr Surg*, vol. 126, no. 6, pp. 2031–2034, Dec. 2010, doi: 10.1097/PRS.0b013e3181f44486.
- [12] K. Denkler, "A comprehensive review of epinephrine in the finger: to do or not to do," *Plast Reconstr Surg*, vol. 108, no. 1, pp. 114–24, 2001.
- [13] A. O. M. Enechukwu, F. Bucher, K. Dastagir, A. Jokuszies, P. M. Vogt, and S. Könniker, "Treatment of hand infections using WALANT -when the anesthesiologist is not available: A retrospective cohort study," *Annals of Medicine and Surgery*, vol. 71, no. November, p. 102993, 2021, doi: 10.1016/j.amsu.2021.102993.
- [14] A. R. Strazar, P. G. Leynes, and D. H. Lalonde, "Minimizing the pain of local anesthesia injection.," *Plast Reconstr Surg*, vol. 132, no. 3, pp. 675–684, Sep. 2013, doi: 10.1097/PRS.0b013e31829ad1e2.
- [15] D. Hobday, T. Welman, N. O'Neill, and G. S. Pahal, "A protocol for wide awake local anaesthetic no tourniquet (WALANT) hand surgery in the context of the coronavirus disease 2019 (COVID-19) pandemic," *Surgeon*, vol. 18, no. 6, pp. e67–e71, 2020, doi: 10.1016/j.surge.2020.06.015.



Open Access This article is licensed under a Creative Commons Attribution 4.0 International License, which permits use, sharing, adaptation, distribution and reproduction in any medium or format, as long as you give appropriate credit to the original author(s) and the source, provide a link to the Creative Commons license, and indicate if changes were made. The images or other third-party material in this article are included in the article's Creative Commons license, unless indicated otherwise in a credit line to the material. If material is not included in the article's Creative Commons license and your intended use is not permitted by statutory regulation or exceeds the permitted use, you will need to obtain permission directly from the copyright holder. To view a copy of this license, visit <https://creativecommons.org/licenses/by/4.0/>.

© The Author(s) 2023