



# Atypical Teratoid Rhabdoid Tumor of the Pineal Region in a 33-Month-Old Child: A Case Report

Macias Grageda M. A.<sup>1</sup> , Montenegro Salcedo J. A.<sup>1</sup> , Rodríguez Ruiz J. A.<sup>2</sup> , Sánchez Terán A.<sup>3</sup> ,  
García Gonzalez O.<sup>4</sup> , Lozada Hernandez E.<sup>5</sup>

<sup>1</sup>General Surgery Resident, Hospital Regional de Alta Especialidad del Bajío, León, Gto, México.

<sup>2</sup>General Surgery Resident, Hospital General Regional de Querétaro “El Marqués”, Ciudad de México, México.

<sup>3</sup>General Surgery Resident, Hospital Regional de Alta Especialidad del Bajío. León, Gto, México.

<sup>4</sup>Chief of Pediatric Neurosurgery Service, Hospital Regional de Alta Especialidad del Bajío. León, Gto, México.

<sup>5</sup>Chief of the Investigation Department, Hospital Regional de Alta Especialidad del Bajío. León, Gto, México.

\*Corresponding author: Rodríguez Ruiz J. A.; [jorge\\_alr27@hotmail.com](mailto:jorge_alr27@hotmail.com)

Received 30 August 2023;

Accepted 20 September 2023;

Published 24 September 2023

## Abstract

**Purpose:** The present article describes a patient with an atypical teratoid/rhabdoid tumor of the pineal region and a literature review about this uncommon pathology. **Methods:** Literature review about Atypical Teratoid Rhabdoid Tumor between March and July of 2023 using 7 databases: Web of Science, Pubmed, Cochrane Library, SCOPUS, Science Direct, Clinical key and Medscape. **Clinical features:** A 33-month-old patient with an Atypical Teratoid Rhabdoid Tumor (ATRT) of the pineal region presented headache, VI cranial nerve paralysis, bilateral ataxia and loss of sphincters control during 3 months. **Intervention:** Endoscopic ventriculostomy with biopsy that reported ATRT. **Conclusions:** Recent statistics show that this tumor has been underdiagnosed throughout the time and evaluation of surgical material by a neuropathologist is required for its correct diagnosis.

**Keywords:** *Atypical Teratoid Rhabdoid Tumor, Pineal ATRT, Neoplasms of the pineal region, Central nervous system tumor*

## Introduction

The atypical Teratoid Rhabdoid Tumor was first described as a distinct type of central nervous system (CNS) rhabdoid tumor in 1987 and it was further described in 1996, affecting children younger than 3 years old with a generally poor prognosis [1]. 90% of ATRT cases were attributed to the mutation or deletion of chromosome 22q [2].

ATRT is extremely rare and represents less than 10% of all CNS tumors in pediatric patients [3]. Its most frequent location is in the infratentorial region (68%) and its worldwide incidence is 0.7 per 100,000 habitants. This tumor often occurs in the posterior fossa with only rare studies reporting ATRT in the pineal region. When it's diagnosed, one third of the patients have evidence of dissemination in the cerebrospinal fluid (CSF) [4]. Recent reports show that ATRT contributes to almost 6% - 7% of all CNS tumors in patients younger than 7 years old [5,6,7].

The most common clinical presentation of ATRT in a young child with CNS tumor is macrocephaly, hydrocephalus, seizures, headache, nausea, vomit and dizziness, although focal neurological deficits are relatively uncommon [8].

The radiological characteristics of an ATRT in MRI, is a large, heterogenous and expansive lesion with cystic, necrotic and hemorrhagic areas [9-11] making it indistinguishable from a medulloblastoma or a neuroectodermal tumor, therefore, the histopathology along with immunohistochemistry is necessary for a definitive diagnosis [1,2,12,13].

ATRT has a complex histopathological diagnosis, since immunohistochemical tests are needed such as an epithelial membrane antigen, glial fibrillary acid protein, synaptophysin, among others [14].

There's a large variety of treatments that literature describes including surgical procedures, chemotherapy and radiotherapy adjuvant with different rates of survival [15].

We present the first case report of an ATRT in the pineal region from the Hospital Regional De Alta Especialidad Del Bajío, Leon, Gto, México.

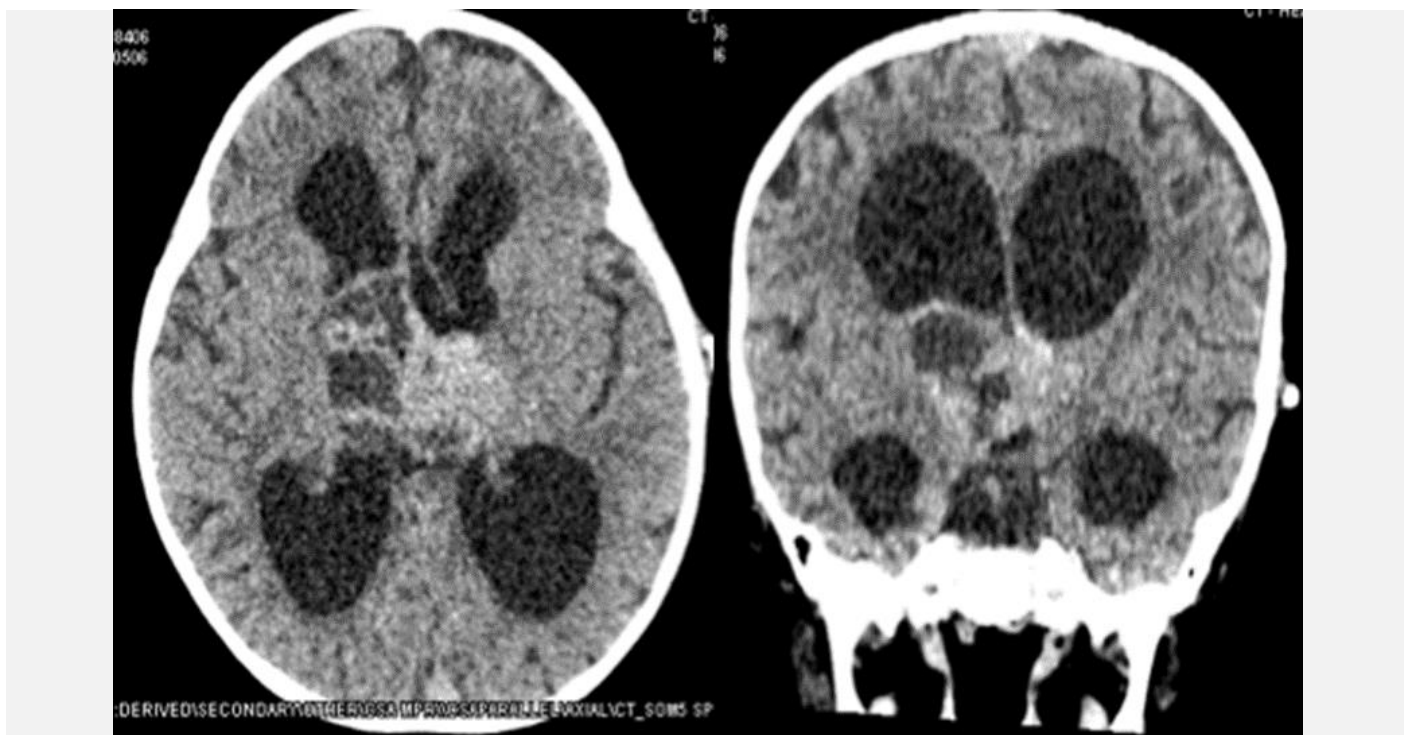
## Case description

A 33 month old male began his symptoms in 2017 with progressive headache, loss of eye movement characterized by bilateral paralysis of the VI cranial nerve, bilateral ataxia, loss of head support and sphincter control and intracranial hypertension symptoms. A CT scan and MRI showed a lesion with heterogeneous signal intensity and contrast enhancement in the pineal region (Figs 1,2).

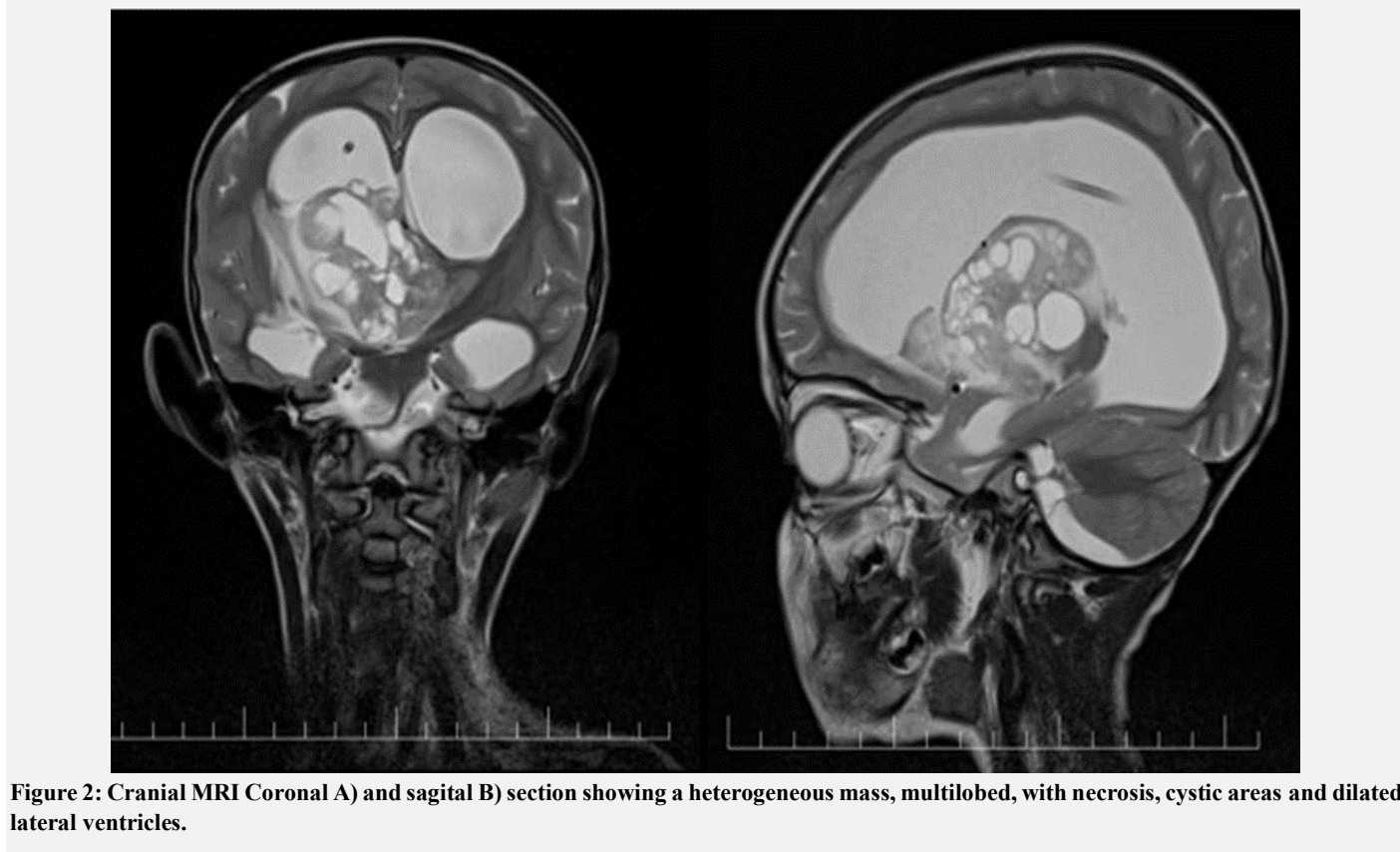An endoscopic ventriculostomy of the third ventricle and biopsy was performed. The histopathological result confirmed that the lesion corresponded to a ATRT by means of immunohistochemical techniques, positive to: Epithelial membrane antigen (EMA), Glial fibrillary acid protein (PAGF), focally to actin (HHF35), synaptophysin (SYN), neuronal specific enolase (ENE) and CD99 (Fig 3).

The patient presented post-surgical neuroinfection, with nuchal rigidity and irritability. The ventriculoperitoneal shunt valve was replaced for an external shunt while the neuroinfection was

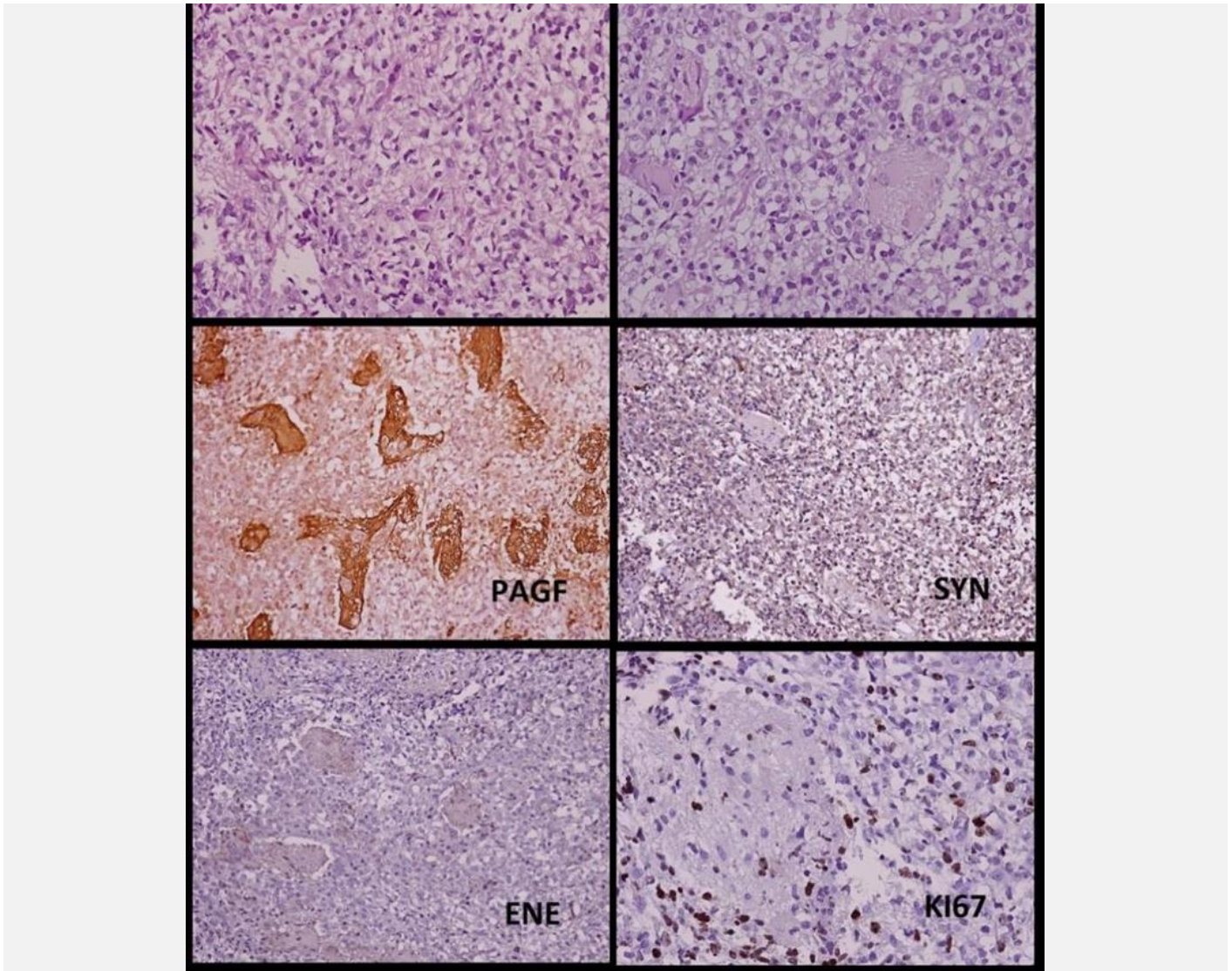
treated with antibiotics. The replacement was performed after the CSF came negative, and the patient began chemotherapy, followed up for 6 months until passed away.



**Figure 1:** CT scan A) Axial section at the level of the 3rd ventricle showing a tumor lesion with areas of necrosis. B) Coronal section showing dilation of the ventricular system and lesion in the pineal region.



**Figure 2:** Cranial MRI Coronal A) and sagittal B) section showing a heterogeneous mass, multilobed, with necrosis, cystic areas and dilated lateral ventricles.



**Figure 3: Histological section of Rhabdoid tissue with fasciculated immature areas and loose cells interspersed with dense collagen, cells with abundant pale pink cytoplasm, clear and vacuolated, a round prominent nucleus of scattered chromatin.**

## Discussion

Pineal tumors are relatively rare CNS lesions, with a predilection for the pediatric population. Establishing an accurate histologic diagnosis is critical for effective treatment of these tumors. Aggressive tumor resection is indicated for ATRT and surgery should typically be followed by chemotherapy or radiation [16,17].

Although ATRT can occur in any part of the nervous system, approximately 50% of cases occur in the posterior fossa. Male patients are slightly more affected than females, approximately 1.5:1. Because of its malignancy ATRT can spread and travel via CSF in the early stages, 30-40% of patients present metastases at the time of detection [18,19].

According to the reviewed literature, this type of tumor is very rare and there's a higher survival rate with increasing age at the diagnosis.

Two studies of the European Rhabdoid Registry reported 4 pineal ATRT out of a total of 62 patients and 5 pineal ATRT out of 143 patients with SNC tumors respectively, confirming the unusual presentation of this pathology [20,21].

The histopathological characteristics include presence of polygonal cells with roughly ovoid vesicular nuclei; prominent single and fairly central nucleoli; variable amounts of eosinophilic cytoplasm, and hyaline globular cytoplasmic inclusions in scattered cells [22,23]. Also, the immunohistochemistry and histopathological analysis shows a poorly differentiated malignant neoplasm, with this analysis is possible to visualize cells with a prominent nucleoli and

broad cytoplasm, large hyperchromatic nuclei, associated with numerous mitoses, and apoptosis, as well as loss of integrase interactor-1 (INI-1), BRG1 protein, and a high Ki-67 proliferation index. ATRT can occur virtually in all locations of the central nervous system, including the pineal and suprasellar regions [24,25].

Treatment is based on total or subtotal resection, followed by chemotherapy and radiotherapy. Due to the proximity of the pineal region to the vein of Galen's draining system and the quadrigeminal plate the surgical resection of ATRT of this region is challenging [26]. The survival rate of these patients is less than 46.8% in the following year [1]. Survival improves when diagnosis is performed at an older age, this is also described in other studies when the patient receives adjuvant treatment after surgical intervention [27-30].

## Conclusion

ATRT is a rare neoplasia that was recently described and has an aggressive behavior; however, surgical and oncological management is extremely important to extend the survival rate of the patients. Recent statistics show that this tumor has been underdiagnosed throughout the time and that evaluation of surgical material by a neuropathologist is required for its correct diagnosis.

## Conflict of interest

No conflicts of interest are reported by the authors.

## Funding

All authors have declared that no funding was received from any organization for the submitted work.

## Statements and Declarations

The authors did not receive support from any organization for the submitted work. The authors have no relevant financial or non-financial interests to disclose.

## References

- [1] Ostrom, Q. T., Chen, Y., M de Blank, P., Ondracek, A., Farah, P., Gittleman, H., Wolinsky, Y., Kruchko, C., Cohen, M. L., Brat, D. J., & Barnholtz-Sloan, J. S. (2014). The descriptive epidemiology of atypical teratoid/rhabdoid tumors in the United States, 2001-2010. *Neuro-oncology*, 16(10), 1392–1399. <https://doi.org/10.1093/neuonc/nou090>
- [2] León-Bojorge, B., Rueda-Franco, F., & Anaya-Jara, M. (2008). Central nervous system atypical teratoid rhabdoid tumor: experience at the National Institute of Pediatrics, Mexico City. *Child's nervous system: ChNS: official journal of the International Society for Pediatric Neurosurgery*, 24(3), 307–312. <https://doi.org/10.1007/s00381-007-0464-9>
- [3] Li, D., Heiferman, D. M., Syed, H. R., Santos, J. G., Bowman, R. M., DiPatri, A. J., Tomita, T., Wadhvani, N. R., & Alden, T. D. (2019). Pediatric primary spinal atypical teratoid rhabdoid tumor: a case series and review of the literature. *Journal of neurosurgery: Pediatrics*, 1–17. Advance online publication. <https://doi.org/10.3171/2019.4.PEDS19113>
- [4] Coccé, M. C., Lubieniecki, F., Kordes, U., Alderete, D., & Gallego, M. S. (2011). A complex karyotype in an atypical teratoid/rhabdoid tumor: case report and review of the literature. *Journal of neuro-oncology*, 104(1), 375–380. <https://doi.org/10.1007/s11060-010-0478-0>
- [5] Lee, J. Y., Kim, I. K., Phi, J. H., Wang, K. C., Cho, B. K., Park, S. H., Ahn, H. S., Kim, I. H., & Kim, S. K. (2012). Atypical teratoid/rhabdoid tumors: the need for more active therapeutic measures in younger patients. *Journal of neuro-oncology*, 107(2), 413–419. <https://doi.org/10.1007/s11060-011-0769-0>
- [6] Woehrer, A., Slavc, I., Waldhoer, T., Heinzl, H., Zielonke, N., Czech, T., Benesch, M., Hainfellner, J. A., Haberler, C., & Austrian Brain Tumor Registry (2010). Incidence of atypical teratoid/rhabdoid tumors in children: a population-based study by the Austrian Brain Tumor Registry, 1996-2006. *Cancer*, 116(24), 5725–5732. <https://doi.org/10.1002/cncr.25540>
- [7] Rickert, C. H., & Paulus, W. (2001). Epidemiology of central nervous system tumors in childhood and adolescence based on the new WHO classification. *Child's nervous system: ChNS: official journal of the International Society for Pediatric Neurosurgery*, 17(9), 503–511. <https://doi.org/10.1007/s003810100496>
- [8] Gendle, C., Karthigeyan, M., Salunke, P., & Gupta, K. (2020). Pineal Atypical Teratoid Rhabdoid Tumor in a 5-Month-Old Child. *Pediatric neurosurgery*, 55(6), 404–408. <https://doi.org/10.1159/000511995>
- [9] Blakeley, J. O., & Grossman, S. A. (2006). Management of pineal region tumors. *Current treatment options in oncology*, 7(6), 505–516. <https://doi.org/10.1007/s11864-006-0025-6>
- [10] Cheng, Y. C., Lirng, J. F., Chang, F. C., Guo, W. Y., Teng, M. M., Chang, C. Y., Wong, T. T., & Ho, D. M. (2005). Neuroradiological findings in atypical teratoid/rhabdoid tumor of the central nervous system. *Acta radiologica (Stockholm, Sweden: 1987)*, 46(1), 89–96. <https://doi.org/10.1080/02841850510020987>
- [11] Warmuth-Metz, M., Bison, B., Dannemann-Stern, E., Kortmann, R., Rutkowski, S., & Pietsch, T. (2008). CT and MR imaging in atypical teratoid/rhabdoid tumors of the central nervous system. *Neuroradiology*, 50(5), 447–452. <https://doi.org/10.1007/s00234-008-0369-7>
- [12] Miller, S., Ward, J. H., Rogers, H. A., Lowe, J., & Grundy, R. G. (2013). Loss of INI1 protein expression defines a subgroup of aggressive central nervous system primitive neuroectodermal tumors. *Brain pathology (Zurich, Switzerland)*, 23(1), 19–27. <https://doi.org/10.1111/j.1750-3639.2012.00610.x>
- [13] Meyers, S. P., Khademan, Z. P., Biegel, J. A., Chuang, S. H., Korones, D. N., & Zimmerman, R. A. (2006). Primary intracranial atypical teratoid/rhabdoid tumors of infancy and childhood: MRI features and patient outcomes. *AJNR. American journal of neuroradiology*, 27(5), 962–971.
- [14] Hilden, J. M., Meerbaum, S., Burger, P., Finlay, J., Janss, A., Scheithauer, B. W., Walter, A. W., Rorke, L. B., & Biegel, J. A. (2004). Central nervous system atypical teratoid/rhabdoid tumor: results of therapy in children enrolled in a registry. *Journal of clinical oncology: official journal of the American Society of Clinical Oncology*, 22(14), 2877–2884. <https://doi.org/10.1200/JCO.2004.07.073>
- [15] Marques, T. C., Costa, R. S., de Souza, S. R., & Corrêa, D. G. (2022). Atypical teratoid/rhabdoid tumour in the pineal and suprasellar regions: report of 2 cases and review of the literature. *Child's nervous system: ChNS: official journal of the International Society for Pediatric Neurosurgery*, 38(8), 1429–1432. <https://doi.org/10.1007/s00381-022-05586-5>
- [16] Torchia, J., Picard, D., Lafay-Cousin, L., Hawkins, C. E., Kim, S. K., Letourneau, L., Ra, Y. S., Ho, K. C., Chan, T. S., Sin-Chan, P., Dunham, C. P., Yip, S., Ng, H. K., Lu, J. Q., Albrecht, S., Pimentel, J., Chan, J. A., Somers, G. R., Zielenska, M., Faria, C. C., ... Huang, A. (2015). Molecular subgroups of atypical teratoid rhabdoid tumours in children: an integrated genomic and clinicopathological analysis. *The Lancet. Oncology*, 16(5), 569–582. [https://doi.org/10.1016/S1470-2045\(15\)70114-2](https://doi.org/10.1016/S1470-2045(15)70114-2)
- [17] Tan, X., Xiao, M., Jiang, W., Yue, C., Qu, L., & Zhao, G. (2021). Paediatric atypical teratoid/rhabdoid tumour of the pineal region mimicking a meningioma: a case report and literature review. *British journal of neurosurgery*, 1–4. Advance online publication. <https://doi.org/10.1080/02688697.2021.1895971>
- [18] Fontana, E. J., Garvin, J., Feldstein, N., & Anderson, R. C. (2011). Pediatric considerations for pineal tumor management. *Neurosurgery clinics of North America*, 22(3), 395–ix. <https://doi.org/10.1016/j.nec.2011.05.003>
- [19] Nemes, K., Johann, P. D., Steinbügl, M., Gruhle, M., Bens, S., Kachanov, D., Teleshova, M., Hauser, P., Simon, T., Tippelt, S., Eberl, W., Chada, M., Lopez, V. S., Grigull, L., Hernáiz-Driever, P., Eyrich, M., Pears, J., Milde, T., Reinhard, H., Leipold, A., ... Frühwald, M. C. (2022). Infants and Newborns with Atypical Teratoid Rhabdoid Tumors (ATRT) and Extracranial Malignant Rhabdoid Tumors (eMRT) in the EU-RHAB Registry: A Unique and Challenging Population. *Cancers*, 14(9), 2185. <https://doi.org/10.3390/cancers14092185>
- [20] Frühwald, M. C., Hasselblatt, M., Nemes, K., Bens, S., Steinbügl, M., Johann, P. D., Kerl, K., Hauser, P., Quiroga,

- E., Solano-Paez, P., Biassoni, V., Gil-da-Costa, M. J., Perek-Polnik, M., van de Wetering, M., Sumerauer, D., Pears, J., Stabell, N., Holm, S., Hengartner, H., Gerber, N. U., ... Graf, N. (2020). Age and DNA methylation subgroup as potential independent risk factors for treatment stratification in children with atypical teratoid/rhabdoid tumors. *Neuro-oncology*, 22(7), 1006-1017. <https://doi.org/10.1093/neuonc/noz244>
- [21] Ostrom, Q. T., Gittleman, H., Farah, P., Ondracek, A., Chen, Y., Wolinsky, Y., Stroup, N. E., Kruchko, C., & Barnholtz-Sloan, J. S. (2013). CBTRUS statistical report: Primary brain and central nervous system tumors diagnosed in the United States in 2006-2010. *Neuro-oncology*, 15 Suppl 2(Suppl 2), ii1-ii56. <https://doi.org/10.1093/neuonc/not15>
- [22] Doi, M., Koike, J., Yoshida, Y., Nakamura, H., Chosokabe, M., Naruki, S., Tajima, S., Endo, A., Matsumori, T., & Tanaka, Y. (2021). A case of an atypical teratoid/rhabdoid tumor with distinctive histology in the pineal region in an adult patient. *Pathology international*, 71(11), 777-782. <https://doi.org/10.1111/pin.13159>
- [23] Biggs, P. J., Garen, P. D., Powers, J. M., & Garvin, A. J. (1987). Malignant rhabdoid tumor of the central nervous system. *Human pathology*, 18(4), 332-337. [https://doi.org/10.1016/s0046-8177\(87\)80161-2](https://doi.org/10.1016/s0046-8177(87)80161-2)
- [24] Shaaban, A., Al Hajali, A., Elaiwy, O., El Sotouhy, A., Al-Bozom, I., & Ayyad, A. (2021). Purely Suprasellar (Hypothalamic) Atypical Teratoid Rhabdoid Tumor Presenting with Diabetes Insipidus and Panhypopituitarism in an Adult Male: A Case Report and Review of Literature. *Asian journal of neurosurgery*, 16(4), 846-849. [https://doi.org/10.4103/ajns.AJNS\\_328\\_20](https://doi.org/10.4103/ajns.AJNS_328_20)
- [25] Johann, P. D., Erkek, S., Zapatka, M., Kerl, K., Buchhalter, I., Hovestadt, V., Jones, D. T. W., Sturm, D., Hermann, C., Segura Wang, M., Korshunov, A., Rhyzova, M., Gröbner, S., Brabetz, S., Chavez, L., Bens, S., Gröschel, S., Kratochwil, F., Wittmann, A., Sieber, L., ... Kool, M. (2016). Atypical Teratoid/Rhabdoid Tumors Are Comprised of Three Epigenetic Subgroups with Distinct Enhancer Landscapes. *Cancer cell*, 29(3), 379-393. <https://doi.org/10.1016/j.ccell.2016.02.001>
- [26] Ogiwara H. (2022). Second-look surgery for pineal region tumors. *Child's nervous system: ChNS: official journal of the International Society for Pediatric Neurosurgery*, 10.1007/s00381-022-05676-4. Advance online publication. <https://doi.org/10.1007/s00381-022-05676-4>
- [27] Chi, S. N., Zimmerman, M. A., Yao, X., Cohen, K. J., Burger, P., Biegel, J. A., Rorke-Adams, L. B., Fisher, M. J., Janss, A., Mazewski, C., Goldman, S., Manley, P. E., Bowers, D. C., Bendel, A., Rubin, J., Turner, C. D., Marcus, K. J., Goumnerova, L., Ullrich, N. J., & Kieran, M. W. (2009). Intensive multimodality treatment for children with newly diagnosed CNS atypical teratoid rhabdoid tumor. *Journal of clinical oncology: official journal of the American Society of Clinical Oncology*, 27(3), 385-389. <https://doi.org/10.1200/JCO.2008.18.7724>
- [28] Tekautz, T. M., Fuller, C. E., Blaney, S., Fouladi, M., Broniscer, A., Merchant, T. E., Krasin, M., Dalton, J., Hale, G., Kun, L. E., Wallace, D., Gilbertson, R. J., & Gajjar, A. (2005). Atypical teratoid/rhabdoid tumors (ATRT): improved survival in children 3 years of age and older with radiation therapy and high-dose alkylator-based chemotherapy. *Journal of clinical oncology: official journal of the American Society of Clinical Oncology*, 23(7), 1491-1499. <https://doi.org/10.1200/JCO.2005.05.187>
- [29] Pai Panandiker, A. S., Merchant, T. E., Beltran, C., Wu, S., Sharma, S., Boop, F. A., Jenkins, J. J., Helton, K. J., Wright, K. D., Broniscer, A., Kun, L. E., & Gajjar, A. (2012). Sequencing of local therapy affects the pattern of treatment failure and survival in children with atypical teratoid rhabdoid tumors of the central nervous system. *International journal of radiation oncology, biology, physics*, 82(5), 1756-1763. <https://doi.org/10.1016/j.ijrobp.2011.02.059>
- [30] Chen, Y. W., Wong, T. T., Ho, D. M., Huang, P. I., Chang, K. P., Shiau, C. Y., & Yen, S. H. (2006). Impact of radiotherapy for pediatric CNS atypical teratoid/rhabdoid tumor (single institute experience). *International journal of radiation oncology, biology, physics*, 64(4), 1038-1043. <https://doi.org/10.1016/j.ijrobp.2005.10.001>



**Open Access** This article is licensed under a Creative Commons Attribution 4.0 International License, which permits use, sharing, adaptation, distribution and reproduction in any medium or format, as long as you give appropriate credit to the original author(s) and the source, provide a link to the Creative Commons license, and indicate if changes were made. The images or other third-party material in this article are included in the article's Creative Commons license, unless indicated otherwise in a credit line to the material. If material is not included in the article's Creative Commons license and your intended use is not permitted by statutory regulation or exceeds the permitted use, you will need to obtain permission directly from the copyright holder. To view a copy of this license, visit <https://creativecommons.org/licenses/by/4.0/>.

© The Author(s) 2023