



Case Report and Literature Review: Unusual Presentation of Genitourinary & Gastrointestinal Metastases from Invasive Lobular Carcinoma of the Breast

Khadija Al-Musalhi¹, Badryia Al-Qassabi², Radiya Al-Ajmi³, Suad Al-Aghbari¹

¹Department of surgery, Sultan Qaboos university hospital, Muscat, Sultanate of Oman

²Department of radiology, Sultan Qaboos university hospital, Muscat, Sultanate of Oman

³Department of pathology, Sultan Qaboos university hospital, Muscat, Sultanate of Oman

Corresponding author is Khadija Al-Musalhi; khadija.m19@resident.omsb.org

Received 01 June 2020;

Accepted 28 June 2020;

Published 04 July 2020

Abstract

Unlike invasive ductal carcinoma, lobular carcinoma exhibits a distinct metastatic pattern. It is likely to spread to gynecological organs, peritoneum, retroperitoneum, brain and gastrointestinal tract in comparison to ductal carcinoma, which spreads to liver, lung, and brain tissues. The diagnosis becomes more unlikely on the rare occasion when it represents the first manifestation of breast cancer. It is important to differentiate the metastasis from primary carcinoma of genital or GI tract as the management substantially differs. In this report; we present a 47 years-old female patient who presented with gynecological organs & gastrointestinal tract involvement as initial presentation and literature review done for these unusual sites of metastasis.

Keywords: *Invasive Lobular, Unusual Metastasis, Rectum, Cervix*

Introduction

Invasive lobular carcinoma (ILC) is the second most common type of invasive carcinoma of the breast after invasive ductal carcinoma (IDC). Although ILC accounts for 5% to 15% of newly diagnosed breast cancers, its incidence is increasing while invasive ductal carcinoma has not changed in the last two decades^[1]. Sixty percent of patients with invasive lobular carcinoma will already have metastatic disease at time of diagnosis while 30-80% of patients will develop metastatic disease following surgery and/or systemic therapy or radiotherapy^[2]. The pattern of metastatic spread differs significantly between ILC and ductal carcinoma where lobular carcinoma tends to exhibit unusual sites of metastasis. It is likely to spread to gynecological organs, peritoneum, retroperitoneum, brain and gastrointestinal tract (GI) in comparison to ductal carcinoma, which spreads to the liver, lung, and brain tissues^[1].

We present a case report of a 47-year-old woman who was referred to our breast surgical clinic with a concurrent cervical, endometrium and rectal cancer that on further evaluation was diagnosed as metastatic invasive lobular carcinoma of the breast.

Case report

A 47-year-old pre-menopausal Omani female un-known to have any medial problem presented to the department of gynecology with abnormal uterine bleeding of two months duration. She was asymptomatic for anemia and she didn't receive any blood transfusion.

On physical examination, she was found to be pale but her vital signs were normal. Pelvic examination revealed hard hypertrophied cervix which was flushed into the vagina. In addition there was a vulvar mass. There was no history of rectal bleeding or gastrointestinal symptoms. Laboratory values revealed low hemoglobin of 8.5 g/dL, with normal platelet and white blood cell counts. Chemistry panel was normal. Pelvic ultrasound revealed a 30 mm dilated endometrial cavity by blood clots. Pap smear was done and it showed poor cellularity. She had an endometrial biopsy that revealed scanty atypical cells suggestive of neoplastic epithelial lesion.

Subsequently Magnetic resonance imaging (MRI) of pelvis was performed. It showed focal eccentric nodular wall thickening involving the rectum close to the rectosigmoid junction with stranding in mesorectum and post contrast enhancement, suggestive of neoplastic rectal mass. Diffuse heterogeneous bone marrow signals with multiple small T2W hypointense lesions

highly suspicious for metastases. No endometrial cervical mass however there is loss of zonal anatomy of the cervix with diffuse T2 hypointensity that is continuous with the uterine junctional zone. Minimal free fluid in the Pouch of Douglas along with

multifocal T2 hypointense and enhancing nodular thickening along the surface of left ovary, peritoneal reflections and on the dome of the urinary bladder with a differential diagnosis of either endometriosis or peritoneal carcinomatosis (Figure 1).

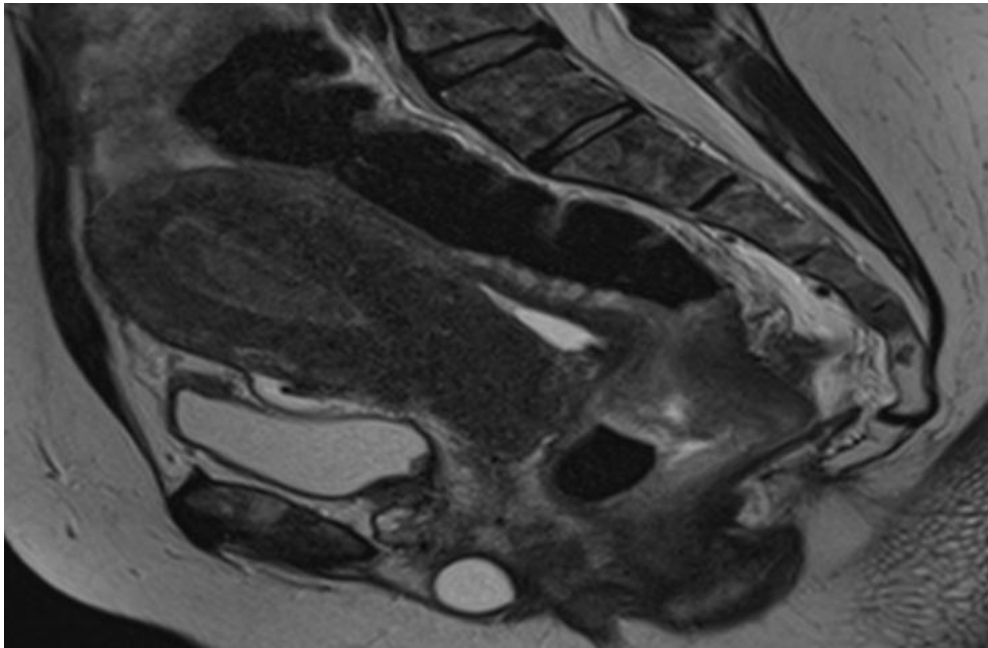


Figure 1: MRI pelvis T2 sagittal view showing diffuse T2 hypo intensity of the cervical stroma with loss of zonal anatomy (thick arrow). Diffuse thickening of the junctional zone. There is a circumferential mass seen in the rectum (arrow). Mild ascites with T2 hypo intense nodular thickening of the peritoneal reflection, dome of the urinary bladder (star). Heterogeneous signal of the bone marrow. Gartner duct cyst is seen *

On subsequent per rectal examination, the rectal mass was felt. Then she underwent repeated hysteroscopy with endometrial sampling and cervical punch biopsy. She had diagnostic colonoscopy done by gastroenterologist demonstrating fungating, friable, circumferential, non-negotiable mass started distally at 4

cm from the anal verge. Multiple biopsies were taken and the pathology report from all biopsy site including rectum, endometrium, vulva and cervix revealed poorly differentiated neoplasm consistent with metastatic breast lobular carcinoma, ER: positive, PR: positive. (Figure 2, 3)

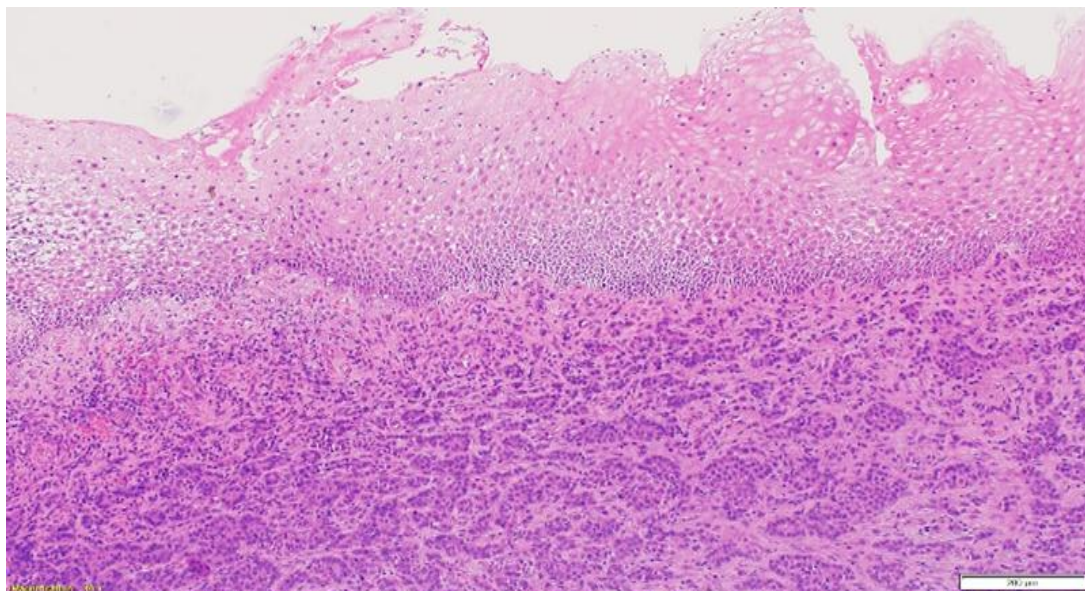


Figure 2: Hematoxylin and eosin (H&E) stain at x100 magnification showing cervix involvement by metastatic lobular carcinoma. The subepithelial stroma is densely infiltrated by malignant cells.

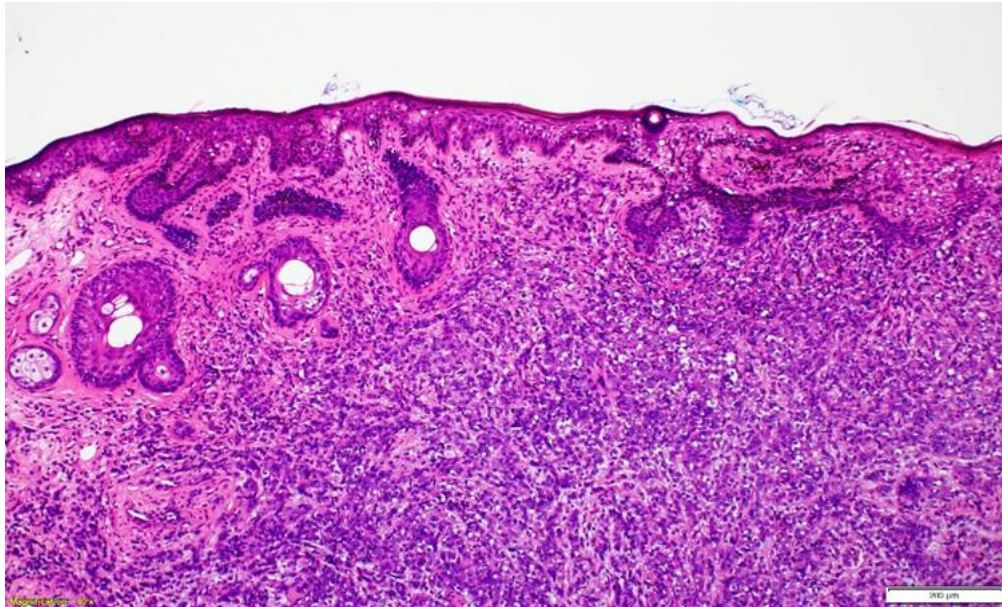


Figure 3: Hematoxylin and eosin (H&E) stain at x100 magnification showing labia involvement by metastatic lobular carcinoma. The dermis is densely infiltrated by malignant cells.

Following this, she was evaluated by breast surgeon and upon further questioning; she reported to have one-year history of bilateral breast hardness with changing in shape and size. She had never brought it to anyone's attention. Reproductive history consisted of menarche at age of 13 years.

She had two children with first live birth at age of 34 years. No history of taken combined oral contraceptive pills & no family history of breast or ovarian cancer. She has never had screening

mammogram. Breast examination was performed and revealed (Figure 4, 5) asymmetrical breast with left side smaller in size and distorted compared to right breast. The left breast was occupied by totally by big hard fixed immobile mass with skin nodules. The right breast also was occupied by big hard fixed mass but it was mobile and associated with skin thickening but no skin nodules. She had bilateral fixed axillary lymph nodes and left supraclavicular lymph node.

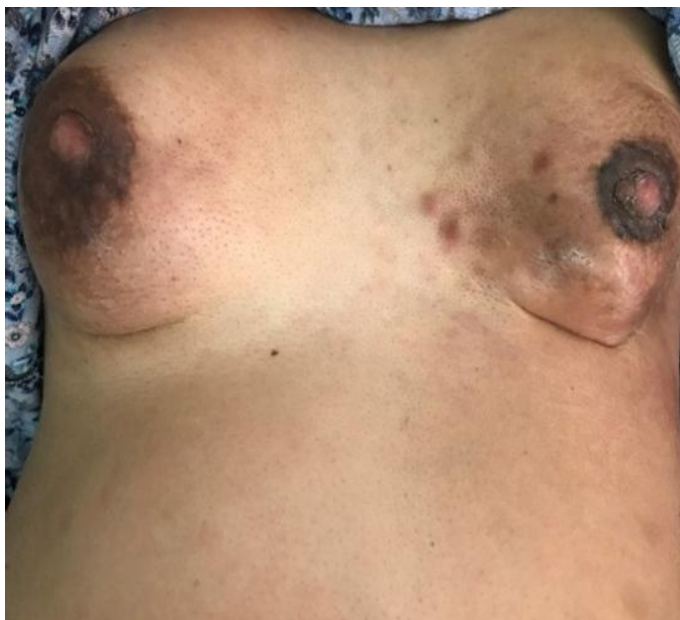

Figure 4: asymmetrical breasts with skin changes.

Mammogram and breast ultrasound were performed and revealed bilateral huge irregular masses with indistinct borders occupying central breasts with angular outline. The nipple and skin were

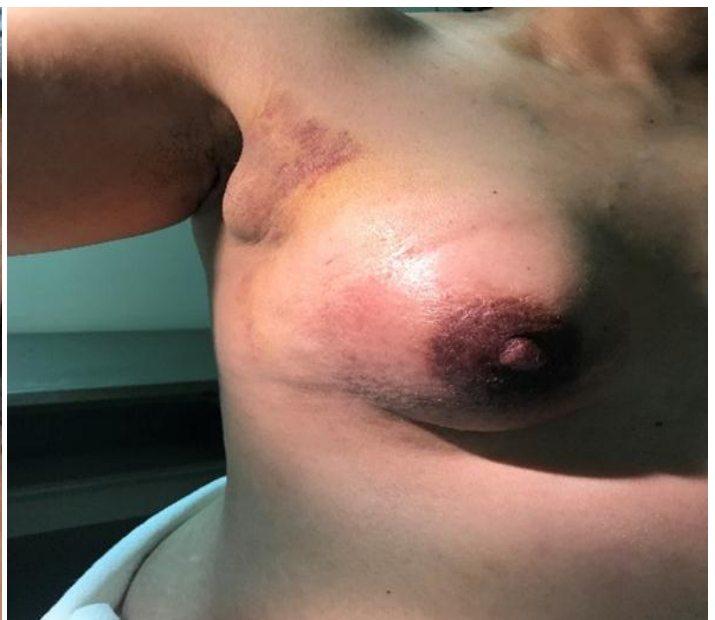

Figure 5: The right breast occupied by big mass, skin changes and fixed axillary lymph nodes

involved on both sides. There are microcalcifications seen in the left breast mass. There are bilateral axillary adenopathy involving levels 1 through 3 (Figure 6).

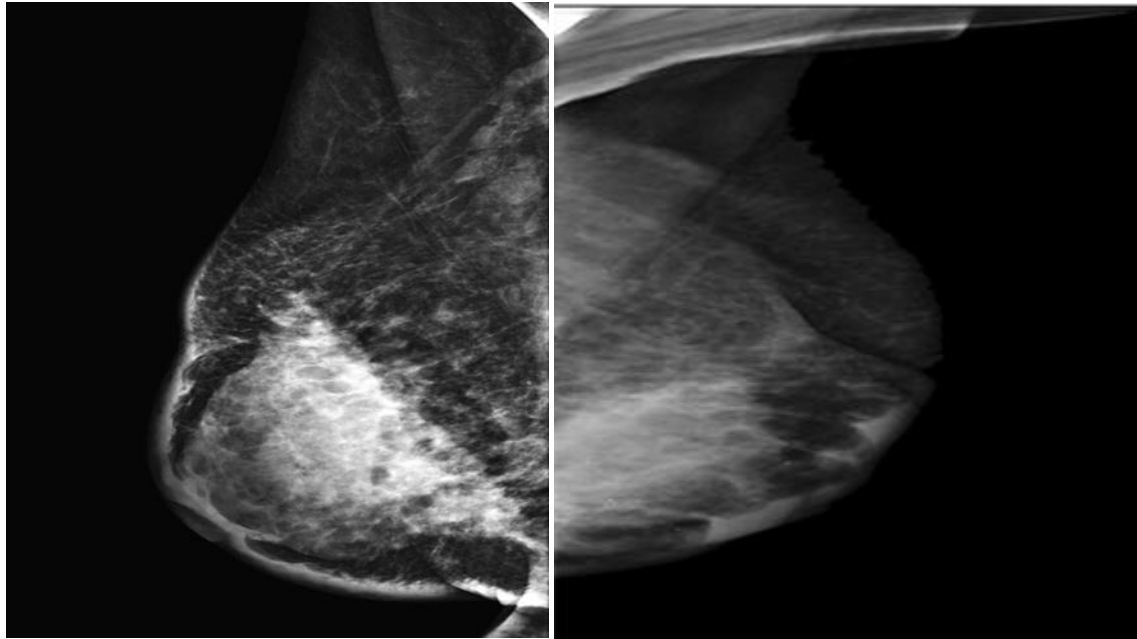


Figure 6: Bilateral mammogram MLO views: There are bilateral dense irregular masses with indistinct borders associated with diffuse skin thickening with tethering in some areas. The nipples are flat. Pleomorphic calcifications are seen in the left breast mass.

Following this, true cut biopsies from both breasts were performed and showed Invasive lobular carcinoma (ILC), grade II, and no in situ carcinoma. Estrogen receptor (ER) and progesterone receptor (PR) immunohistochemistry were positive, HER-2

immunohistochemistry was negative and the proliferation index Ki67 was 40 %. Fine needle aspiration (FNA) from both axillary lymph nodes revealed a typical cell suspicious for malignancy (figure 7, 8).

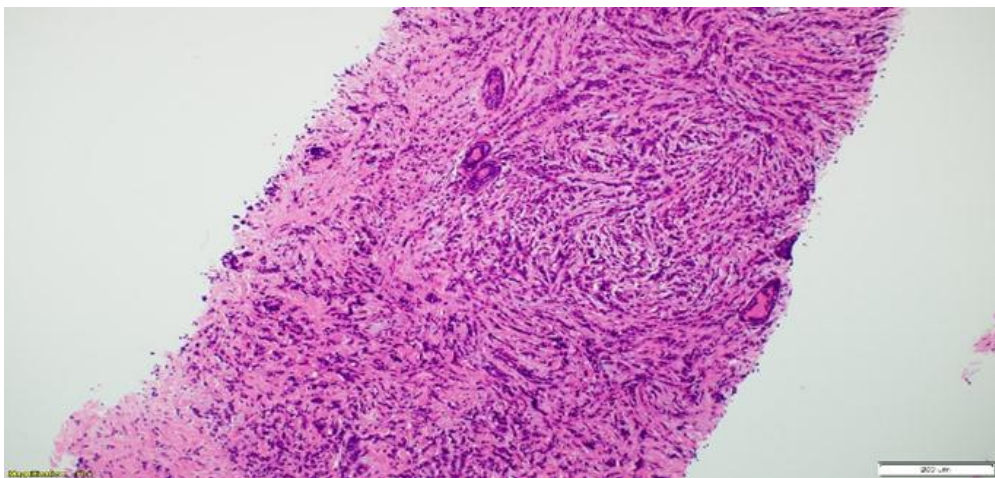


Figure 7: Hematoxylin and eosin (H&E) stain at x100 magnification showing breast core with invasive lobular carcinoma.

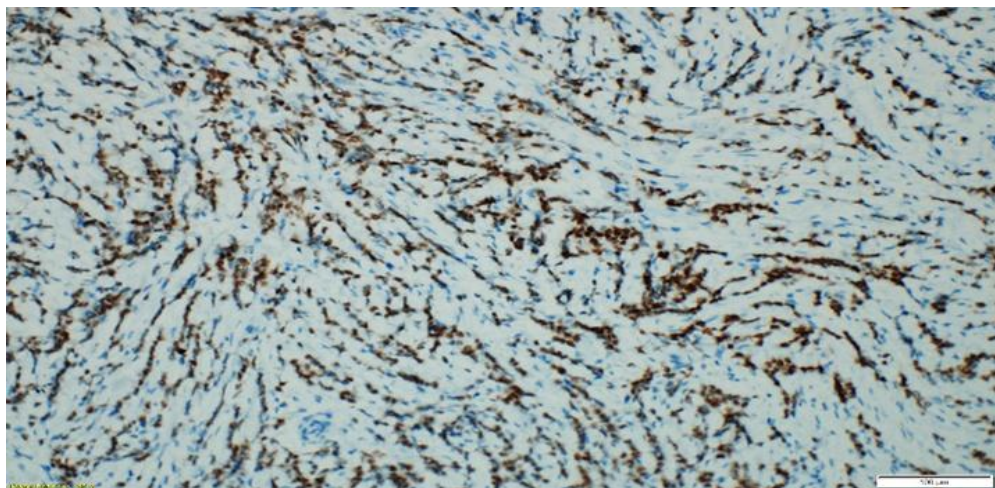
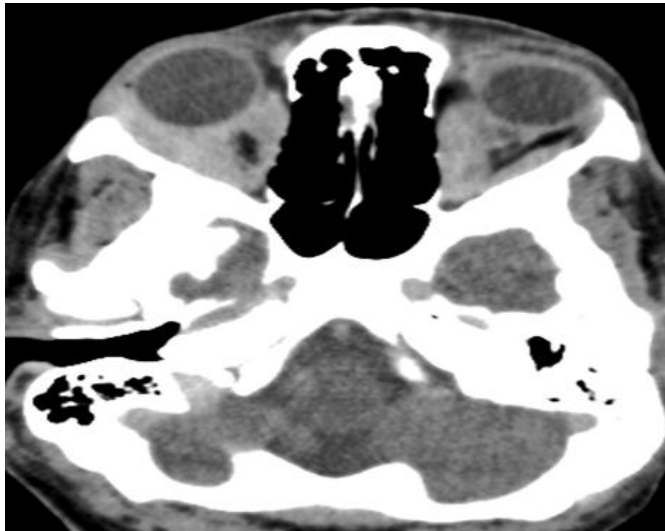

Figure 8: ER immunohistochemical positive stain at x200 magnification highlighting the malignant cells.

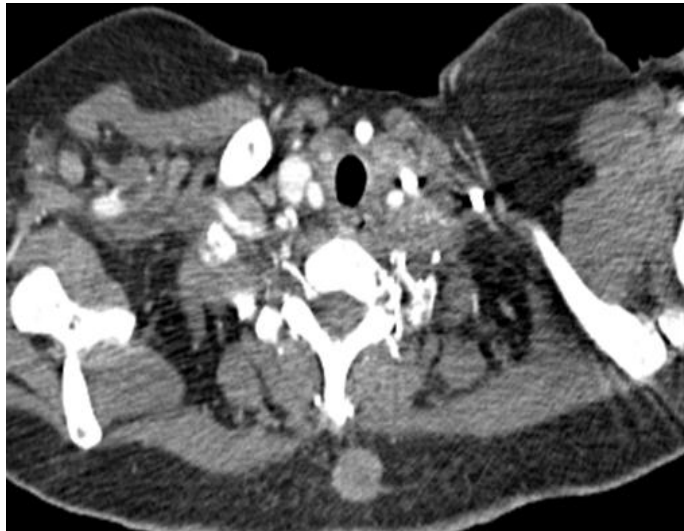
Further investigations with staging CT chest, abdomen and pelvis showed in addition to the known rectal and uterine cervical mass, subcutaneous soft tissue deposit, right and possibly left orbital metastatic involvement. Multiple bilateral cervical lymph nodes. Moderate bilateral pleural effusions. Mass lesion is seen infiltrating the left kidney and the tail of pancreas. Nodular appearance of adrenal glands. Mild to moderate bilateral hydronephrosis. There are extensive patchy mixed lytic and sclerotic bone lesions. Bone scan showed widespread, diffuse and extensive metastatic deposits

involving almost the entire axial skeleton including the proximal upper and lower limbs sparing the skull. (Figure 9, 10, 11).

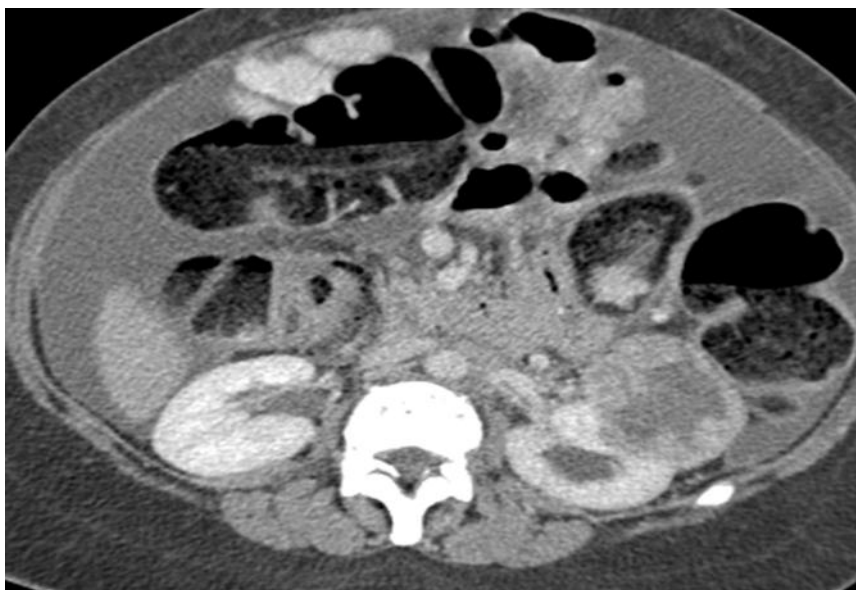MRI brain performed showed significant infiltration of the bilateral orbital muscles noted along with suggestion of heterogenous lesion noted along right lateral globe along with compression of the intracranial part of bilateral optic nerves. Bony infiltration of the bones of vault of skull and skull base. No definite brain metastasis.



(Figure 9)



(Figure 10)



(Figure 11)

CT Head (figure 9): Diffuse enlargement of the extra ocular muscles associated with exophthalmos.
CT chest (figure 10): Ring enhancing subcutaneous mass in the back of upper chest.
CT abdomen (figure 11): There is moderate ascites with a rim enhancing mass in the left kidney.

The final diagnosis was de novo metastatic lobular carcinoma of bilateral breast with extensive metastases to orbits, subcutaneous tissue, bone, kidney, pancreas, adrenals, rectum, peritoneum, cervix, uterus and ovaries. She was staged clinically for the breast cancer as left breast T4cN3M1 and right breast T4bN3M1. Cystoscopy and Bilateral JJ Ureteric Stenting was performed by urologist. She was treated with palliative chemotherapy using Palbociclib, Denosumab & Letrozole. She is still alive at the age of 49 years.

Discussion

Invasive lobular carcinoma accounts for 5% to 15% of newly diagnosed breast cancers. Unlike IDC, ILC exhibits a distinct metastatic pattern. It preferentially occurs in the bones, gynecological organs, peritoneum, retroperitoneum, and GI tract in comparison to ductal carcinoma, which spreads to liver, lung, and brain tissues [1]. Our patient presented with metastasis to bones, genitourinary system and GI system. This pattern of metastasis is supported by the prospective study, which compared the pattern of

metastasis between ILC vs. IDC. ILC had more frequent metastases to the bone (56.8 vs. 37.7%, $p=0.001$), ovarian (5.7 vs. 2.1%, $p=0.042$), and gastrointestinal (GI) tract (5.7 vs. 0.3%, $p<0.001$) and less to organs such as lung (5.7 vs. 24.2%, $p<0.001$) and liver (4.6 vs. 11.4%, $p=0.049$) [3]. In another study which followed the patient diagnosed with breast cancer for 24 years, it was found that ILC was associated with an increased incidence of bone events but a decrease in regional and lung events ($P < .01$). Same study showed that patients with ILC were older compared to IDC, more frequently with ER-positive, and less vascular invasion [4]. Compared to our case, the patient was young, ER positive, and had no vascular invasion. The knowledge regarding the unusual metastatic pattern of lobular carcinoma is essential to differentiate it from second primary and then plan appropriate treatment.

Metastasis in the female genital tract from an extragenital primary tumor is uncommon. Mazur et al in 1984 analyzed 325 cases of metastasis to female genital tract [5]. The majority of the extragenital primaries metastasizing to gynecological organs were adenocarcinoma from gastrointestinal tract. They originated less frequently from the breast and other organs. In literature review, lobular histotype seems to metastasize to the genital tract more frequently than ductal tumors [6]. The incidence of ILC metastasizing to the genital tract is 36%–52% in autopsy series and 2% - 5% in clinical series. Kumar et al published a review in 1988 with 63 cases of metastatic cancers to uterine corpus from extragenital neoplasms [7]. The most common primary metastasizing to uterus in this series was breast cancer (47.3%). Interestingly, the myometrium was found to be more involved than the endometrium although most of the endometrial curettage showed metastatic tumor cells. Le Bouedec et al in 1993 described 12 patients with metastatic breast cancer to the uterus out of which ten had ILC [8]. Abnormal vaginal bleeding may be a sign of neoplastic uterine involvement although this is also infrequent [9]. This may include abnormal duration of periods, bleeding between periods, and postmenopausal bleeding [10].

Breast cancer metastasizing to cervix is very rare. Of 325 metastatic female genital neoplasms, Mazur et al found only 3.7% involved the cervix, and none of these represented primary breast carcinomas [5]. Pérez-Montiel D et al reports the most common tumor metastasizing to cervix are gastrointestinal tract and ovarian cancers [11]. Only a few cases have been reported so far. Considering the rarity the actual incidence of cervix metastasis is unknown. In the literature most of the cases of breast cancer with genital tract metastasis occurred in advanced breast cancer while on tamoxifen treatment or during follow-up. There are only a few cases where genital tract involvement as initial presentation was reported [12]. This highlights the rarity of presentation in our case. The patient underwent full investigations for vaginal bleeding and the breast cancer was diagnosed later.

The Breast cancer is the second most common cancer to metastasize to the GI tract, following malignant melanoma. Although GI metastasis from invasive breast cancer is rare (<1% in clinical practice), the incidence might be underestimated and is likely to increase [13,14]. Autopsy series report a rate of GI tract metastasis up to 15% [14]. It rarely metastasizes to the colon or rectum, more commonly metastasizing to the stomach or small bowel. GI metastasis is usually associated with extensive systemic spread [14].

In the big series presented by Borst et al. invasive lobular carcinoma was more likely to give metastases to GI tract than invasive ductal carcinoma, with the incidence of 4.5% and 0.2%, respectively [15]. Sites of metastasis can vary from the oropharynx

to the anus. Anorectal involvement is very rare [16,17]. Rectal metastasis from ILC usually occurs 5–7 years after diagnosis of the primary tumor, but there have been cases reported with synchronously rectal metastasis, as well as metastasis up to 20–30 years after diagnosis of primary ILC [18,19]. There were very few reports about coexistence of breast cancer metastases and adenocarcinoma in GI tract. In fact, only Jafferbhoy et al. described the case of synchronous GIST, colon and breast adenocarcinoma with double colonic polyp metastases [9]. It was mentioned in literature that colonic involvement in metastasis ILC can be as high as 12 % [20]. A fifteen years' study analyzed pathological diagnosis of breast cancer metastatic to the gastrointestinal tract or peritoneum has found that Infiltrating lobular carcinoma represented 34 (64%) of the 53 gastrointestinal metastases, with 45 % involving the colon and the rectum, followed by the stomach with 28% [21]. However, a larger study was conducted before of Three hundred and thirty-seven autopsies on patients who died of carcinoma of the breast published in 1968 by Asch et al. 52 cases of these 337 were GI metastasis. The distribution of these metastases was as follows: esophagus (25%), stomach (25%), small intestine (28%), colon (19%), and rectum (4%) [22]. Other literatures which have been published showed also that stomach is the most common site of gastrointestinal involvement by metastatic breast cancer, specifically lobular form, with an incidence of up to 15% on autopsy. Mostly it's hematogenous metastases [23], but involvement via peritoneal and lymphatic spread also occurs [24]. Metastasis of ILC to colon can occur even after treatment, as it was reported a case of ILC metastasized to sigmoid colon after 3 months of treatment [25].

The time interval between primary breast cancer and gastrointestinal involvement may range from synchronous presentation to as long as 30 years but reverse is also true, with the GI manifestation preceding a diagnosis of breast cancer [26–27]. Matsuda et al and Schwarz et al reported a median interval of GI metastatic progression of 6 years with a range of 0.25 to 12.5 years [12]. Also, GI metastatic disease confers poorer prognosis, possibly due to hematogenous spread with cancer seeding in other organ systems compared to usual lymphocytic spread of breast cancer. The clinical manifestations that metastatic breast cancer to the GI tract can have are variable. Symptoms may range from non-specific complaints to acute GI symptoms & may be considered treatment-related or as inflammatory GI disease. They can also mimic a primary cancer of the GI tract, which is more common than isolated GI metastasis of primary BC [18–21]. The diagnosis becomes more unlikely on the rare occasion when it represents the first manifestation of breast cancer [28]. In our case the patient was asymptomatic and rectal lesion was detected only in MRI pelvis.

The combination of its rarity, the often unusually long interval and the non-specific clinical presentation makes the diagnosis of GI metastasis from primary breast carcinoma a challenge. Endoscopy is important in making a correct diagnosis [14–17]. The metastatic lesion may simulate inflammatory bowel disease macroscopically, so taking biopsies is important. It is important to differentiate the metastasis from primary carcinoma of genital or GI tract as the management is dramatically different. The histological diagnosis of the secondary deposit is crucial for the correct diagnosis. The histological recognition of lobular carcinoma at the metastatic sites may be difficult. Nevertheless, in our case the metastatic sites maintained their characteristics to the primary. Microscopically, metastases from ILC consist of spindle-shaped cells usually that show a single-file growth pattern with no dominant mass. The lack of dysplasia or atypia of the rectal epithelium and the glands surrounding the malignant cells is often

helpful in distinguishing between a primary and a metastatic lesion, but immunohistochemistry will allow for the most accurate diagnosis. Markers that help confirm the diagnosis are gross cystic disease fluid protein-15 (GCDFP-15), estrogen (ER) and progesterone (PR) receptors. The GCDFP-15 and the ER and/or PR are positive in metastatic lesions of the breast, in contrast to most colorectal or gastric carcinomas, which are usually negative. Studies have found ILC more likely to be ER+/PR+ than ductal carcinomas. HER-2 protein overexpression or gene amplification have been reported in <1% to 6.2% of all ILC cases. Few ILC cases (1.5%) exhibit a triple negative phenotype [29]. Our patient was positive for ER and PR and negative for HER-2 protein.

In the retrospective analysis by Sanuki-Fujimoto N et al prognosis of patients with unusual metastases was similar to that of patients with metastasis only at usual sites [30]. Systemic treatment with chemotherapy, endocrine therapy or a combination of both is usually started in patients with breast cancer that metastasize to the GI tract. Surgery should be limited to cases with complications such as stenosis or obstruction, or for obtaining a diagnosis [18-21]. Remissions are observed in 32-53% of patients [18]. Survival after diagnosis of GI metastases from a breast primary is poor with few patients surviving beyond two years, although survival up to nine years has been reported [31-32]

Conclusion

This case highlights the importance of understanding that ILC has a unique pattern of metastasis compared to most other types of breast cancer. A high index of clinical suspicion should be maintained for unusual patterns of metastases. Metastatic spread should be considered in the differential diagnosis of patients with invasive lobular breast carcinoma presenting with abnormal vaginal bleeding or GI symptoms. Accurate diagnosis is essential as the treatments for primary genital tract or GI carcinoma and metastatic lobular carcinoma are different.

List of abbreviations

GI: Gastrointestinal
 ILC: Invasive lobular carcinoma
 IDC: Invasive ductal carcinoma
 MRI: Magnetic resonance imaging (MRI)
 ER: Estrogen receptor
 PR: progesterone receptor

Conflicts of Interest

The author(s) declare(s) that there is no conflict of interest regarding the publication of this paper.

References

[1] Arrangoiz R, Papavasiliou P, Dushkin H, Farma JM. Case report and literature review: metastatic lobular carcinoma of the breast an unusual presentation. *Int J Surg Case Rep.* 2011;2:301-305. doi:10.1016/j.ijscr.2011.06.010. [PMC free article] [PubMed] [CrossRef]

[2] Bamias A., Baltayiannis G., Kaminam S., Fatouros M., Lymperopoulos E., Agnanti N. Rectal metastases from lobular carcinoma of the breast: report of a case and literature review. *Ann Oncol.* 2001;12:715-718.[PubMed]

[3] Mathew A, Rajagopal P, Villgran V, Sandhu G, Jankowitz R, Jacob M et al. Distinct Pattern of Metastases in Patients with Invasive Lobular Carcinoma of the Breast. *Geburtshilfe und Frauenheilkunde.* 2017;77(06):660-666.

[4] Pestalozzi B, Zahrieh D, Mallon E, Gusterson B, Price K, Gelber R et al. Distinct Clinical and Prognostic Features of Infiltrating Lobular Carcinoma of the Breast: Combined Results of 15 International Breast Cancer Study Group Clinical Trials. *Journal of Clinical Oncology.* 2008;26(18):3006-3014

[5] Sastre-Garau X., Jouve M., Asselain B., Vincent-Salomon A., Beuzeboc P., Dorval T. Infiltrating lobular carcinoma of the breast: clinicopathological analysis of 975 cases with reference to data on conservative therapy and metastatic patterns. *Cancer.* 1996;77:113-120. [PubMed]

[6] Jemal A., Siegel R., Ward E., Hao Y., Xu J., Murray T. Cancer statistics 2008. *CA Cancer J Clin.* 2008;58:71. [PubMed]

[7] Aurello P., D'Angelo F., Cosenza G., Petrocca S., Stoppacciaro A., Ramacciato G. Gastric metastasis 14 years after mastectomy for breast lobular carcinoma: a case report and literature review. *Am J Surg.* 2006;72:456-460. [PubMed]

[8] Washington K., McDonagh D. Secondary tumours of the gastrointestinal tract: surgical pathologic findings and comparison with autopsy series. *Mod Pathol.* 1995;8(4):427-433. [PubMed]

[9] Kumar N.B., Hart W.R. Metastases to the uterine corpus from extragenital cancers: a clinicopathologic study of 63 cases. *Cancer.* 1982;50(10):2163-2169. [PubMed]

[10] Nijenhuis M.V., Rutgers E.L. Who should not undergo breast conservation? *Breast.* 2013;22(Suppl. 2):S110-S114. [PubMed]

[11] Ayantunde A.A., Agrawal A., Parsons S.L., Welch N.T. Esophagogastric cancers secondary to a breast primary tumor do not require resection. *World J Surg.* 2007;31:1597-1601. [PubMed]

[12] Schwarz R., Klimstra D., Turnbull A. Metastatic breast cancer masquerading as gastrointestinal primary. *Am J Gastroenterol.* 1998;93:111-114. [PubMed]

[13] Dawson PM, Hershman MJ, Wood CB. Metastatic carcinoma of the breast in the anal canal. *Postgrad Med J.* 1985;61(722):1081. doi: 10.1136/pgmj.61.722.1081. [PMC free article] [PubMed] [CrossRef]

[14] Haberstick R, Tuech JJ, Wilt M, Rodier JF. Anal localization as first manifestation of metastatic ductal breast carcinoma. *Tech Coloproctol.* 2005;9(3):237-238. doi: 10.1007/s10151-005-0235-0. [PubMed] [CrossRef]

[15] Pérez-Montiel D, et al. Adenocarcinoma metastatic to the uterine cervix: a case series. *J Obstet Gynaecol Res.* 2012;38(3):541-9. doi: 10.1111/j.1447-0756.2011.01747.x. [PubMed] [CrossRef]

[16] Mistrangelo M, Cassoni P, Mistrangelo M, Castellano I, Codognotto E, Sapino A, et al. Obstructive colon metastases from lobular breast cancer: report of a case and review of the literature. *Tumori.* 2011;97(6):800-804. doi: 10.1177/030089161109700619. [PubMed] [CrossRef]

[17] Ambroggi M, Stroppa EM, Mordenti P, Biasini C, Zangrandi A, Michieletti E, et al. Metastatic breast cancer to the gastrointestinal tract: report of five cases

- and review of the literature. *Int J Breast Cancer*. 2012;2012:439023. doi: 10.1155/2012/439023. [PMC free article] [PubMed] [CrossRef]
- [18] Balakrishnan B, Shaik S, Burman-Solovyeva I. an unusual clinical presentation of gastrointestinal metastasis from invasive lobular carcinoma of breast. *J Investig Med High Impact Case Rep*. 2016;4(2):2324709616639723. [PMC free article] [PubMed]
- [19] Saranovic D, Kovac JD, Knezevic S, Susnjar S, Stefanovic AD, Saranovic DS, et al. Invasive lobular breast cancer presenting an unusual metastatic pattern in the form of peritoneal and rectal metastases: a case report. *J Breast Cancer*. 2011;14(3):247–250. doi: 10.4048/jbc.2011.14.3.247. [PMC free article][PubMed] [CrossRef]
- [20] N. Cifuentes and J. W. Pickren, “Metastases from carcinoma of mammary gland: an autopsy study,” *Journal of Surgical Oncology*, vol.11, no.3, pp.193–205, 1979
- [21] McLemore E, Pockaj B, Reynolds C, Gray R, Hernandez J, Grant C et al. Breast Cancer: Presentation and Intervention in Women With Gastrointestinal Metastasis and Carcinomatosis. *Annals of Surgical Oncology*. 2005;12(11):886-894.
- [22] Asch MJ, Wiedel PD, Habif DV. Gastrointestinal metastases from carcinoma of the breast: autopsy study and 18 cases requiring.
- [23] M. Harris, A. Howell, and M. Chrissohou, “A comparison of the metastatic pattern of infiltrating lobular carcinoma and infiltrating duct carcinoma of the breast,” *British Journal of Cancer*, vol.50, no.1, pp.23–30, 1984.
- [24] Chang SF, Burrell MI, Brand MH, Garsten JJ. The protean gastrointestinal manifestations of metastatic breast carcinoma. *Radiology* 1978; 126: 611-617
- [25] Sobinsky J, Willson T, Podbielski F, Connolly M. Unusual Metastatic Patterns of Invasive Lobular Carcinoma of the Breast. *Case Reports in Oncological Medicine*. 2013;2013:1-3.
- [26] Lin KM, Ternent CA, Adams DR, Thorson AG, Blatchford GJ, Christensen MA, Watson P, Lynch HT. Colorectal cancer in hereditary breast cancer kindreds. *Dis Colon Rectum*. 1999;42:1041–5. [PubMed]
- [27] Van Loon AJ, Brug J, Goldbohm RA, van den Brandt PA, Brug J. Differences in cancer incidence and mortality among socio-economic groups. *Scand J Soc Med*. 1995;23:110–20. [PubMed]
- [28] Stoll BA. Association between breast and colorectal cancers. *Br J Surg*. 1998;85:1468–72. [PubMed]
- [29] Lamovec J., Bracko M. Metastatic pattern of infiltrating lobular carcinoma of the breast: an autopsy study. *J Surg Oncol*. 1991;48:28–33. [PubMed]
- [30] Taal B.G., den Hartog Jager F.C.A., Steinmetz R., Peterse H. The spectrum of gastrointestinal metastases of breast carcinoma. *Gastrointest Endosc*. 1992;38:136–141. [PubMed]
- [31] Longo DL. Approach to the patient with cancer. In: Kasper DL, Braunwald E, Hauser S, Dan L, Jameson JL, Fauci AS, editors. *Harrison’s Principles of Internal Medicine*. 16th Edition. New York: Mc Graw-Hill; 2004. pp. 435–41.
- [32] Pappo I, Stahl-Kent V, Sandbank J, Karni T, Wasserman I, Halevy A. Gastrointestinal carcinomas occurring in breast cancer patients. *Breast J*. 2006;12:437–41. [PubMed]